



PATIENT

Belle Meckler

SPECIES

Canine

BREED

German Shepherd

SEX

Spayed Female

AGE

9 Years

WEIGHT

62.6 lbs

INTERPRETED BY

Kathleen Sennello DVM,
MS, Diplomate ACVIM
(Small Animal Internal
Medicine)

IMAGING PERFORMED BY

Jessica Boudreaux-
Milligan, DVM

HOSPITAL NAME

Dockside Veterinary
Imaging

REFERRING VET

Kayla Brenk, DVM

INVOICE

72920

DATE

1/2/26

PRESENTING CLINICAL SIGNS

9/18/25 CBC reveals mild elevations in ALP (202 U/L; ref 5-131 U/L) and ALT (145 U/L; ref 12-118 U/L), with a mild increase in platelets. Renal parameters (BUN, creatinine) are within reference, but urinalysis demonstrates dilute urine and proteinuria, with elevated UPC (0.9). Rx: Benazepril 10mg 1.5 tablets PO BID for blood pressure, Denamarin 1 tablet PO once daily. -12/5/25 Exam for weight loss and recheck liver enzymes. ALP 225 and ALT 178. Blood pressure measurement performed on front left forelimb with size 5 cuff: - Reading 1: 151/58 (66) - Reading 2: 171/132 (151) - Reading 3: 164/99 (110) - Reading 4: 184/71 (126) Treatment Plan/Medications: - Benazepril dosage increase: from 10mg 1.5 tablets PO BID to 20mg (can give 2 tablets of 10mg PO BID until 20mg tablets obtained, then 1 tablet of 20mg PO BID) - Continue Denamarin 1 tablet PO once daily

Abnormal PE/Chem/CBC/UA Results: See hx above, records attached.

ULTRASONOGRAPHIC EXAMINATION OF THE ABDOMEN

Urinary System

The urinary bladder is moderately distended with mildly echogenic urine. The ventral bladder wall appears mildly prominent/thickened, measuring at 0.27 cm. The region of the trigone, ureteral papillae and proximal urethra appear free of any mass lesions or calculi.

The left kidney has a normal shape and size (6.92 cm). Overall echogenicity is slightly hyperechoic with mildly reduced corticomedullary distinction and a typical 1:3 cortex:medulla ratio. There is no evidence of focal perinephric inflammation or effusion. There is no evidence of pyelectasia, nephroliths, infarcts or hydronephrosis. Renal vasculature is normal.

The right kidney has a normal shape and size (7.01 cm). Overall echogenicity is slightly hyperechoic with mildly reduced corticomedullary distinction and a typical 1:3 cortex:medulla ratio. There is no evidence of focal perinephric inflammation or effusion. There is no evidence of pyelectasia, nephroliths, infarcts or hydronephrosis. Renal vasculature is normal.

Adrenal Glands

The left adrenal gland is normal in size measuring 0.75 cm at the cranial pole and 0.66 cm at the caudal pole. It is observed in its normal position cranial to the left renal artery. It is normal in appearance (uniformly hypoechoic) and shape with no evidence of a mass effect.

The right adrenal gland is normal in size measuring 0.55 cm at the cranial pole and 0.53 cm at the caudal pole. It is observed in its normal position between the cranial aspect of the right kidney and the caudal vena cava. It is normal in appearance (uniformly hypoechoic) and shape with no evidence of a mass effect.

Spleen

The spleen is subjectively normal in size and the echotexture is homogenous. It measures 1.92 cm in width at the level of the hilus. The splenic capsule is smooth with no visible irregularities. Rare discrete focal hyperechoic, perivascular parenchymal abnormalities are present. The appearance of these lesions is most consistent with benign splenic myelolipomas. The blood flow through the hilus and splenic parenchyma appears normal.



PATIENT

Belle Meckler

SPECIES

Canine

BREED

German Shepherd

SEX

Spayed Female

AGE

9 Years

WEIGHT

62.6 lbs

INTERPRETED BY

Kathleen Sennello DVM,
MS, Diplomate ACVIM
(Small Animal Internal
Medicine)

IMAGING PERFORMED BY

Jessica Boudreaux-
Milligan, DVM

HOSPITAL NAME

Dockside Veterinary
Imaging

REFERRING VET

Kayla Brenk, DVM

INVOICE

72920

DATE

1/2/26

Liver

The liver is large in size, and normal in echogenicity with smooth peripheral margins. The parenchyma is heterogenous in echotexture with subtle, indistinct focal mottling. The visible portions of the vasculature and biliary tract appear normal. No focal nodules or cystic lesions are observed.

The gall bladder lumen is significantly distended. The gallbladder wall appears thickened and irregular in some regions measuring 0.70 cm. There is a large amount of primarily non-organized echogenic debris. Some of the debris is adhered to the gallbladder wall. There is no evidence of bile duct dilation.

Gastrointestinal

The stomach contains moderate fluid/shadowing ingesta. It measures at a normal thickness of <0.7cm with some variability due to the presence of rugal folds. The distinction of the gastric wall layers is adequate and there is no impression of reduced peristaltic activity. Shadowing ingesta interferes with full evaluation of the stomach and some areas of the cranial abdomen.

The visualized areas of duodenum, jejunum and ileum have a uniform diameter with minimal fluid distension. Wall appears subjectively, mildly increased. Bowel loops follow a typical curvilinear path with distinct wall layering. Duodenum wall measures 0.54 cm. Jejunum wall measures 0.41 cm. There is mild mucosal speckling visualized associated with the duodenum. Visualized peristalsis appears appropriate. There were no focal lesions consistent with obstruction or a mass effect observed.

Sections of colon are visualized with formed fecal material and gas shadowing distally. There is no observed focal or generalized colon wall thickening or loss of layering.

Pancreas

The right limb of the pancreas is prominent and mottled compared to the surrounding isoechoic mesentery. There is no evidence of nodules or cystic lesions. There is no evidence of regional mesenteric inflammation or fluid.

Free Abdomen

Evaluation of the peritoneal cavity did not reveal any evidence of effusion, or subjective lymphadenomegaly. The Medial iliac nodes appear normal and there was no evidence of a caudal aortic thrombus at the bifurcation. The omentum is of normal uniform echogenicity.

PRIMARY FINDINGS

- Mild suspended echogenic debris in the urinary bladder and a mildly thickened urinary bladder – The bladder mucosal changes could be consistent with cystitis or artifactual due to lack of adequate luminal distension. Bladder neoplasia cannot be ruled out but is considered unlikely in this patient.
- Large, heterogeneous liver – The diffuse hepatic changes are non-specific and could be consistent with vacuolar hepatopathy, nodular hyperplasia, inflammatory/immune-mediated disease, fibrosis, extramedullary hematopoiesis, toxic hepatopathy (e.g., copper), infiltrative neoplasia (less likely) or other hepatopathy.



PATIENT

Belle Meckler

SPECIES

Canine

BREED

German Shepherd

SEX

Spayed Female

AGE

9 Years

WEIGHT

62.6 lbs

INTERPRETED BY

Kathleen Sennello DVM,
MS, Diplomate ACVIM
(Small Animal Internal
Medicine)

IMAGING PERFORMED BY

Jessica Boudreaux-
Milligan, DVM

HOSPITAL NAME

Dockside Veterinary
Imaging

REFERRING VET

Kayla Brenk, DVM

INVOICE

72920

DATE

1/2/26

- Moderate non-organized debris visualized within the gallbladder with an irregular/thickened gallbladder wall – Findings could be consistent with cholecystitis. A neoplastic process is less likely.

- Mildly thickened small intestine with mild mucosal speckling – Bright mucosal speckling has been postulated to represent dilated lacteals or focal accumulations of mucus, cellular debris, etc.. in the mucosal crypts.

SECONDARY FINDINGS

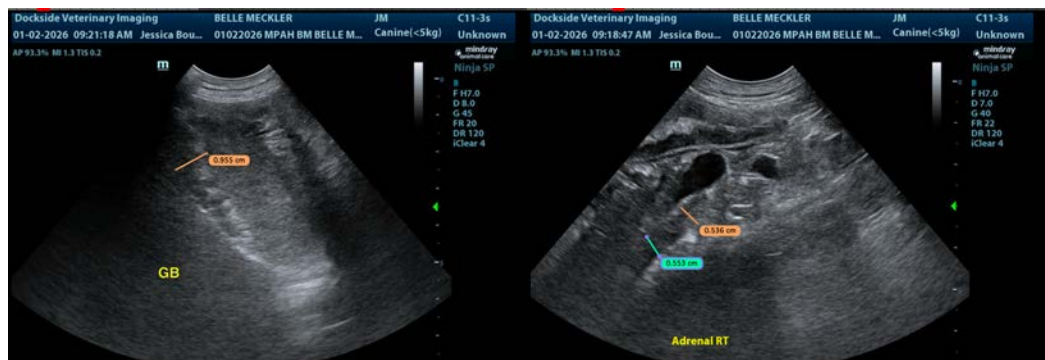- Age related changes visualized associated with both kidneys.
- Hyperechoic lesions visualized in the spleen – Findings are most consistent with benign myelolipomas. Recommend continued monitoring.
- Prominent, mottled pancreas in the right limb – Findings are most consistent with chronic pancreatic remodeling.
- Shadowing ingesta visualized within the gastric lumen – Findings are most consistent with a non-fasted patient. If the patient was adequately fasted, consider the possibility of delayed gastric emptying or partial outflow tract obstruction (none clearly visualized).

INTERPRETATION OF THE FINDINGS & FURTHER RECOMMENDATIONS

The liver changes are relatively mild and most consistent with a vacuolar hepatopathy (although other hepatopathies are possible). Additionally, the gallbladder has a moderate amount of disorganized intraluminal material and a thickened, irregular wall. Findings are concerning for possible cholecystitis. Recommend chronic Ursodiol therapy and possibly a course of antibiotics with continued monitoring of the gallbladder with ultrasound, looking for improvement with treatment or further progression.

The urinary bladder wall appears mildly thickened and there is some echogenic debris in the urinary bladder. Recommend a urinalysis and culture, looking for possible bacterial cystitis.

The small intestine appears subjectively mildly prominent/thickened, and there is mild mucosal speckling visualized associated with the duodenum. The significance of this in the absence of underlying gastrointestinal symptoms is uncertain. If an underlying enteropathy is suspected, you could consider a GI panel to Texas A&M for a qualitative PLI, TLI, cobalamin and folate. If these values are significantly abnormal, further evaluation may be warranted.





PATIENT

Belle Meckler

SPECIES

Canine

BREED

German Shepherd

SEX

Spayed Female

AGE

9 Years

WEIGHT

62.6 lbs

INTERPRETED BY

Kathleen Sennello DVM,
MS, Diplomate ACVIM
(Small Animal Internal
Medicine)

**IMAGING
PERFORMED BY**

Jessica Boudreaux-
Milligan, DVM

HOSPITAL NAME

Dockside Veterinary
Imaging

REFERRING VET

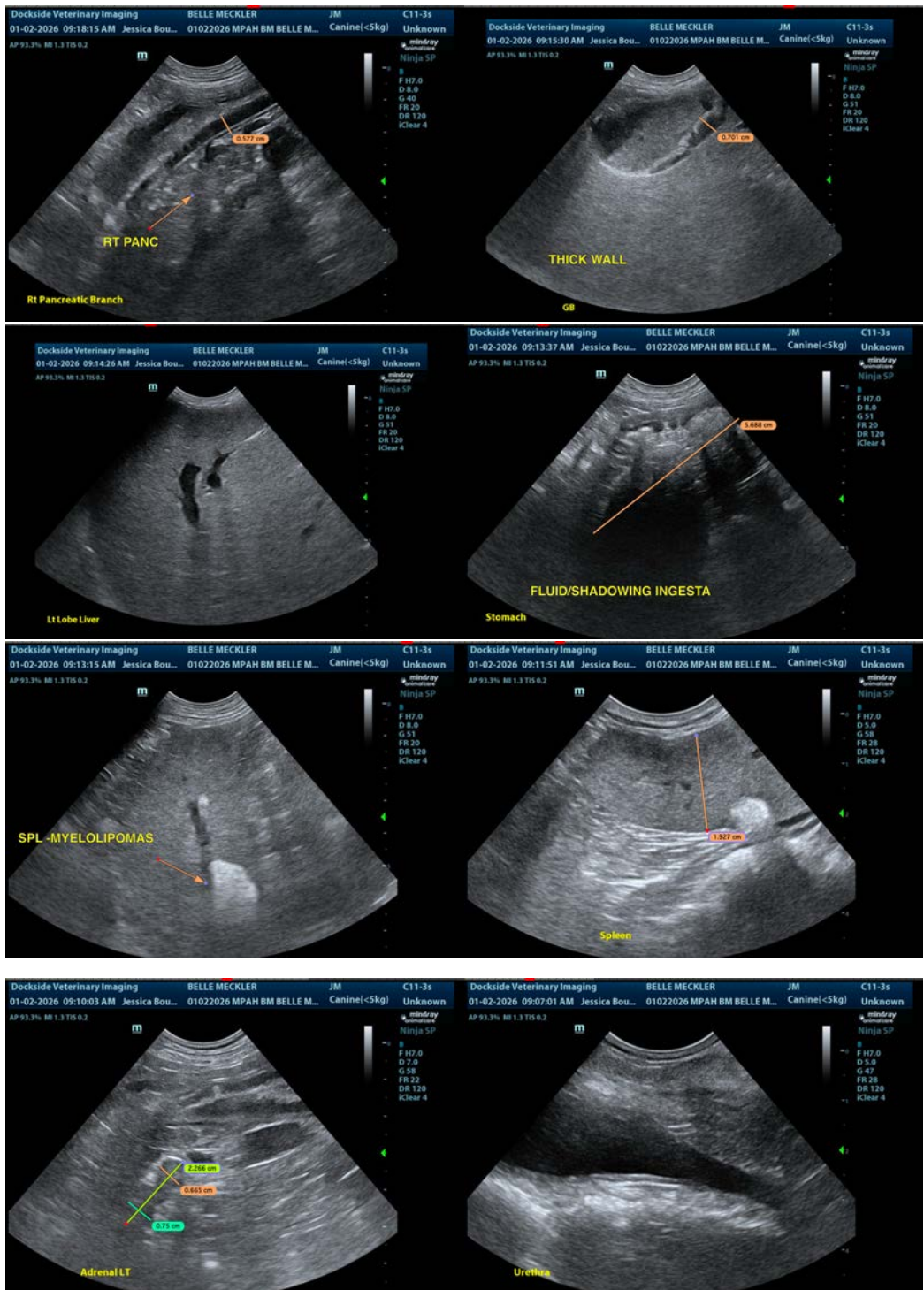
Kayla Brenk, DVM


INVOICE

72920

DATE

1/2/26





PATIENT

Belle Meckler

SPECIES

Canine

BREED

German Shepherd

SEX

Spayed Female

AGE

9 Years

WEIGHT

62.6 lbs

INTERPRETED BY

Kathleen Sennello DVM,
MS, Diplomate ACVIM
(Small Animal Internal
Medicine)

**IMAGING
PERFORMED BY**

Jessica Boudreaux-
Milligan, DVM

HOSPITAL NAME

Dockside Veterinary
Imaging

REFERRING VET

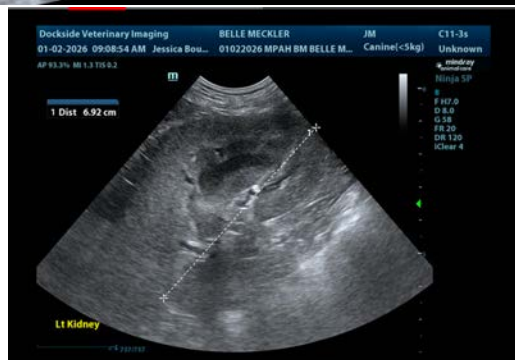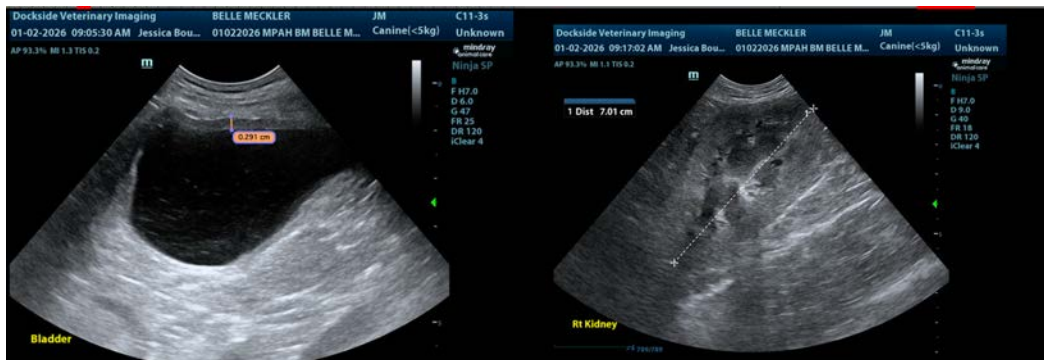
Kayla Brenk, DVM

INVOICE

72920

DATE

1/2/26



The information and recommendations provided are based on the images presented by the referring veterinarian/sonographer. No evaluation can be communicated regarding pathology that was not visible in the image/video clips provided.

Thank you for this referral. If the clinical or image interpretation does not parallel your findings or if I can be of any further assistance please contact me.

Kathleen Sennello DVM,MS, Diplomate ACVIM (Small animal Internal Medicine)

info@sonopath.com