

**DATE PRESENTING CLINICAL SIGNS**

1/19/23 Presented for diarrhea of a few days duration on 1/12. Had 1 episode of vomiting a few days prior but no further vomiting. Appetite still good but 4 lb weight loss noted. History of Glaucoma- controlled. Other than weight loss and dental disease exam unremarkable.

PATIENT

Petey Kile

SPECIES

Canine

BREED

Shih Tzu

SEX

Neutered Male

AGE

5/19/06

WEIGHT

19.1 Pounds

INTERPRETED BY

Kathleen Sennello DVM,
MS, Diplomate ACVIM
(Small Animal Internal
Medicine)

HOSPITAL NAME

Fullerton AH

REFERRING VET

Dr. Unger

INVOICE

44349

PRESENTING CLINICAL SIGNS

Presented for diarrhea of a few days duration on 1/12. Had 1 episode of vomiting a few days prior but no further vomiting. Appetite still good but 4 lb weight loss noted. History of Glaucoma- controlled. Other than weight loss and dental disease exam unremarkable.

Current Medications: Denamarin Advanced sm/med 1/2 T sid started 1/12, Metronidazole 250 mg 1/2 T BID started 1/11, Provable- 1 C sid started 1/11, Galliprant 20 mg SID- months, Dorzolamide- 1 drop OU TID. Lab Results: AST- 135 (15-66), ALT- 351 (12-118), ALP- 1138 (5-131), GGT- 149 (1-12), SDMA- 18.5 (<14), PSL- 244 (24-140), Plate- 591 (170-400).
Date of Previous IntraPet Ultrasound: No previous.
Sedation: Not required to complete full diagnostic ultrasound.
Stat Report: Not requested.
Imaging Performed By: Andi Parkinson, BS, RDMS.

ULTRASONOGRAPHIC EXAMINATION OF THE ABDOMEN**Urinary System**

The urinary bladder is moderately distended with anechoic urine. The Bladder wall, trigone, ureteral papillae and visible urethra (to a depth of 2cm) appear normal with no evidence of wall thickening, mucosal irregularities, masses or cystic calculi.

The prostate is normal in size (0.78 cm) and shape for this neutered male dog. The parenchyma is homogenous and the external margins are smooth. The prostatic urethra appears normal with no evidence of irregularity, invasion, mass effect or calculi.

The left kidney has a normal shape and size (4.03 cm). Overall echogenicity is slightly hyperechoic with poor corticomedullary distinction and a typical 1:3 cortex:medulla ratio. There is no evidence of focal perinephric inflammation or effusion. There is no evidence of pyelectasia, nephroliths, infarcts or hydroureter. Renal vasculature is normal.

The right kidney has a normal shape and size (4.21 cm). Overall echogenicity is slightly hyperechoic with poor corticomedullary distinction and a typical 1:3 cortex:medulla ratio. There is no evidence of focal perinephric inflammation or effusion. There is no evidence of pyelectasia, nephroliths, infarcts or hydroureter. Renal vasculature is normal.

Adrenal Glands

The left adrenal gland is slightly irregular in shape and plump at 0.80 cm. It is observed in its normal position cranial to the left renal artery.

The right adrenal gland is large and irregular, measuring 0.84 cm at the caudal pole. It is observed in its normal position between the cranial aspect of the right kidney and the caudal vena cava.

Spleen

The spleen is subjectively normal in size. The spleen echotexture is heterogenous and mottled, the splenic capsule is smooth with no irregularities. The blood flow through the hilus and splenic parenchyma appears normal. No focal parenchymal abnormalities are visualized.

Liver

The liver is large and irregular. The parenchyma is heterogenous in echotexture with subtle, indistinct focal mottling. The visible portions of the vasculature and biliary tract appear normal. There are two irregular lobulated, hyper- to mixed echogenic masses visualized in the liver. One of the left side measures 5.14 cm x 3.81 cm. One on the right side measures 5.75 cm in diameter.

The gall bladder lumen is moderately distended. The wall of the gall bladder is not thickened and has a smooth mucosal surface. There is a moderate amount of non-organized echogenic debris. The cystic and common bile ducts are normal/not visible.

Gastrointestinal

The stomach contains minimal luminal contents. It measures at a normal thickness of <0.7cm with some variability due to the presence of rugal folds. The distinction of the gastric wall layers is adequate and there is no impression of reduced peristaltic activity. No masses or focal lesions were observed.

The visualized areas of duodenum, jejunum and ileum have a relatively uniform diameter with minimal fluid distension. Wall thickness is normal. Bowel loops follow a curvilinear path with distinct wall layering maintaining the typical 1:3 muscularis:mucosa layer ratio. Duodenum wall measures 0.34 cm. Jejunum wall measures 0.32 cm. Visualized peristalsis appears appropriate. There were no focal lesions consistent with obstruction or a mass effect observed.

The ileocecal junction was visualized and exhibited normal intact wall layering and is subjectively of normal thickness. Sections of colon are visualized with formed fecal material and gas shadowing distally. There is no observed focal or generalized colon wall thickening or loss of layering.

Pancreas

The pancreas (particularly the right limb) is large and hypoechoic to surrounding mesentery. There is no evidence of nodules or cystic lesions. There is evidence of regional mesenteric inflammation. Consistent with moderate pancreatitis.

Free Abdomen

Evaluation of the peritoneal cavity did not reveal any evidence of effusion, or subjective lymphadenomegaly. The Medial iliac nodes appear normal and there was no evidence of a caudal aortic thrombus at the bifurcation. The omentum is of normal uniform echogenicity.

ULTRASONOGRAPHIC FINDINGS

- Borderline large irregular adrenal glands – The bilateral adrenomegaly could be consistent with bilateral hyperplasia (e.g., secondary to pituitary-dependent hyperadrenocorticism), bilateral infiltrative neoplasia, inflammatory adrenal disease, other. Correlation with clinical findings is recommended.
- Decreased corticomedullary distinction in both kidneys – The bilateral renal findings are consistent with age-related change.
- Mottled spleen – The diffuse splenic changes are non-specific and could be consistent with lymphoid hyperplasia, extramedullary hematopoiesis, infiltrative neoplasia, inflammation, other. Cytology or histopathology would be necessary to get a definitive diagnosis.
- Large, lobulated, hypoechoic pancreas surrounded by hyperechoic mesentery – The pancreatic changes are most consistent with moderate pancreatitis/pancreatic inflammation. Recommend fPLI testing and continued monitoring for improvement or possible development of a pancreatic abscess. Consider fine needle aspirate if not improving.
- Hyper- and mixed echogenicity liver masses – These lesions could be consistent with primary hepatic masses or less likely metastatic lesions. Recommend a fine needle aspirate.

- Moderate gallbladder debris – The significance of the aggregated gallbladder debris is unclear. This could represent an early mucocele, cholestasis, or may be secondary to fasting but seems unlikely to be causing a current issue. Recommend continued monitoring.

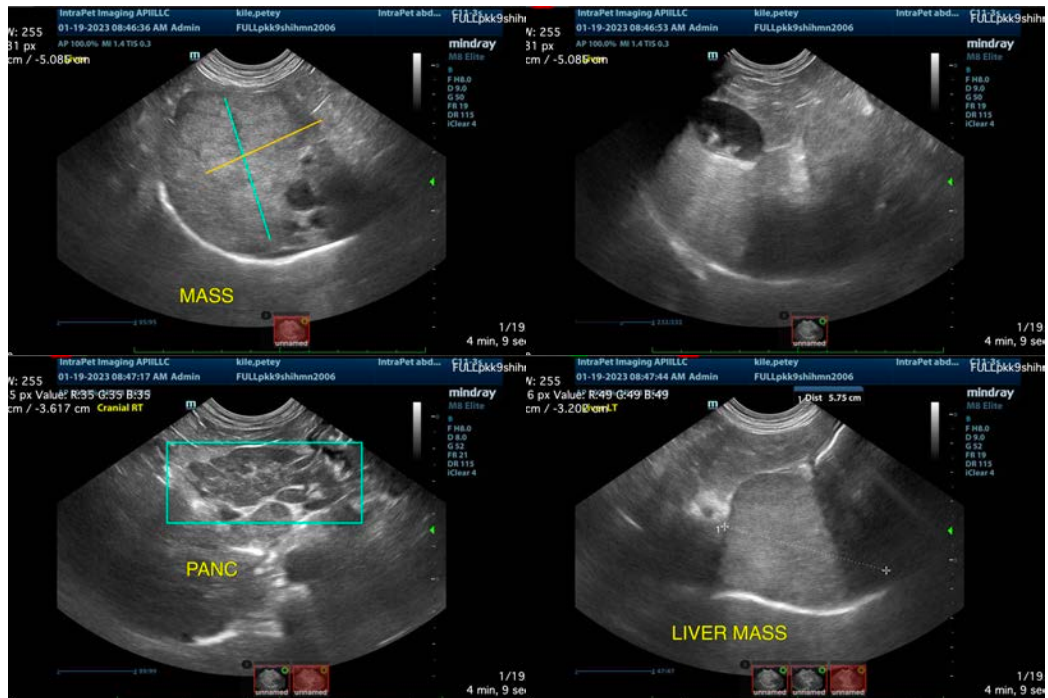
INTERPRETATION OF THE FINDINGS & FURTHER RECOMMENDATIONS

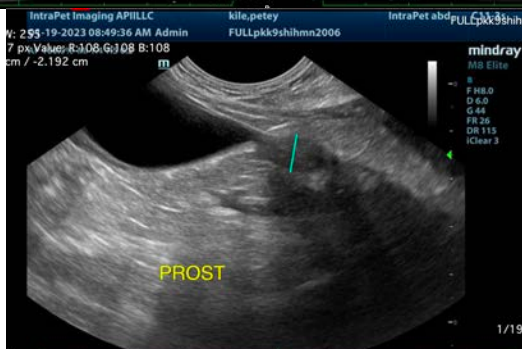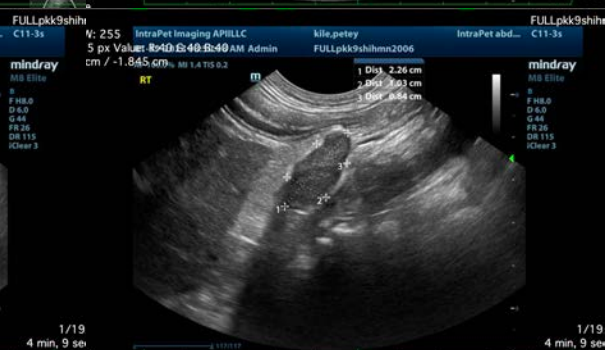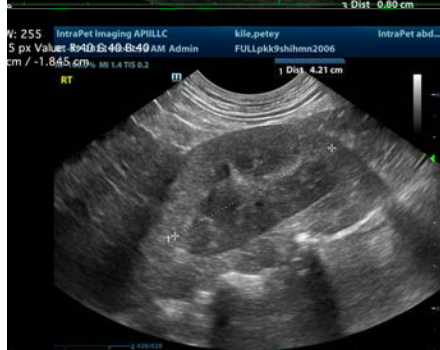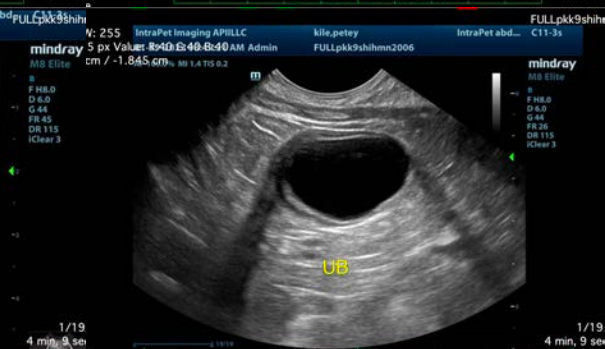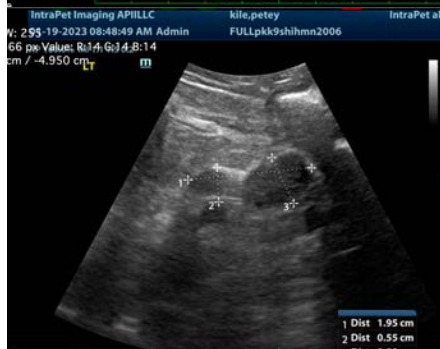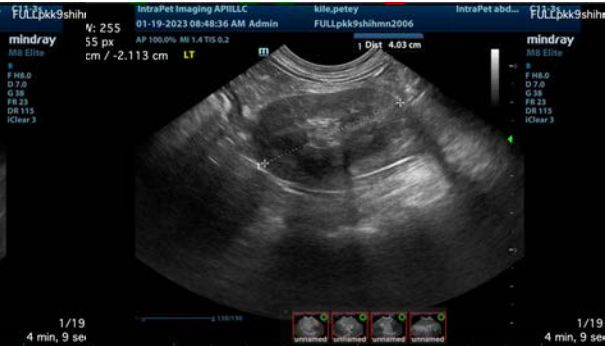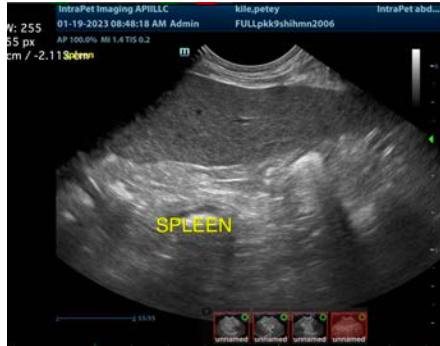There are at least two large lobulated, mixed echogenic, hyperechoic masses arising towards the caudal aspect of the liver. These could represent primary hepatic masses (Benign or neoplastic) or less likely could represent neoplastic lesions. Consider a contrast CT scan to better evaluate the relationship of these masses and their location to try and determine if surgical removal could be possible. If these are benign or slow growing hepatic carcinomas, the prognosis can be good with surgical removal.

The right limb of the pancreas appears prominent, lobulated, and hypoechoic with surrounding hyperechoic mesentery. This is most consistent with acute moderate pancreatitis and could be associated with the acute symptoms observed. Recommend treatment for pancreatitis.

The spleen appears somewhat mottled with no focal lesions. Consider a fine needle aspirate.

Recommend three view thoracic radiographs to evaluate for possible concurrent thoracic disease/involvement.





The information and recommendations provided are based on the images presented by the referring veterinarian/sonographer. No evaluation can be communicated regarding pathology that was not visible in the image/video clips provided.

Thank you for this referral. If the clinical or image interpretation does not parallel your findings or if I can be of any further assistance please contact me.

Kathleen Sennello DVM,MS, Diplomate ACVIM (Small animal Internal Medicine)
kathleen.sennello@sonopath.com