



**PATIENT**

Max Bedor

**SPECIES**

Canine

**BREED**

Mixed

**SEX**

Neutered Male

**AGE**

8 Years

**WEIGHT**

75 Pounds

**INTERPRETED BY**

Kathleen Sennello DVM,  
MS, Diplomate ACVIM  
(Small Animal Internal  
Medicine)

**IMAGING PERFORMED BY**

Dr. Arch Gordon

**HOSPITAL NAME**

Coral Ridge AH

**REFERRING VET**

Dr. Arch Gordon

**INVOICE**

44393

**DATE**

1/19/23

**PRESENTING CLINICAL SIGNS**

Lethargy and nausea - no weight loss, increased borborygmus wants to eat grass Labwork unremarkable Radiographs unremarkable Patient BAR We placed patient on Sucralfate, Reglan, pro biotics and started Royal Canin Gastro diet - will consider hypoallergenic diet based on results Submitted fecal with Antigen testing.

**ULTRASONOGRAPHIC EXAMINATION OF THE ABDOMEN**

**Urinary System**

The urinary bladder is moderately distended with anechoic urine. The Bladder wall, trigone, ureteral papillae and visible urethra (to a depth of 2cm) appear normal with no evidence of wall thickening, mucosal irregularities, masses or cystic calculi.

The visualized areas of prostate and surrounding tissue appear normal. Unfortunately, the prostate is not fully visualized likely due to its intrapelvic location. Correlate with rectal exam findings.

The left kidney has a normal shape and size (6.43 cm). Overall echogenicity is normal with adequate corticomedullary distinction and a typical 1:3 cortex:medulla ratio. There is no evidence of focal perinephric inflammation or effusion. There is no evidence of pyelectasia, nephroliths, infarcts or hydroureter. Renal vasculature is normal.

The right kidney has a normal shape and size (7.28 cm). Overall echogenicity is normal with adequate corticomedullary distinction and a typical 1:3 cortex:medulla ratio. There is no evidence of focal perinephric inflammation or effusion. There is no evidence of pyelectasia, nephroliths, infarcts or hydroureter. Renal vasculature is normal.

**Adrenal Glands**

The left adrenal gland is normal in size measuring 0.45 cm at the caudal pole. It is observed in its normal position cranial to the left renal artery. It is normal in appearance (uniformly hypoechoic) and shape with no evidence of a mass effect.

The right adrenal gland is normal in size measuring 0.53 cm at the caudal pole. It is observed in its normal position between the cranial aspect of the right kidney and the caudal vena cava. It is normal in appearance (uniformly hypoechoic) and shape with no evidence of a mass effect.

**Spleen**

The spleen is borderline large. The spleen echotexture is heterogenous and mottled, the splenic capsule is smooth with no irregularities. The blood flow through the hilus and splenic parenchyma appears normal. No focal parenchymal abnormalities are visualized.

**Liver**

The liver is normal/borderline small, with normal echogenicity and smooth peripheral margins. The parenchyma is homogenous echotexture. The visible portions of the vasculature and biliary tract appear normal. No focal nodules or cystic lesions are observed.

The gallbladder lumen is moderately distended. The wall of the gall bladder is not thickened and has a smooth mucosal surface. Luminal contents are mild and primarily anechoic. The cystic and common bile ducts are normal/not visible.



**PATIENT**

Max Bedor

**SPECIES**

Canine

**BREED**

Mixed

**SEX**

Neutered Male

**AGE**

8 Years

**WEIGHT**

75 Pounds

**INTERPRETED BY**

Kathleen Sennello DVM,  
MS, Diplomate ACVIM  
(Small Animal Internal  
Medicine)

**IMAGING PERFORMED BY**

Dr. Arch Gordon

**HOSPITAL NAME**

Coral Ridge AH

**REFERRING VET**

Dr. Arch Gordon

**INVOICE**

44393

**DATE**

1/19/23

**Gastrointestinal**

The stomach is moderately dilated with fluid and irregular shadowing material most consistent with normal ingesta and gas. It measures at a normal thickness of <0.7cm with some variability due to the presence of rugal folds. The distinction of the gastric wall layering is adequate and there is no impression of reduced peristaltic activity. No masses or focal lesions were observed.

The visualized areas of duodenum, jejunum and ileum have a relatively uniform diameter with minimal fluid distension. Wall thickness is normal. Bowel loops follow a curvilinear path with distinct wall layering maintaining the typical 1:3 muscularis:mucosa layer ratio. Jejunum wall measures 0.40 cm. Duodenum wall measures 0.43 cm. Visualized peristalsis appears appropriate. There were no focal lesions consistent with obstruction or a mass effect observed.

The ileocecal junction was visualized and exhibited normal intact wall layering and is subjectively of normal thickness. Sections of colon are visualized with formed fecal material and gas shadowing distally. There is no observed focal or generalized colon wall thickening or loss of layering.

**Pancreas**

The pancreas is normal and isoechoic to surrounding mesentery. There is no evidence of nodules or cystic lesions. There is no evidence of regional mesenteric inflammation or fluid.

**Free Abdomen**

Evaluation of the peritoneal cavity did not reveal any evidence of effusion, or subjective lymphadenomegaly. The Medial iliac nodes appear normal and there was no evidence of a caudal aortic thrombus at the bifurcation. The omentum is of normal uniform echogenicity.

**ULTRASONOGRAPHIC FINDINGS**

- Borderline large, mottled spleen – The diffuse splenic changes are non-specific and could be consistent with lymphoid hyperplasia, extramedullary hematopoiesis, infiltrative neoplasia, inflammation, other. Cytology or histopathology would be necessary to get a definitive diagnosis.
- Subjectively small liver – Correlate with liver values and a liver function test. This could be within normal limits for a deep chested dog.
- Moderate ingesta within the gastric lumen – Correlate with feeding history. If the patient was adequately fasted, then consider such differentials as delayed gastric emptying time, partial outflow tract obstruction, etc. (none observed).

**INTERPRETATION OF THE FINDINGS & FURTHER RECOMMENDATIONS**

No focal lesions are visualized on today's exam. Subjectively, the spleen appears large and somewhat mottled, but this could be normal for a large dog. Consider a fine needle aspirate of the spleen. Additionally, the liver appears subjectively small. Correlate this with bloodwork, abdominal radiographs, etc. If this is concerning, consider a liver function test (pre- and post-prandial bile acids).

Unfortunately, there can be significant gastrointestinal disease despite a normal ultrasound exam, as there are many causes for vomiting/nausea that cannot be diagnosed by ultrasound alone.

Consider such differentials as food allergy/dietary intolerance, GI parasitism, chronic pancreatitis, IBD and less likely neoplasia, etc..



**PATIENT**

Max Bedor

**SPECIES**

Canine

**BREED**

Mixed

**SEX**

Neutered Male

**AGE**

8 Years

**WEIGHT**

75 Pounds

**INTERPRETED BY**

Kathleen Sennello DVM,  
MS, Diplomate ACVIM  
(Small Animal Internal  
Medicine)

**IMAGING PERFORMED BY**

Dr. Arch Gordon

**HOSPITAL NAME**

Coral Ridge AH

**REFERRING VET**

Dr. Arch Gordon

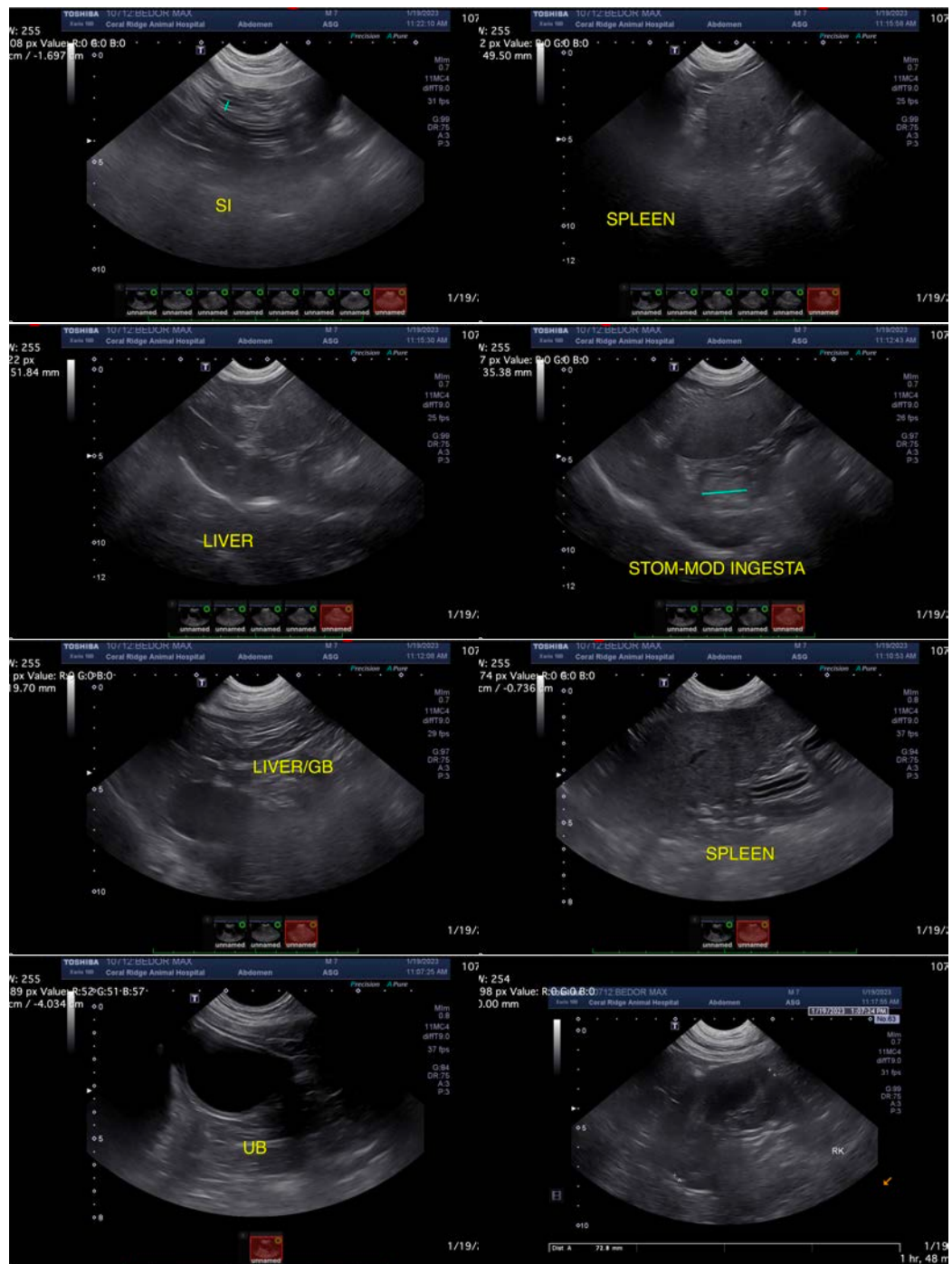
**INVOICE**

44393

**DATE**

1/19/23

- Consider a novel protein/hydrolyzed protein diet (exclusively at least 4-6 weeks)
- Consider a GI panel to Texas A&M for evaluation of B12 levels, folate, PLI/TLI etc.. to further evaluate for pancreatic/small intestinal disease.
- Recommend chronic probiotic therapy.
- If symptoms persist, consider obtaining GI biopsies.





**PATIENT**

Max Bedor

**SPECIES**

Canine

**BREED**

Mixed

**SEX**

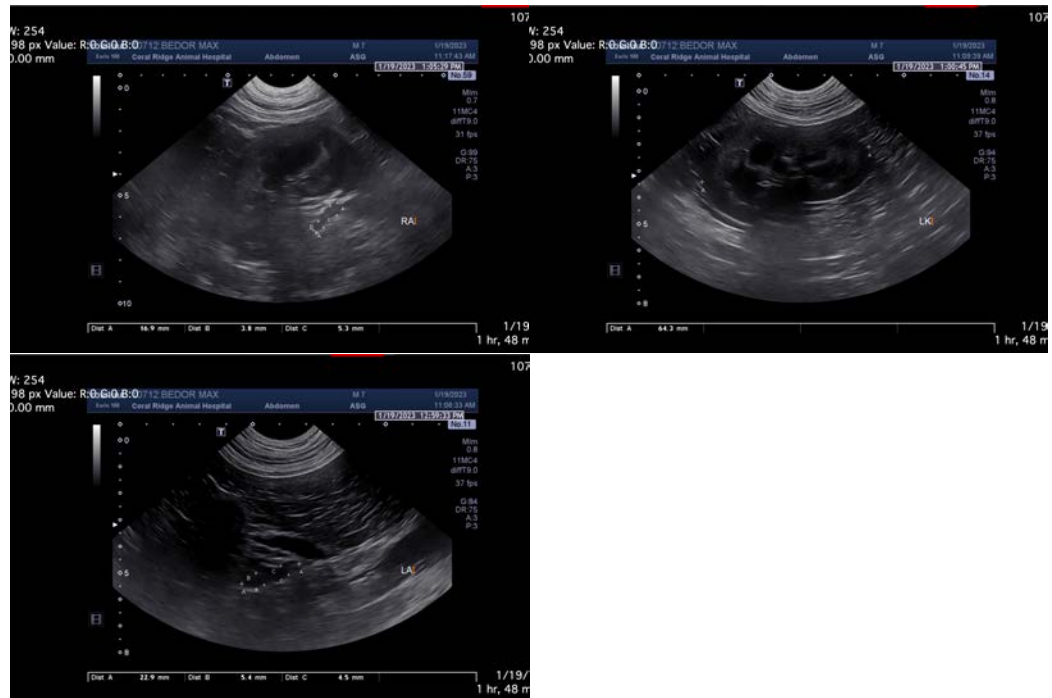
Neutered Male

**AGE**

8 Years

**WEIGHT**

75 Pounds



**INTERPRETED BY**

Kathleen Sennello DVM,  
MS, Diplomate ACVIM  
(Small Animal Internal  
Medicine)

The information and recommendations provided are based on the images presented by the referring veterinarian/sonographer. No evaluation can be communicated regarding pathology that was not visible in the image/video clips provided.

Thank you for this referral. If the clinical or image interpretation does not parallel your findings or if I can be of any further assistance please contact me.

**IMAGING PERFORMED BY**

Dr. Arch Gordon

Kathleen Sennello DVM,MS, Diplomate ACVIM (Small animal Internal Medicine)

kathleen.sennello@sonopath.com

**HOSPITAL NAME**

Coral Ridge AH

**REFERRING VET**

Dr. Arch Gordon

**INVOICE**

44393

**DATE**

1/19/23