



**PATIENT**

Maverick Grady

**SPECIES**

Canine

**BREED**

German Shepherd

**SEX**

Neutered Male

**AGE**

4.5 Years

**WEIGHT**

55.1 kg

**INTERPRETED BY**

Kathleen Sennello DVM,  
MS, Diplomate ACVIM  
(Small Animal Internal  
Medicine)

**IMAGING PERFORMED BY**

Dr. Trudeau

**HOSPITAL NAME**

Petworks VH

**REFERRING VET**

Dr. Trudeau

**INVOICE**

44361

**DATE**

1/19/23

**PRESENTING CLINICAL SIGNS**

Hx of AG fistulas; degenerative myelopathy, supraventricular arrhythmias with supraventricular tachycardia Presented icteric today otherwise eating and acting well. Was treated for bacterial dermatitis (simplicef) Meds: Cyclosporin 100mg BID Tylenol 500 mg TID \*\*\*\* Requested that owner discontinue this medication as of today Pimobendan 12.5mg BID Sodalolol 40mg BID Gabapentin 400mg BID Prednisone 50mg SID ( Simplicef finished 2 days ago)

Abnormal PE/Chem/CBC/UA Results: CBC - WBC 26.36 ( neutrophilia, monocytosis) CHEM - CREA 39; ALT 2469; ALP 2136; GGT 278; TBIL 80 Lepto PCR - pending U/A - pending

**ULTRASONOGRAPHIC EXAMINATION OF THE ABDOMEN**

**Urinary System**

The urinary bladder is moderately distended with anechoic urine. The Bladder wall, trigone, ureteral papillae and visible urethra (to a depth of 2cm) appear normal with no evidence of wall thickening, mucosal irregularities, masses or cystic calculi.

The prostate is normal in size (1.25 cm) and shape for this neutered male dog. The parenchyma is homogenous and the external margins are smooth. The prostatic urethra appears normal with no evidence of irregularity, invasion, mass effect or calculi.

The left kidney has a normal shape and size (9.44 cm). Overall echogenicity is normal with adequate corticomedullary distinction and a typical 1:3 cortex:medulla ratio. There is no evidence of focal perinephric inflammation or effusion. There is no evidence of pyelectasia, nephroliths, infarcts or hydroureter. Renal vasculature is normal.

The right kidney has a normal shape and size (7.1 cm). Overall echogenicity is normal with adequate corticomedullary distinction and a typical 1:3 cortex:medulla ratio. There is no evidence of focal perinephric inflammation or effusion. There is no evidence of pyelectasia, nephroliths, infarcts or hydroureter. Renal vasculature is normal.

**Adrenal Glands**

The region of left adrenal (Cranial to left renal artery) is unremarkable but the adrenal is not distinctly visualized. No evidence of a mass effect is visualized.

The region of the right adrenal (between right cranial kidney and vena cava) is unremarkable, but the adrenal is not distinctly visualized. No evidence of a mass effect is visualized.

**Spleen**

The spleen is subjectively normal in size, echotexture is homogenous, and the splenic capsule is smooth with no irregularities. The blood flow through the hilus and splenic parenchyma appears normal. No focal parenchymal abnormalities are visualized.

**Liver**

The liver is large, hyperechoic, and heterogeneous. The visible portions of the vasculature and biliary tract appear normal. No focal nodules or cystic lesions are observed.

The gallbladder lumen is moderately distended. The wall of the gall bladder is not thickened and has a smooth mucosal surface. Luminal contents are mild and primarily anechoic. The cystic and common bile ducts are normal/not visible.



**PATIENT**

Maverick Grady

**SPECIES**

Canine

**BREED**

German Shepherd

**SEX**

Neutered Male

**AGE**

4.5 Years

**WEIGHT**

55.1 kg

**INTERPRETED BY**

Kathleen Sennello DVM,  
MS, Diplomate ACVIM  
(Small Animal Internal  
Medicine)

**IMAGING  
PERFORMED BY**

Dr. Trudeau

**HOSPITAL NAME**

Petworks VH

**REFERRING VET**

Dr. Trudeau

**INVOICE**

44361

**DATE**

1/19/23

**Gastrointestinal**

The stomach is mildly dilated with fluid and irregular shadowing material most consistent with normal ingesta and gas. It measures at a normal thickness of <0.7cm with some variability due to the presence of rugal folds. The distinction of the gastric wall layering is adequate and there is no impression of reduced peristaltic activity. No masses or focal lesions were observed.

The visualized areas of duodenum, jejunum and ileum have a relatively uniform diameter with minimal fluid distension. Wall thickness is normal. Bowel loops follow a curvilinear path with distinct wall layering maintaining the typical 1:3 muscularis:mucosa layer ratio. Jejunum wall measures 0.42 cm. Visualized peristalsis appears appropriate. There were no focal lesions consistent with obstruction or a mass effect observed.

The ileocecal junction was visualized and exhibited normal intact wall layering and is subjectively of normal thickness. Sections of colon are visualized with formed fecal material and gas shadowing distally. There is no observed focal or generalized colon wall thickening or loss of layering.

**Pancreas**

The pancreas is normal and isoechoic to surrounding mesentery. There is no evidence of nodules or cystic lesions. There is no evidence of regional mesenteric inflammation or fluid.

**Free Abdomen**

Evaluation of the peritoneal cavity did not reveal any evidence of effusion, or subjective lymphadenomegaly. The Medial iliac nodes appear normal and there was no evidence of a caudal aortic thrombus at the bifurcation. The omentum is of normal uniform echogenicity.

**ULTRASONOGRAPHIC FINDINGS**

- Large, heterogeneous liver – The diffuse hepatic changes are non-specific and could be consistent with vacuolar hepatopathy, nodular hyperplasia, inflammatory/immune-mediated disease, fibrosis, extramedullary hematopoiesis, toxic hepatopathy (e.g., copper), infiltrative neoplasia (less likely) or other hepatopathy.

**INTERPRETATION OF THE FINDINGS & FURTHER RECOMMENDATIONS**

The liver appears large and heterogeneous. The gallbladder appears relatively normal with no obvious evidence of biliary disease. The appearance of the liver could be due to chronic steroid therapy, and as mentioned, it is likely that both adrenals are small, making them difficult to visualize on today's scan in this deep chested dog. My primary concern would be acute liver injury.

There is significant polypharmacy going on, and many of these medications could have potential toxic side effects, particularly if used in conjunction with each other. In particular, regarding the Tylenol (while the dose is not inappropriate), toxicity can be seen with more chronic use. I would recommend treatment for acute liver injury with supportive care (IV fluids, nausea medications, +/- antibiotics, Ursodiol, etc.), and if possible, pare down medications to what is absolutely necessary (consider discontinuing the Cyclosporin, the Tylenol, reducing the Prednisone dose, etc., provided this is not medically contraindicated).

If liver values do not start to improve, then consider a liver biopsy (provided coagulation parameters are normal). You could consider a fine needle aspirate prior to this to rule out round cell neoplasia.



**PATIENT**

Maverick Grady

**SPECIES**

Canine

**BREED**

German Shepherd

**SEX**

Neutered Male

**AGE**

4.5 Years

**WEIGHT**

55.1 kg

**INTERPRETED BY**

Kathleen Sennello DVM,  
MS, Diplomate ACVIM  
(Small Animal Internal  
Medicine)

**IMAGING  
PERFORMED BY**

Dr. Trudeau

**HOSPITAL NAME**

Petworks VH

**REFERRING VET**

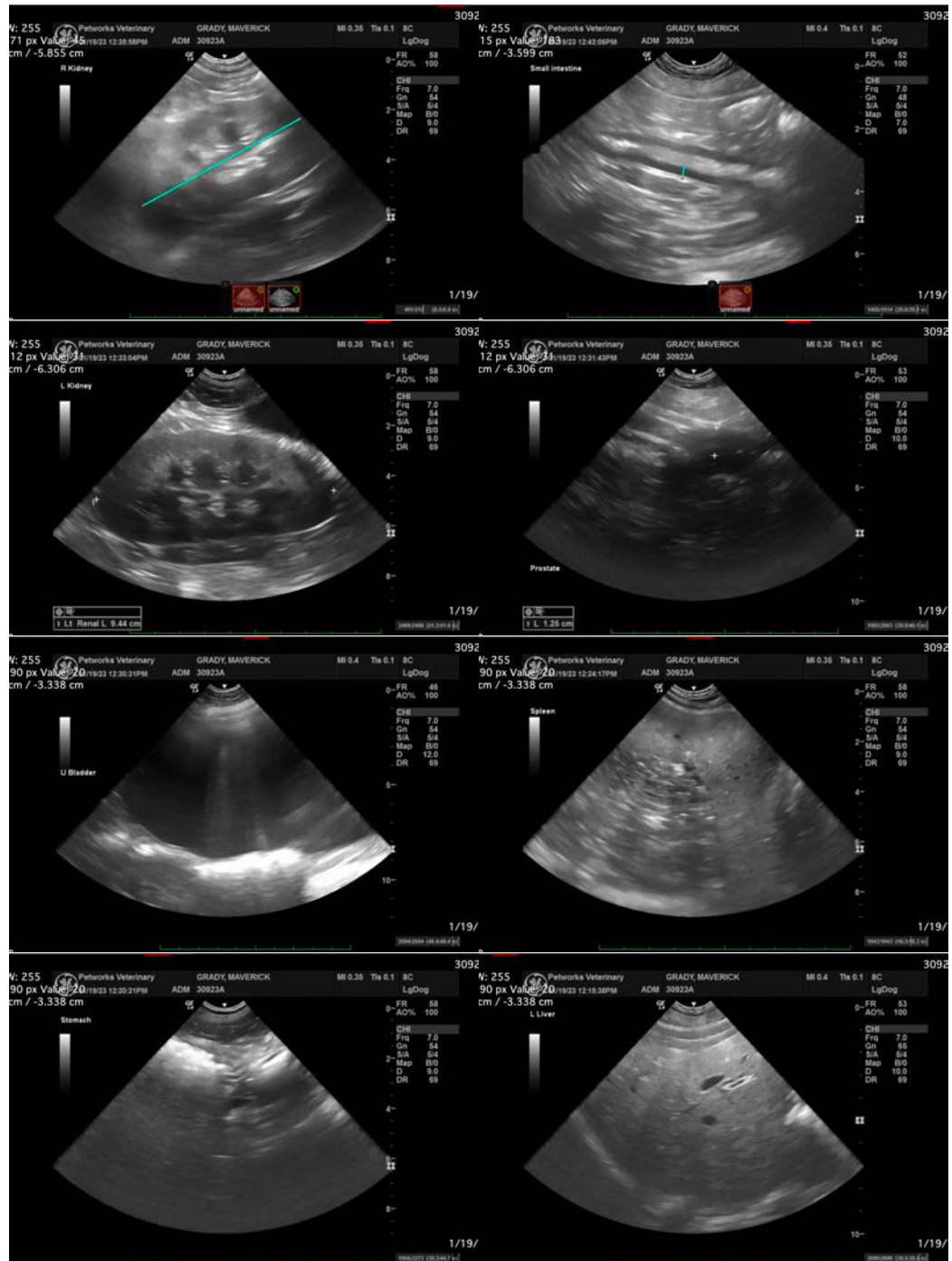
Dr. Trudeau

**INVOICE**

44361

**DATE**

1/19/23





**PATIENT**

Maverick Grady

**SPECIES**

Canine

**BREED**

German Shepherd

**SEX**

Neutered Male

**AGE**

4.5 Years

**WEIGHT**

55.1 kg

**INTERPRETED BY**

Kathleen Sennello DVM,  
MS, Diplomate ACVIM  
(Small Animal Internal  
Medicine)

**IMAGING  
PERFORMED BY**

Dr. Trudeau

**HOSPITAL NAME**

Petworks VH

**REFERRING VET**

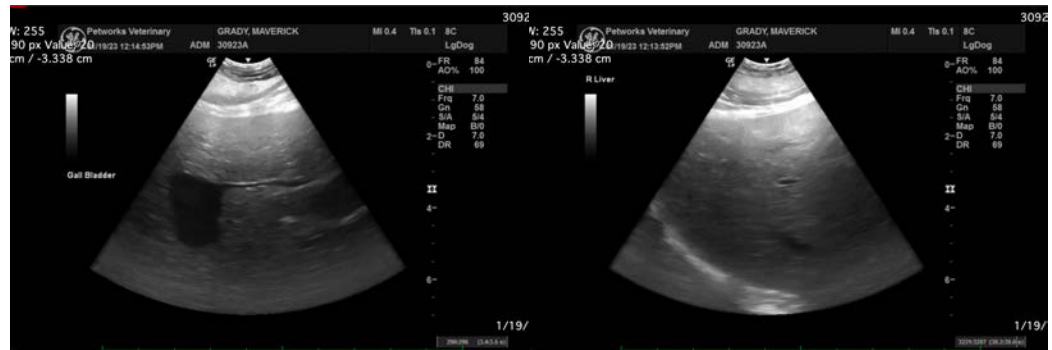Dr. Trudeau

**INVOICE**

44361

**DATE**

1/19/23



The information and recommendations provided are based on the images presented by the referring veterinarian/sonographer. No evaluation can be communicated regarding pathology that was not visible in the image/video clips provided.

Thank you for this referral. If the clinical or image interpretation does not parallel your findings or if I can be of any further assistance please contact me.

Kathleen Sennello DVM,MS, Diplomate ACVIM (Small animal Internal Medicine)

kathleen.sennello@sonopath.com