



PATIENT

Lola Gervais

SPECIES

Canine

BREED

Pit Bull

SEX

Spayed Female

AGE

7.5 Years

WEIGHT

79 Pounds

INTERPRETED BY

Kathleen Sennello DVM,
MS, Diplomate ACVIM
(Small Animal Internal
Medicine)

IMAGING PERFORMED BY

Emily Kirk

HOSPITAL NAME

Shiloh AH

REFERRING VET

Dr. Shana Silverstein

INVOICE

44391

DATE

1/19/23

PRESENTING CLINICAL SIGNS

Splenic HSA removed 7/21/22. Patient has been doing well clinically. Scan is performed to screen for metastatic disease.

Abnormal PE/Chem/CBC/UA Results: CBC and chem unremarkable

ULTRASONOGRAPHIC EXAMINATION OF THE ABDOMEN

Urinary System

The urinary bladder is moderately distended with anechoic urine. The Bladder wall, trigone, ureteral papillae and visible urethra (to a depth of 2cm) appear normal with no evidence of wall thickening, mucosal irregularities, masses or cystic calculi.

The left kidney has a normal shape and size (6.8 cm). Overall echogenicity is normal with adequate corticomedullary distinction and a typical 1:3 cortex:medulla ratio. There is no evidence of focal perinephric inflammation or effusion. There is no evidence of pyelectasia, nephroliths, infarcts or hydroureter. Renal vasculature is normal.

The right kidney has a normal shape and size (7.62 cm). Overall echogenicity is normal with adequate corticomedullary distinction and a typical 1:3 cortex:medulla ratio. There is no evidence of focal perinephric inflammation or effusion. There is no evidence of pyelectasia, nephroliths, infarcts or hydroureter. Renal vasculature is normal.

Adrenal Glands

The left adrenal gland is normal in size measuring 0.66 cm at the caudal pole. It is observed in its normal position cranial to the left renal artery. It is normal in appearance (uniformly hypoechoic) and shape with no evidence of a mass effect.

The region of the right adrenal (between right cranial kidney and vena cava) is unremarkable, but the adrenal is not distinctly visualized. No evidence of a mass effect is visualized.

Spleen

The spleen is surgically absent, removed 7/2022 due to hemangiosarcoma.

Liver

The liver is subjectively normal in size, and echogenicity with smooth peripheral margins. The parenchyma is homogenous echotexture. The visible portions of the vasculature and biliary tract appear normal. No focal nodules or cystic lesions are observed.

The gallbladder lumen is moderately distended. The wall of the gall bladder is not thickened and has a smooth mucosal surface. Luminal contents are mild and primarily anechoic. The cystic and common bile ducts are normal/not visible.

Gastrointestinal

The stomach contains moderate fluid/ingesta. It measures at a normal thickness of <0.7cm with some variability due to the presence of rugal folds. The distinction of the gastric wall layers is adequate and there is no impression of reduced peristaltic activity. No masses or focal lesions were observed.

The visualized areas of duodenum, jejunum and ileum have a relatively uniform diameter with minimal fluid distension. Wall thickness is normal. Bowel loops follow a curvilinear path with distinct wall



PATIENT

Lola Gervais

layering maintaining the typical 1:3 muscularis:mucosa layer ratio. Duodenum wall measures 0.47 cm. Jejunum wall measures 0.28 cm. Visualized peristalsis appears appropriate. There were no focal lesions consistent with obstruction or a mass effect observed.

SPECIES

Canine

The ileocecal junction was visualized and exhibited normal intact wall layering and is subjectively of normal thickness. Sections of colon are visualized with formed fecal material and gas shadowing distally. There is no observed focal or generalized colon wall thickening or loss of layering.

BREED

Pit Bull

Pancreas

The pancreas is normal and isoechoic to surrounding mesentery. There is no evidence of nodules or cystic lesions. There is no evidence of regional mesenteric inflammation or fluid.

SEX

Spayed Female

Free Abdomen

Evaluation of the peritoneal cavity did not reveal any evidence of effusion. The sublumbar lymph node is normal, measuring 0.55 cm. The omentum is of normal echogenicity.

AGE

7.5 Years

ULTRASONOGRAPHIC FINDINGS

WEIGHT

79 Pounds

- Spleen surgically removed 7/2022 due to hemangiosarcoma
- Moderate fluid/ingesta within the gastric lumen – findings are most consistent with a non-fasted patient.

INTERPRETED BY

Kathleen Sennello DVM,
MS, Diplomate ACVIM
(Small Animal Internal
Medicine)

INTERPRETATION OF THE FINDINGS & FURTHER RECOMMENDATIONS

There are no lesions visualized associated with the omentum, liver, or other areas consistent with metastatic disease. At this time, continued monitoring is warranted.

IMAGING PERFORMED BY

Emily Kirk

HOSPITAL NAME

Shiloh AH

REFERRING VET

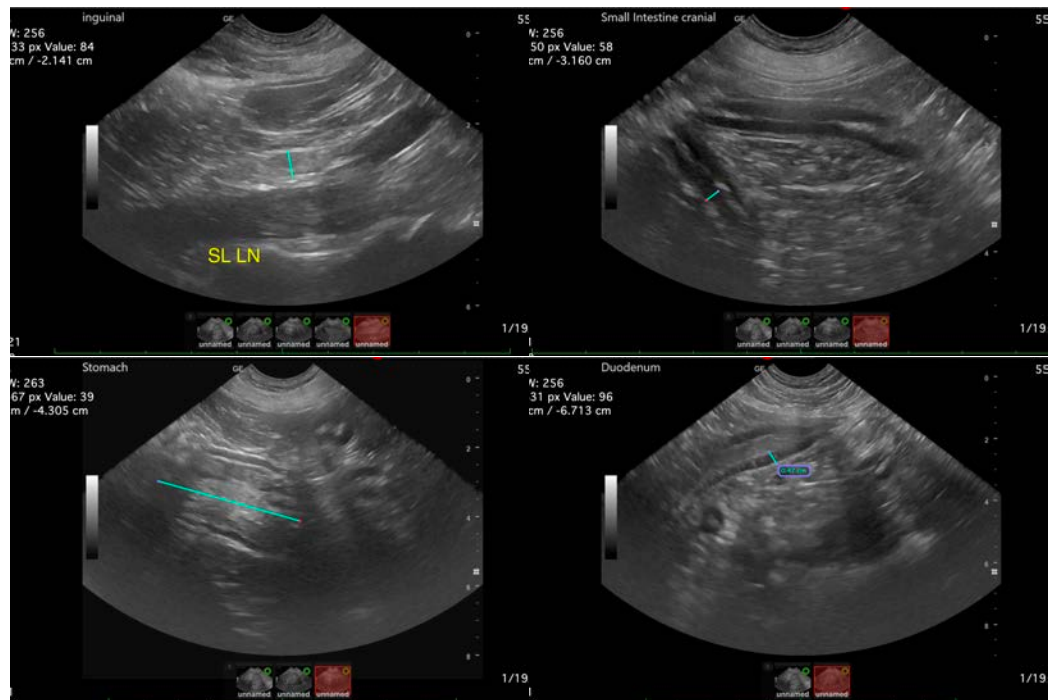
Dr. Shana Silverstein

INVOICE

44391

DATE

1/19/23





PATIENT

Lola Gervais

SPECIES

Canine

BREED

Pit Bull

SEX

Spayed Female

AGE

7.5 Years

WEIGHT

79 Pounds

INTERPRETED BY

Kathleen Sennello DVM,
MS, Diplomate ACVIM
(Small Animal Internal
Medicine)

**IMAGING
PERFORMED BY**

Emily Kirk

HOSPITAL NAME

Shiloh AH

REFERRING VET

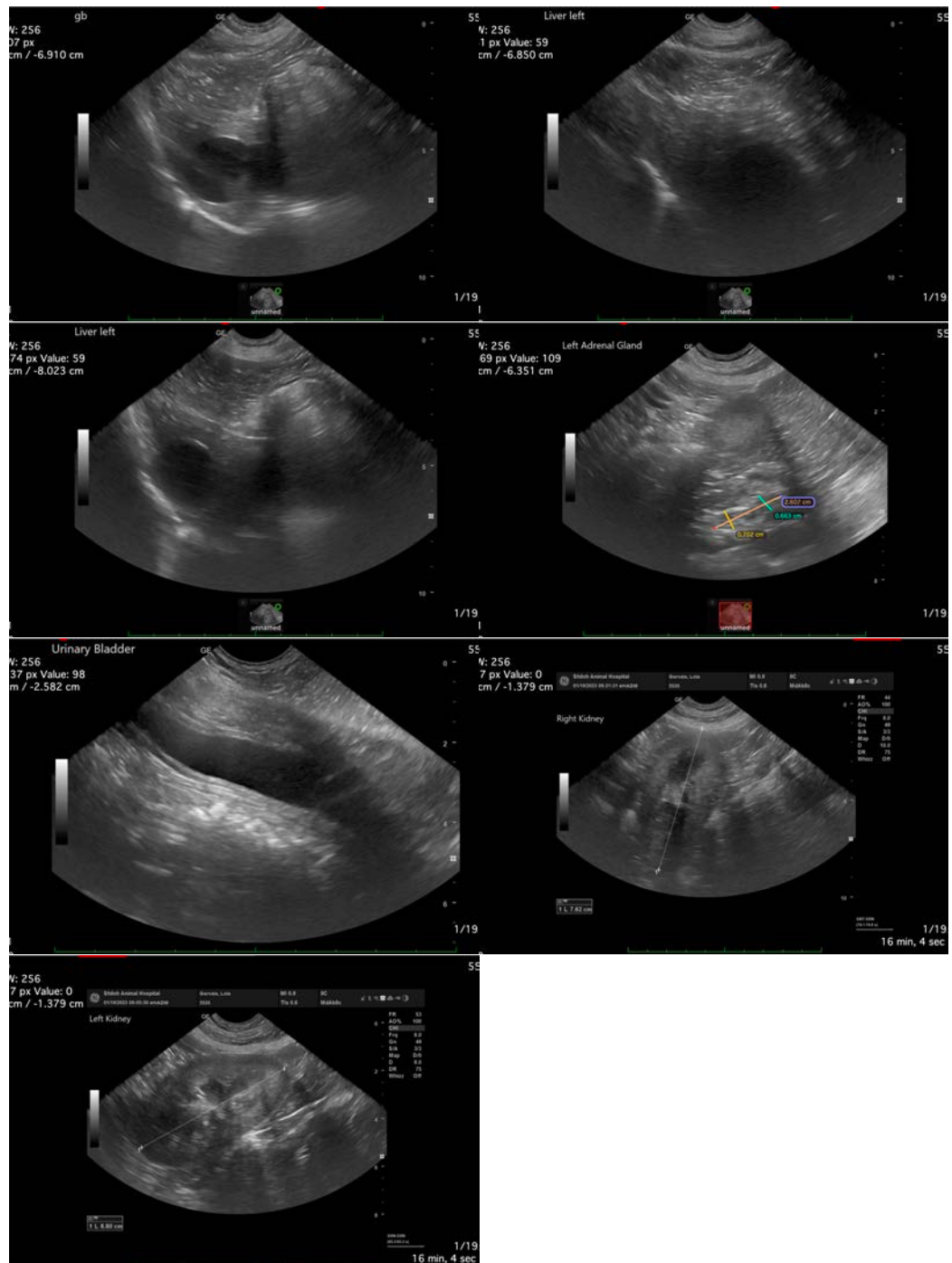
Dr. Shana Silverstein

INVOICE

44391

DATE

1/19/23



The information and recommendations provided are based on the images presented by the referring veterinarian/sonographer. No evaluation can be communicated regarding pathology that was not visible in the image/video clips provided.

Thank you for this referral. If the clinical or image interpretation does not parallel your findings or if I can be of any further assistance please contact me.

Kathleen Sennello DVM,MS, Diplomate ACVIM (Small animal Internal Medicine)

kathleen.sennello@sonopath.com