

IMAGING PERFORMED BY

IntraPet.com



SonoPath

Clinical Sonography & Telecytology

EDUCATIONAL TELECONSULTATION SERVICES™

1-800-838-4268 info@sonopath.com SonoPath.com

DATE PRESENTING CLINICAL SIGNS

1/18/22

History: Presenting Complaint: Back Pain; Vomiting. Date: 01-17-2022 Notes: Was here about 2 weeks ago for back pain, possibly abdominal pain. On exam she exhibited more back pain and was eating w/no vomiting; Chem 10 WNL, so treated w/pain medication, Gabapentin, and Methocarbamol. She improved and owner felt like she was doing well until yesterday. Owner noticed that her belly appeared distended and firm. She was eating but appetite was reduced. This morning she vomited. Was treated for pancreatitis 2 years ago, took about 6 weeks for her to fully recover from that; then about a few weeks to a month after that she exhibited back pain/neurologic deficits in hind limbs. Assessment: r/o abdominal pain vs back pain; pancreatitis, gastroenteritis, neoplasia; back - muscle pain vs IVDD

PATIENT

Lizzie Starks

SPECIES

Canine

BREED

Shih Tzu

Current Medications: Buprenex in hospital.
Lab Results: Attached separately.
Date of Previous IntraPet Ultrasound: No previous IntraPet scans.
Sedation: Not required to complete full diagnostic ultrasound.
Stat Report: Not requested.

SEX

Spayed Female

ULTRASONOGRAPHIC EXAMINATION OF THE ABDOMEN

AGE

11/8/11

Urinary System

The urinary bladder is rounded and significantly distended with anechoic urine. The Bladder wall, trigone, ureteral papillae and visible urethra (to a depth of 2cm) appear normal with no evidence of wall thickening, mucosal irregularities, or masses. There is a small flat area of mineralization in the dependent portion of the urinary bladder, measuring 0.42 cm, consistent with a small stone.

WEIGHT

12.9 Pounds

The left kidney has a normal shape and size (3.99 cm) with numerous non-obstructive nephroliths varying in size from 0.2-0.5 cm. Overall echogenicity is slightly hyperechoic with poor corticomedullary distinction and a typical 1:3 cortex:medulla ratio. There is no evidence of perinephric inflammation or effusion. There is no evidence of pyelectasia, infarcts or hydroureter. Renal vasculature is normal.

INTERPRETED BY

Kathleen Sennello DVM,
MS, Diplomate ACVIM
(Small Animal Internal
Medicine)

The right kidney has a normal shape and size (4.59 cm) with multiple non-obstructive nephroliths, the largest measuring 0.42 cm. Overall echogenicity is slightly hyperechoic with poor corticomedullary distinction and a typical 1:3 cortex:medulla ratio. There is no evidence of perinephric inflammation or effusion. There is no evidence of pyelectasia, infarcts or hydroureter. Renal vasculature is normal.

IMAGING PERFORMED BY

Rachel Brillhart RDMS

Adrenal Glands

The left adrenal gland is normal in size measuring 0.82 cm at the caudal pole. It is observed in its normal position cranial to the left renal artery. It is normal in appearance (uniformly hypoechoic) and shape with no evidence of a mass effect.

HOSPITAL NAME

Animal Emergency
Hospital

The right adrenal gland is normal in size measuring 0.51 cm at the caudal pole. It is observed in its normal position between the cranial aspect of the right kidney and the caudal vena cava. It is normal in appearance (uniformly hypoechoic) and shape with no evidence of a mass effect.

REFERRING VET

Dr. Martinoli

Spleen

The spleen is subjectively normal in size, echotexture is homogenous, and the splenic capsule is smooth with no irregularities. The blood flow through the hilus and splenic parenchyma appears normal. No focal parenchymal abnormalities are visualized.

INVOICE

34354

Liver

The liver is large in size with smooth peripheral margins. The parenchyma is hyperechoic and homogenous in echotexture. The visible portions of the vasculature and biliary tract appear normal. No focal nodules or cystic lesions are observed.

The gall bladder lumen is moderately distended. The wall of the gall bladder is not thickened and has a smooth mucosal surface. There is a moderate amount of non-organized echogenic debris. The cystic and common bile ducts are normal/not visible.

Gastrointestinal

The stomach contains minimal luminal contents. It measures at a normal thickness of <0.7cm with some variability due to the presence of rugal folds. The distinction of the gastric wall layers is adequate and there is no impression of reduced peristaltic activity. No masses or focal lesions were observed.

The visualized areas of duodenum, jejunum and ileum have a relatively uniform diameter with minimal fluid distension. Wall thickness is normal. Bowel loops follow a curvilinear path with distinct wall layering maintaining the typical 1:3 muscularis:mucosa layer ratio. The duodenum measured as normal (between 0.3-0.5cm in wall thickness) and the jejunum measured as normal (between 0.2-0.47cm.) Visualized peristalsis appears appropriate. There were no focal lesions consistent with obstruction or a mass effect observed.

The ileocecal junction was visualized and exhibited normal intact wall layering and is subjectively of normal thickness. Sections of colon are visualized with formed fecal material and gas shadowing distally. There is no observed focal or generalized colon wall thickening or loss of layering.

Pancreas

The pancreas is prominent and mottled compared to the surrounding isoechoic mesentery. There is no evidence of nodules or cystic lesions. There is no evidence of regional mesenteric inflammation or fluid.

Free Abdomen

Evaluation of the peritoneal cavity did not reveal any evidence of effusion, or subjective lymphadenomegaly. The Medial iliac nodes appear normal and there was no evidence of a caudal aortic thrombus at the bifurcation. The omentum is of normal uniform echogenicity.

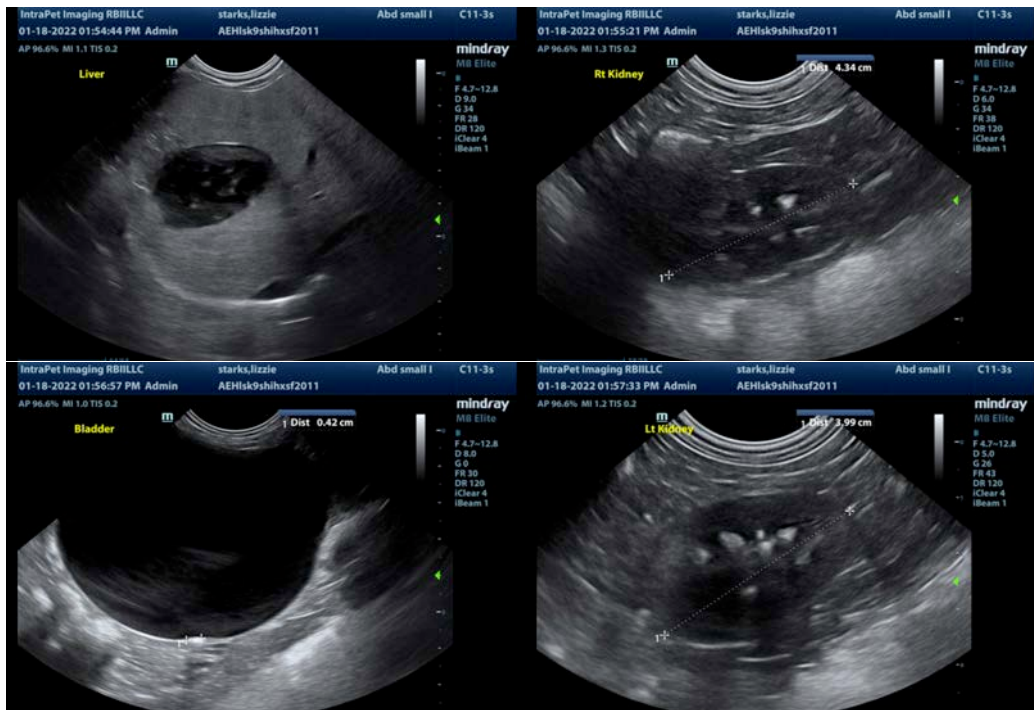
ULTRASONOGRAPHIC FINDINGS

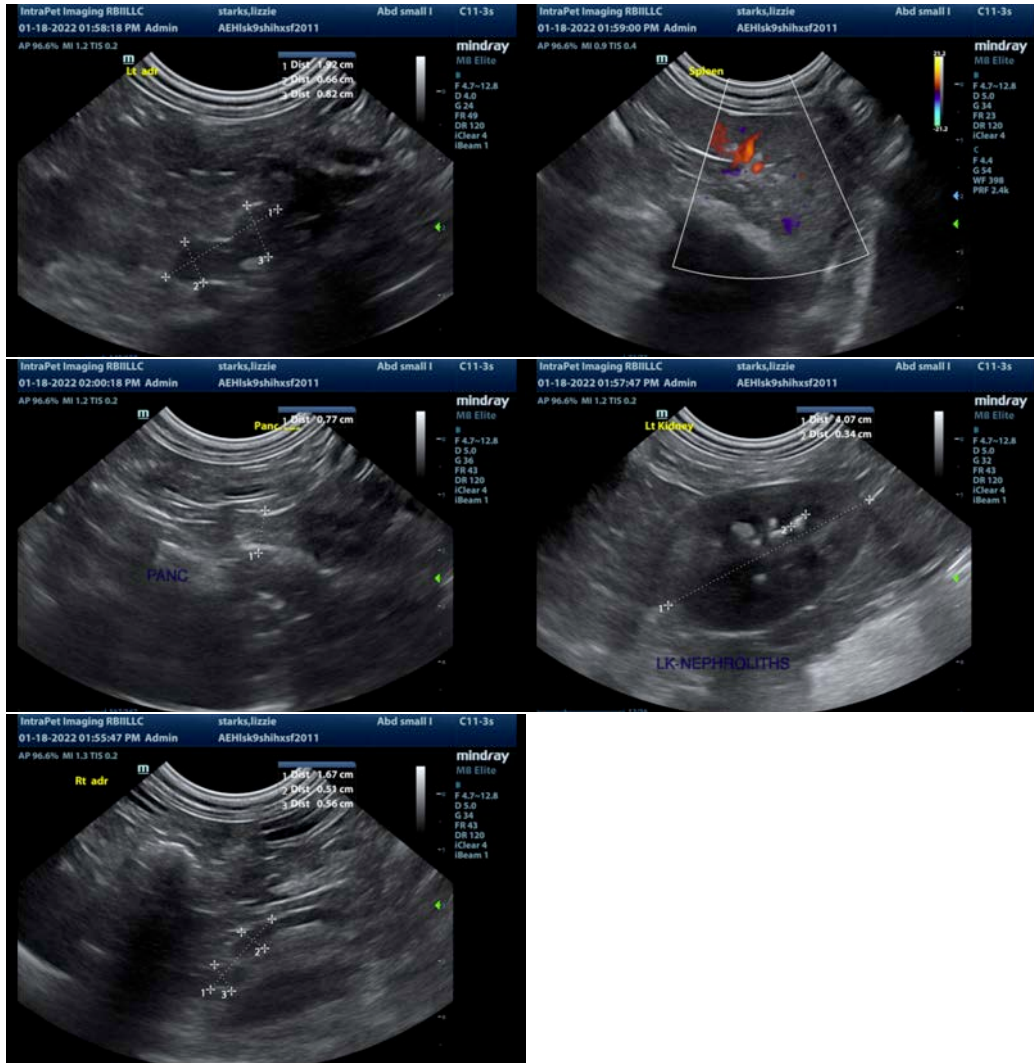
- Decreased corticomedullary distinction in both kidneys with bilateral non-obstructive nephroliths – Mild loss of corticomedullary distinction in both kidneys could be consistent with chronic degenerative disease or interstitial nephrosis. The hyperechoic mineralized foci observed at the corticomedullary junction of the left/right kidney are consistent with small, non-obstructive nephroliths.
- Distended urinary bladder with small dependent mineralization – most consistent with a small stone or mineralized debris. Correlate with abdominal radiographs and ensure the patient can urinate freely.
- Prominent, mottled pancreas – The pancreatic changes are most consistent with mild pancreatitis or a recent episode of pancreatic inflammation.
- Large, hyperechoic liver – The diffuse hepatic changes are non-specific and can be seen with vacuolar hepatopathy, reactive change, nodular hyperplasia or, less likely, inflammatory/immune-mediated disease, infiltrative neoplasia, or other hepatopathy.
- Moderate gallbladder debris – The significance of the aggregated gallbladder sludge is unclear. This could represent an early mucocele, cholestasis, or may be secondary to fasting.

INTERPRETATION OF THE FINDINGS & FURTHER RECOMMENDATIONS

There are stones visualized in both kidneys and a small shadowing structure within the urinary bladder. It is difficult to say if these are currently causing discomfort, as I do not see an obvious obstruction at this time, although small stone could be passed intermittently, etc. Additionally, there is no obvious inflammation around the kidneys, ureters or urinary bladder. The urinary bladder is very distended. This could be due to not wanting to urinate in the hospital, but ensure that there is not an obstruction or partial obstruction present based on visualization of the urine stream, etc. Additionally, the pancreas is slightly prominent. Sometimes the degree of pancreatic inflammation visualized on ultrasound does not always correlate with the clinical discomfort, etc. Consider GI panel to Texas A&M with a quantitative PLI, TLI, cobalamin and folate to further evaluate the pancreas. There is not a lot of significant peripancreatic inflammation visualized.

It can be difficult to discern between back pain and abdominal pain, particularly when there is no overt source but there are stones present. Consider urinalysis and culture to look for obvious evidence of blood, inflammation, infection, etc. Recommend testing for pancreatitis (as discussed above) along with symptomatic therapy for possible back pain. Consider a consultation with a veterinary neurologist who may aid in differentiating. Recommend continued monitoring of the stones in the kidneys and urinary bladder. At this time, I am concerned the bladder stone is very small, and a cystotomy may not be necessary.





The information and recommendations provided are based on the images presented by the referring veterinarian. No evaluation can be communicated regarding pathology that was not visible in the image/video clips provided.

Thank you for this referral. If the clinical or image interpretation does not parallel your findings or if I can be of any further assistance please contact me.

Kathleen Sennello DVM,MS, Diplomate ACVIM (Small animal Internal Medicine)
 kathleen.sennello@sonopath.com