



<b>DATE</b>	<b>PRESENTING CLINICAL SIGNS</b>
01/17/2023	About a month ago saw rDVM for vomiting with blood. (Vomited every 2-3 days for at least a week.) Was given Cerenia; owner thinks that was all that was Rx at the time. He did seem to recover from that. Today vomited a large amount, somewhat violently, then became extremely lethargic. He could stand, but preferred to lay down and not walk around. Seemed to have labored breathing. Owner said he had no problem getting him into the carrier and usually it takes him at least 20 minutes. Also has had intermittent diarrhea; usually about 2 times per month.
<b>PATIENT</b>	
Sylvester Lawrence	
<b>SPECIES</b>	Current Medications: Gabapentin, Acepromazine, Ondansetron.
Feline	Lab Results: Pro BNP abnormal 133.
<b>BREED</b>	Date of Previous IntraPet Ultrasound: No previous.
DLH	Sedation: IV propofol.
<b>SEX</b>	Stat Report: Not requested.
MN	Imaging Performed By: Rachel Brillhart, RDMS.
<b>AGE</b>	<b>ULTRASONOGRAPHIC EXAMINATION OF THE ABDOMEN</b>
2010	<b>Urinary System</b>
<b>WEIGHT</b>	The urinary bladder is moderately distended with anechoic urine. The Bladder wall, trigone, ureteral papillae and visible urethra (to a depth of 2cm) appear normal with no evidence of wall thickening, mucosal irregularities, masses or cystic calculi.
9.9lb	The left kidney has a normal shape and size. Decreased corticomedullary distinction present with a 0.51 cm non-obstructive nephrolith. There is no evidence of perinephric inflammation or effusion. Renal vasculature is normal. The left kidney measured 4.0 cm.
<b>INTERPRETED BY</b>	The right kidney has a normal shape and size. Decreased corticomedullary distinction present. A non-obstructive nephrolith measuring 0.47 cm was present. There is no evidence of perinephric inflammation or effusion. Renal vasculature is normal. The right kidney measured 3.8 cm.
Kathleen Sennello DVM, MS, Diplomate ACVIM (Small Animal Internal Medicine)	<b>Adrenal Glands</b>
<b>HOSPITAL NAME</b>	The left adrenal gland is normal in size measuring 0.47 cm at the caudal pole. It is observed in its normal position cranial to the left renal artery. It is normal in appearance (uniformly hypoechoic) and shape with no evidence of a mass effect.
Animal Emergency Hospital	The right adrenal gland is normal in size measuring 0.48 cm at the caudal pole. It is observed in its normal position between the cranial aspect of the right kidney and the caudal vena cava. It is normal in appearance (uniformly hypoechoic) and shape with no evidence of a mass effect.
<b>REFERRING VET</b>	<b>Spleen</b>
Dr. Martinoli	The spleen is subjectively normal in size, echotexture is homogenous, and the splenic capsule is smooth with no irregularities. The blood flow through the hilus and splenic parenchyma appears normal. No focal parenchymal abnormalities are visualized. The spleen measured 0.87 cm in width at the level of the hilus.
<b>INVOICE</b>	<b>Liver</b>
12728ag	

The liver is subjectively normal in size, and echogenicity with smooth peripheral margins. The parenchyma is homogenous echotexture. The visible portions of the vasculature and biliary tract appear normal. No focal nodules or cystic lesions are observed.

The gallbladder lumen is moderately distended. The wall of the gall bladder is not thickened and has a smooth mucosal surface. Luminal contents are primarily anechoic. The cystic and common bile ducts are normal/not visible.

### ***Gastrointestinal***

The stomach contains minimal luminal contents. It measures at a normal thickness of <0.36cm with some variability due to the presence of rugal folds. The distinction of the gastric wall layers is adequate and there is no impression of reduced peristaltic activity. No masses or focal lesions were observed.

The visualized areas of duodenum, jejunum and ileum have a relatively uniform diameter with minimal fluid distension. Wall thickness is normal. Bowel loops follow a curvilinear path with distinct wall layering maintaining the typical 1:3 muscularis:mucosa layer ratio. There is a focal section of small bowel which appears to be duodenum with thickening and reduced detail wall layering, in this region the bowel measured 0.32 cm in width. Visualized peristalsis appears appropriate. There were no focal lesions consistent with obstruction or a mass effect observed.

The ileocecal junction was visualized and exhibited normal intact wall layering and is subjectively of normal thickness. Sections of colon are visualized with formed fecal material and gas shadowing distally. There is no observed focal or generalized colon wall thickening or loss of layering.

### ***Pancreas***

The pancreas is normal and isoechoic to surrounding mesentery. There is no evidence of nodules or cystic lesions. There is no evidence of regional mesenteric inflammation or fluid.

### ***Free Abdomen***

Evaluation of the peritoneal cavity did not reveal any evidence of effusion. There are prominent mesenteric lymph nodes around the focal bowel thickening measuring 0.51 cm and 0.52 cm in diameter. The omentum is hyperechoic in the cranial abdomen.

### ***Other***

A brief view of the heart reveals a somewhat cystic appearing mass effect in the cranial thorax most consistent with a cystic mediastinal mass or lymph node measuring 3.0 cm x 1.0 cm.

## **ULTRASONOGRAPHIC FINDINGS**

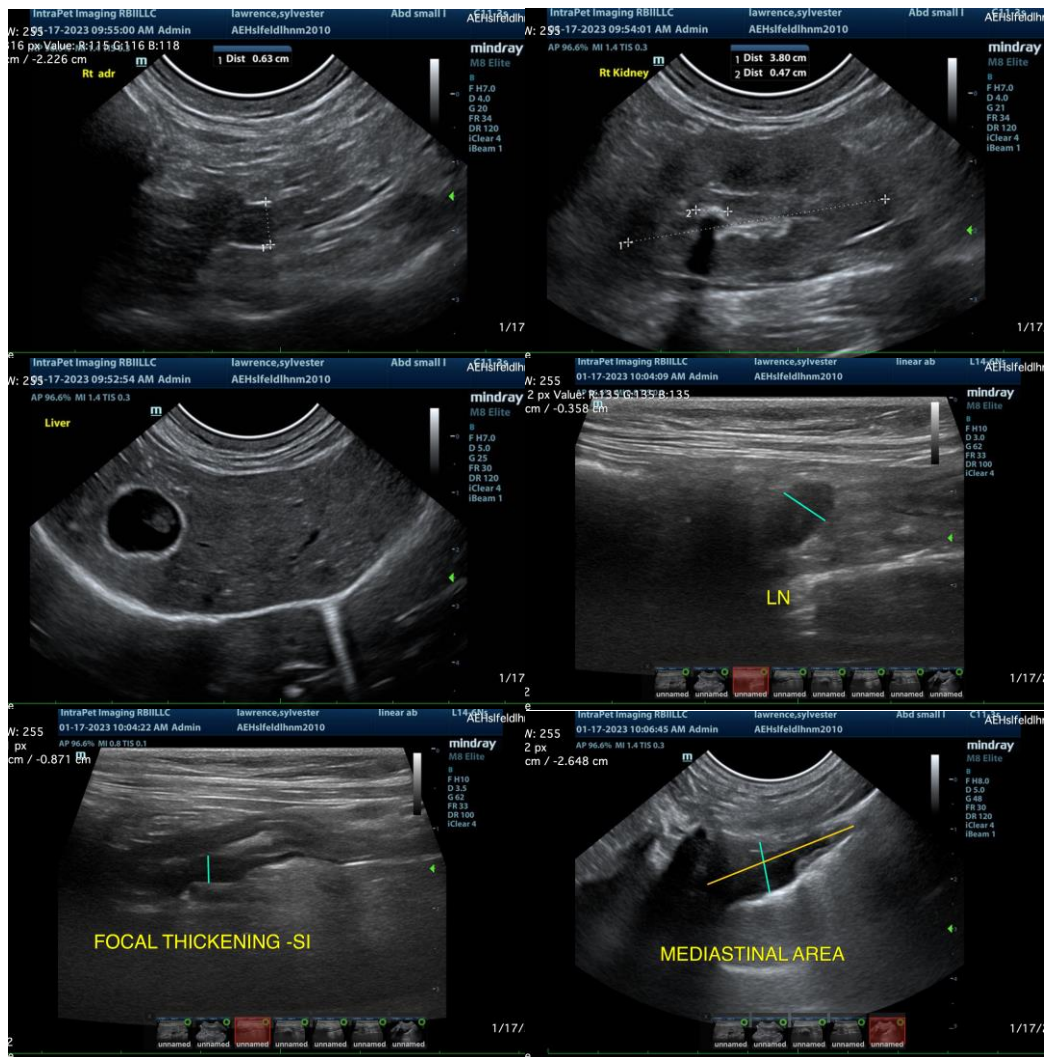
- Decreased corticomedullary distinction in both kidneys with non-obstructive nephroliths. The bilateral renal findings are consistent with age-related change.
- Focal area of bowel thickening with reduced detail wall layering. Findings could be consistent with inflammation, infection or more likely infiltrative disease (round cell neoplasia etc.)
- The prominent abdominal lymph nodes are most consistent with reactive lymphadenitis or lymphoid hyperplasia. Neoplastic infiltration is considered less likely.

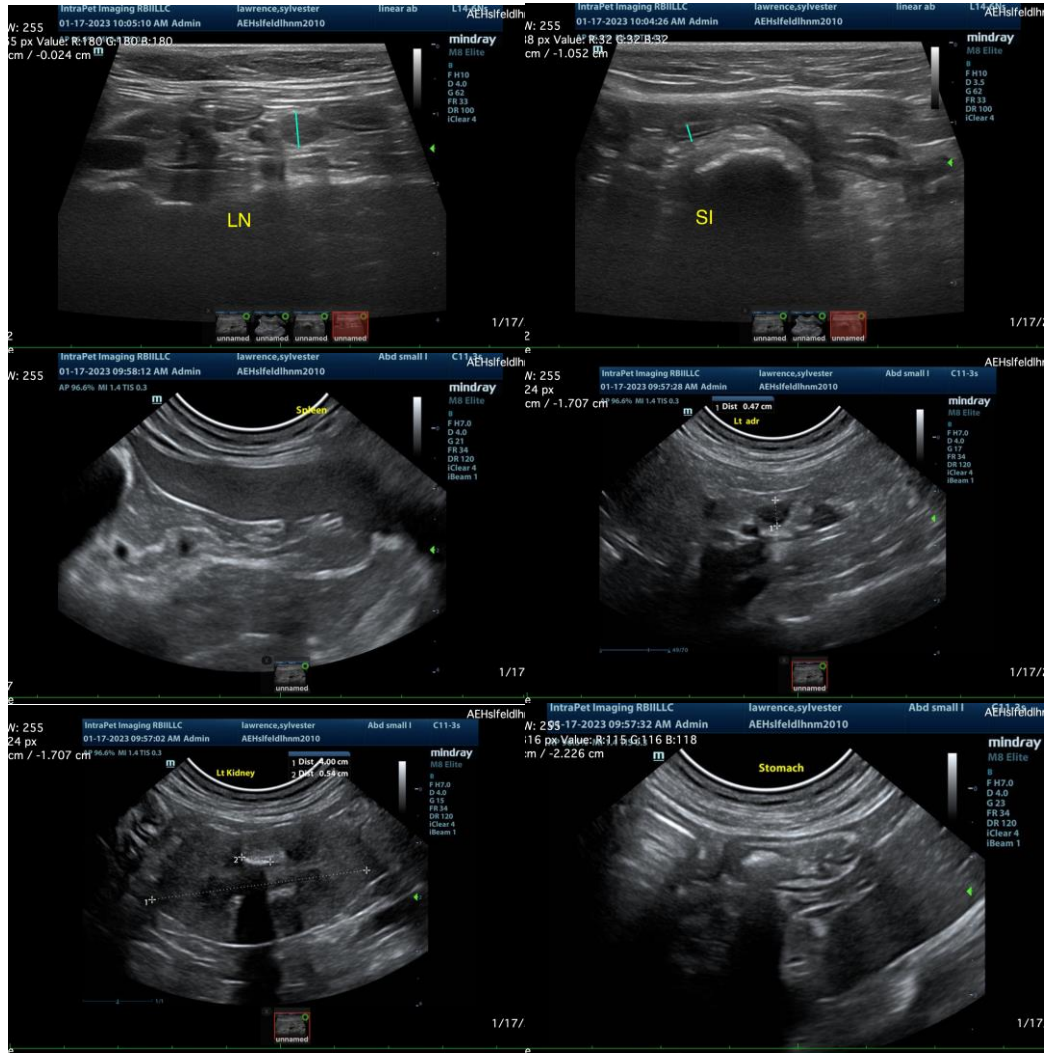
## **INTERPRETATION OF THE FINDINGS & FURTHER RECOMMENDATIONS**

There is no overt evidence of an obstruction on today's exam but there is some fluid dilation in the proximal small bowel with a focal area of bowel wall thickening and irregularity which is concerning for possible infiltrative disease as there is additionally some prominent lymph nodes in the region. A focal inflammatory process cannot be definitively ruled out. Consider a FNA of a mesenteric lymph node or biopsies of the GI

tract to further evaluate this region.

There is a somewhat cystic appearing lesion visualized in the mediastinal region of the thorax. This could be consistent with a cystic lymph node, thymoma, lymphoma etc. If a diagnosis cannot be obtained based on abdominal evaluation a FNA could be considered. Recommend three view thoracic radiographs.





The information and recommendations provided are based on the images presented by the referring veterinarian/sonographer. No evaluation can be communicated regarding pathology that was not visible in the image/video clips provided.

Thank you for this referral. If the clinical or image interpretation does not parallel your findings or if I can be of any further assistance please contact me.

Kathleen Sennello DVM,MS, Diplomate ACVIM (Small animal Internal Medicine)  
 kathleen.sennello@sonopath.com