



## PATIENT

Pongo Church

## SPECIES

Canine

## BREED

Dalmatian

## SEX

Neutered Male

## AGE

7 Years

## WEIGHT

31.4 kg

## INTERPRETED BY

Kathleen Sennello DVM,  
MS, Diplomate ACVIM  
(Small Animal Internal  
Medicine)

## IMAGING PERFORMED BY

Dr. Iacovides

## HOSPITAL NAME

Oakbank Animal  
Hospital

## REFERRING VET

Dr. Youngs

## INVOICE

72267

## DATE

1/15/26

## PRESENTING CLINICAL SIGNS

Owner thinks it was his leg that was painful, but now suspects abdominal pain - 2 week history of crying out randomly at night while in bed with owners. Seems restless for a bit after then goes back to sleep - Yelped after sneezing one time - No other symptoms. Was seen for this in 7/25 as well and workup was negative back then. Abdominal u/s to look for any cause of this as orthopedic exam has been unremarkable

Abnormal PE/Chem/CBC/UA Results: Normal exam and orthopedic exam Normal spinal rads  
CBC/Chem/UA in 7/25 nsf

## ULTRASONOGRAPHIC EXAMINATION OF THE ABDOMEN

### Urinary System

The urinary bladder is moderately distended with anechoic urine. The Bladder wall largely appears of normal thickness with a smooth mucosal surface. In the dependent portion of the urinary bladder there are numerous pinpoint hyperechoic foci and some larger focal shadowing structures most consistent with small stones (measuring 0.51 cm and 0.44 cm). Additionally, there is sandy mineralized debris that appears to be extending into the region of the pre-prostatic urethra.

The prostate is normal in size (1.02 cm) and shape for this neutered male dog. The parenchyma is homogenous and the external margins are smooth. The prostatic urethra appears normal with no evidence of irregularity, invasion, mass effect or calculi.

The left kidney has a normal shape and size (6.63 cm). Overall echogenicity is normal with adequate corticomedullary distinction and a typical 1:3 cortex:medulla ratio. There is no evidence of focal perinephric inflammation or effusion. There is no evidence of pyelectasia, nephroliths, infarcts or hydroureter. Renal vasculature is normal.

The right kidney has a normal shape and size (6.21 cm). Overall echogenicity is normal with adequate corticomedullary distinction and a typical 1:3 cortex:medulla ratio. There is no evidence of focal perinephric inflammation or effusion. There is no evidence of pyelectasia, nephroliths, infarcts or hydroureter. Renal vasculature is normal.

### Adrenal Glands

The left adrenal gland is normal in size measuring 0.52 cm at the cranial pole and 0.61 cm at the caudal pole. It is observed in its normal position cranial to the left renal artery. It is normal in appearance (uniformly hypoechoic) and shape with no evidence of a mass effect.

The right adrenal gland is not clearly visualized/obscured by gas artifact in the right cranial abdomen.

### Spleen

The spleen is subjectively normal in size (1.92 cm), echotexture is homogenous, and the splenic capsule is smooth with no irregularities. The blood flow through the hilus and splenic parenchyma appears normal. No focal parenchymal abnormalities are visualized.



## PATIENT

Pongo Church

## SPECIES

Canine

## BREED

Dalmatian

## SEX

Neutered Male

## AGE

7 Years

## WEIGHT

31.4 kg

## INTERPRETED BY

Kathleen Sennello DVM,  
MS, Diplomate ACVIM  
(Small Animal Internal  
Medicine)

## IMAGING PERFORMED BY

Dr. Iacovides

## HOSPITAL NAME

Oakbank Animal  
Hospital

## REFERRING VET

Dr. Youngs

## INVOICE

72267

## DATE

1/15/26

## Liver

The liver is subjectively normal in size, and echogenicity with smooth peripheral margins. The parenchyma is homogenous echotexture. The visible portions of the vasculature and biliary tract appear normal. No focal nodules or cystic lesions are observed.

The gall bladder lumen is moderately distended. The wall of the gall bladder is not thickened and has a smooth mucosal surface. Luminal contents are mild and likely incidental at this time. The cystic and common bile ducts are normal/not visible.

## Gastrointestinal

The stomach contains moderate gas and ingesta. It measures at a normal thickness of <0.7cm with some variability due to the presence of rugal folds. The distinction of the gastric wall layers is adequate and there is no impression of reduced peristaltic activity. Gas artifact obscures full evaluation of the stomach and a significant portion of the right cranial abdomen.

Most of the visualized areas of duodenum, jejunum and ileum have a relatively uniform diameter with minimal to mild fluid and gas. Wall thickness is normal. Bowel loops follow a curvilinear path with distinct wall layering maintaining the typical 1:3 muscularis:mucosa layer ratio. Jejunum wall measures 0.35 cm. Duodenum wall measures 0.30 cm. Visualized peristalsis appears appropriate. Some sections of small intestine appear mildly to moderately fluid and gas distended. No focal lesions are observed.

Sections of colon are visualized with non-formed fecal material and gas shadowing distally. There is no observed focal or generalized colon wall thickening or loss of layering.

## Pancreas

The area of the pancreas is normal and isoechoic to surrounding mesentery. There is no evidence of nodules or cystic lesions. There is no evidence of regional mesenteric inflammation or fluid. \*The right limb of the pancreas was not clearly visualized due to gas interference in the cranial abdomen.

## Free Abdomen

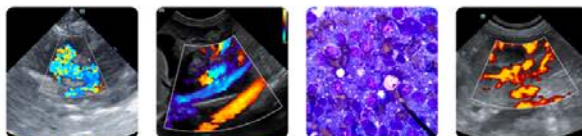
Evaluation of the peritoneal cavity did not reveal any evidence of effusion, or subjective lymphadenomegaly. The Medial iliac nodes appear normal and there was no evidence of a caudal aortic thrombus at the bifurcation. The omentum is of normal uniform echogenicity.

## ULTRASONOGRAPHIC FINDINGS

- Dependent mineralized sandy debris and small stones visualized in the urinary bladder and proximal urethra – Recommend urinalysis and culture +/- radiographs.
- Mild to moderate fluid and gas distended stomach and some sections of small intestine – Findings could be consistent with a stressed/panting patient, ileus, less likely a partially obstructive process. Enteritis is thought most likely.

## INTERPRETATION OF THE FINDINGS & FURTHER RECOMMENDATIONS

No definitive cause for abdominal pain is visualized on today's exam. Unfortunately, there is a significant amount of gas interference in the right cranial abdomen that interferes with full evaluation of the proximal duodenum, right pancreas, right adrenal, etc. This could be secondary to anxiety/panting, a non-fasted patient, or less likely a partial obstruction or similar in this region. Correlate with abdominal radiographs. If symptoms are persistent, consider sedation in hopes that reevaluation would allow for



## PATIENT

Pongo Church

## SPECIES

Canine

## BREED

Dalmatian

## SEX

Neutered Male

## AGE

7 Years

## WEIGHT

31.4 kg

## INTERPRETED BY

Kathleen Sennello DVM,  
MS, Diplomate ACVIM  
(Small Animal Internal  
Medicine)

## IMAGING PERFORMED BY

Dr. Iacovides

## HOSPITAL NAME

Oakbank Animal  
Hospital

## REFERRING VET

Dr. Youngs

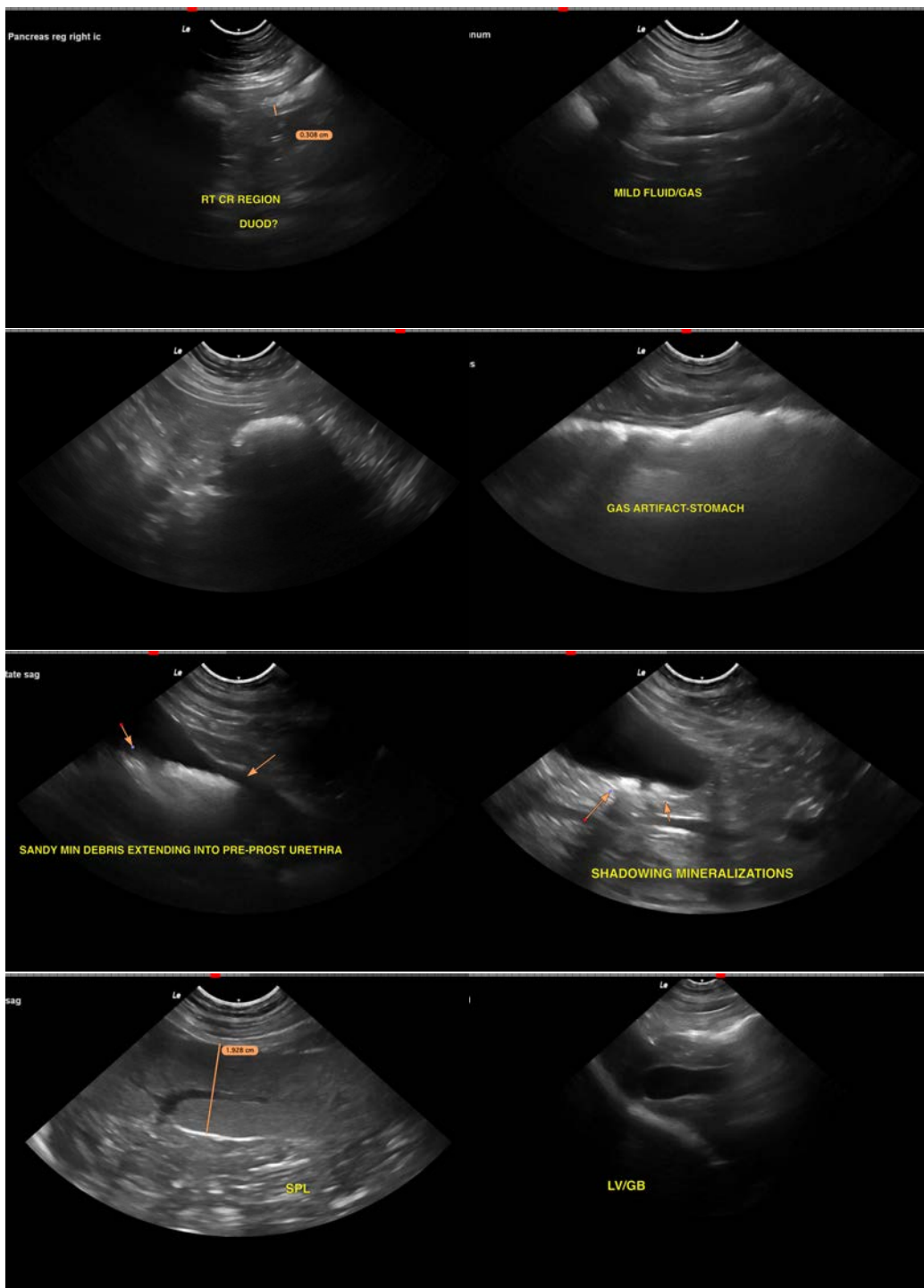
## INVOICE

72267

## DATE

1/15/26

better visualization of these structures. Alternately, if musculoskeletal disease is still a concern (particularly back pain, etc.), a contrast CT scan could be considered to evaluate the abdomen and thoracolumbar and lumbar spine.





## PATIENT

Pongo Church

## SPECIES

Canine

## BREED

Dalmatian

## SEX

Neutered Male

## AGE

7 Years

## WEIGHT

31.4 kg

## INTERPRETED BY

Kathleen Sennello DVM,  
MS, Diplomate ACVIM  
(Small Animal Internal  
Medicine)

## IMAGING PERFORMED BY

Dr. Iacovides

## HOSPITAL NAME

Oakbank Animal  
Hospital

## REFERRING VET

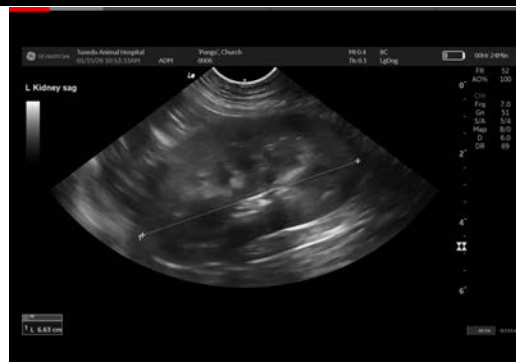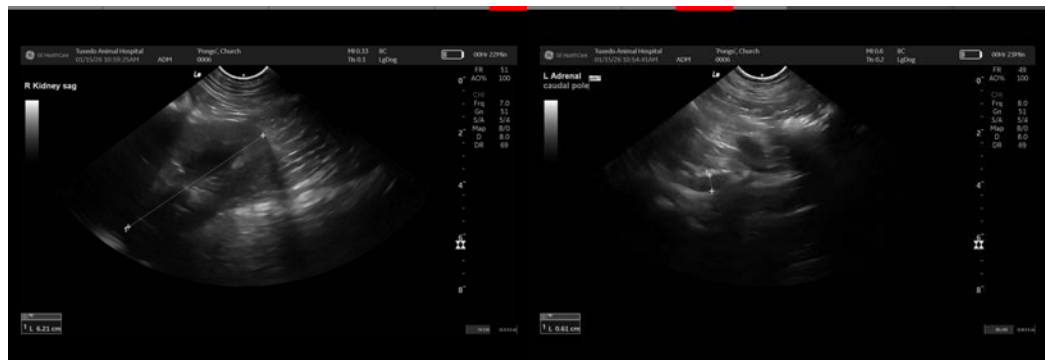
Dr. Youngs

## INVOICE

72267

## DATE

1/15/26



The information and recommendations provided are based on the images presented by the referring veterinarian/sonographer. No evaluation can be communicated regarding pathology that was not visible in the image/video clips provided.

Thank you for this referral. If the clinical or image interpretation does not parallel your findings or if I can be of any further assistance please contact me.

Kathleen Sennello DVM,MS, Diplomate ACVIM (Small animal Internal Medicine)

info@sonopath.com