



**PATIENT PRESENTING CLINICAL SIGNS**

Leo Nathani Vomiting bile, not food since early December. Wt. loss. No current meds.  
Abnormal PE/Chem/CBC/UA Results: Slight anemia, SDMA 16 (H14), ALB 2.6(L2.7), USG 1.039

**SPECIES ULTRASONOGRAPHIC EXAMINATION OF THE ABDOMEN**

Canine

**Urinary System**

**BREED**

The urinary bladder is minimally distended with anechoic urine. The Bladder wall appears somewhat thickened and irregular, measuring 0.3 cm. The area of the trigone, proximal urethra (to a depth of 2cm) and ureteral papillae appear free from mass lesions or calculi. Findings are most consistent with diffuse cystitis or lack of urine distention.

Maltese

**SEX**

The prostate appears somewhat large (1.57 cm) and hypoechoic. It has a fairly regular wall and smooth external margins. The parenchyma appears somewhat heterogeneous, but no discreet focal lesions are present.

Neutered Male

**AGE**

The left kidney has a normal shape and size (3.67 cm). Overall echogenicity is slightly hyperechoic with poor corticomedullary distinction and a typical 1:3 cortex:medulla ratio. There is no evidence of perinephric inflammation or effusion. There is no evidence of pyelectasia, nephroliths, infarcts or hydroureter. Renal vasculature is normal.

15 Years

**WEIGHT**

The right kidney has a normal shape and size (3.88 cm). Overall echogenicity is slightly hyperechoic with poor corticomedullary distinction and a typical 1:3 cortex:medulla ratio. There is no evidence of perinephric inflammation or effusion. There is no evidence of pyelectasia, nephroliths, infarcts or hydroureter. Renal vasculature is normal.

Not Given

**INTERPRETED BY**

**Adrenal Glands**

Kathleen Sennello DVM,  
MS, Diplomate ACVIM  
(Small Animal Internal  
Medicine)

The left adrenal gland is normal in size measuring 0.53 cm at the caudal pole. It is observed in its normal position cranial to the left renal artery. It is normal in appearance (uniformly hypoechoic) and shape with no evidence of a mass effect.

**IMAGING PERFORMED BY**

The right adrenal gland is normal in size measuring 0.49 cm at the caudal pole. It is observed in its normal position between the cranial aspect of the right kidney and the caudal vena cava. It is normal in appearance (uniformly hypoechoic) and shape with no evidence of a mass effect.

Shari Reffi, CVT

**Spleen**

**HOSPITAL NAME**

The spleen is subjectively normal in size, echotexture is homogenous, and the splenic capsule is smooth with no irregularities. The blood flow through the hilus and splenic parenchyma appears normal. No focal parenchymal abnormalities are visualized.

Parsippany Troy Hills

**REFERRING VET**

**Liver**

Dr. Dulude

The liver is subjectively normal in size, and echogenicity with smooth peripheral margins. The parenchyma is slightly heterogenous in echotexture with subtle, indistinct focal mottling. The visible portions of the vasculature and biliary tract appear normal. There is a hyperechoic cystic mass effect towards the middle of the liver measuring 2.71 cm x 2.2 cm.

**INVOICE**

34253

The gall bladder lumen is moderately distended. The wall of the gall bladder has irregular polypoid projections and there is a moderate amount of non-organized echogenic debris. The cystic and common bile ducts are normal/not visible.

**DATE**

1/14/22



## PATIENT

Leo Nathani

## SPECIES

Canine

## BREED

Maltese

## SEX

Neutered Male

## AGE

15 Years

## WEIGHT

Not Given

## INTERPRETED BY

Kathleen Sennello DVM,  
MS, Diplomate ACVIM  
(Small Animal Internal  
Medicine)

## IMAGING PERFORMED BY

Shari Reffi, CVT

## HOSPITAL NAME

Parsippany Troy Hills

## REFERRING VET

Dr. Dulude

## INVOICE

34253

## DATE

1/14/22

## Gastrointestinal

The stomach is moderately dilated with fluid. Additionally, there is hard shadowing, irregular solid foreign material within the gastric lumen measuring 2.88 cm x 1.14 cm, consistent with a foreign object such as a rock or something with right angles. The stomach measures at a normal thickness of <0.7cm with some variability due to the presence of rugal folds. The distinction of the gastric wall layers is adequate and there is no impression of reduced peristaltic activity. I suspect the foreign material in the gastric lumen is not causing a complete obstruction.

The visualized areas of duodenum, jejunum and ileum have a uniform diameter with moderate fluid distension. Wall appears subjectively, mildly increased. Bowel loops follow a typical curvilinear path with distinct wall layering. Duodenum wall measured 0.35 cm. Jejunum wall measured 0.22 cm. Visualized peristalsis appears appropriate. There were no focal lesions consistent with obstruction or a mass effect observed.

The ileocecal junction was visualized and exhibited normal intact wall layering and is subjectively of normal thickness. Sections of colon are visualized with formed fecal material and gas shadowing distally. There is no observed focal or generalized colon wall thickening or loss of layering.

## Pancreas

The pancreas is normal and isoechoic to surrounding mesentery. There is no evidence of nodules or cystic lesions. There is no evidence of regional mesenteric inflammation or fluid.

## Free Abdomen

Evaluation of the peritoneal cavity did not reveal any evidence of effusion, or subjective lymphadenomegaly. The Medial iliac nodes appear normal and there was no evidence of a caudal aortic thrombus at the bifurcation. The omentum is of normal uniform echogenicity.

## PRIMARY FINDINGS

- Mildly fluid dilated stomach with intraluminal shadowing foreign material – most consistent with a gastric foreign body. Recommend correlating with abdominal radiographs.
- Hyperechoic cystic hepatic mass – This lesion could represent a benign or malignant process. The hyperechoic cystic appearance favors a more benign process. Consider a fine needle aspirate.
- Mildly thickened small intestine with mild diffuse fluid dilation.
- Prominent/large prostate – Correlate with age at neutering. If patient was neutered before puberty, this could be an abnormal prostate. Correlate with rectal exam findings. If the prostate is in fact large despite early neutering, consider a fine needle aspirate of the prostate, as prostatic carcinoma would be a concern.

## SECONDARY FINDINGS

- Decreased corticomedullary distinction in both kidneys – The bilateral renal findings are consistent with age-related change.
- Thickened, irregular urinary bladder wall – The bladder mucosal changes could be consistent with cystitis or artifactual due to lack of adequate luminal distension. Bladder neoplasia cannot be ruled out but is considered unlikely in this patient.



**PATIENT**

Leo Nathani

- Hypoechoic, prominent pancreas – The pancreatic changes are most consistent with age-related parenchymal remodeling, potentially secondary to a prior inflammatory episode, early fibrosis or chronic pancreatitis.

**SPECIES**

Canine

**INTERPRETATION OF THE FINDINGS & FURTHER RECOMMENDATIONS**

There is clearly shadowing discreet foreign material within the gastric lumen. I would suspect this would show up on radiographs. Correlate with clinical history. If this could be a source of the vomiting, then consider gastrotomy.

**BREED**

Maltese

Additionally, there is a liver mass present. This is a mid parenchymal mass, so options would be a fine needle aspirate or CT scan for surgical planning. Alternately, this mass could continue to be monitored in hopes that it is a benign/slow-growing lesion.

**SEX**

Neutered Male

The changes with the urogenital system are unexpected. Recommend a urinalysis and culture to look for evidence of infection, inflammation, etc., and consider reevaluation of the urinary bladder when it is more distended. If this pet was neutered early in life, the prostate may be large, and you could consider a fine needle aspirate. Correlate the prostatic findings with rectal exam.

**AGE**

15 Years

If this pet has had chronic GI signs, then evaluation of the distal bowel at the time of gastrotomy would be recommended with the possibility of obtaining small intestinal biopsies.

Recommend 3-view thoracic radiographs.

**WEIGHT**

Not Given

**INTERPRETED BY**

Kathleen Sennello DVM,  
MS, Diplomate ACVIM  
(Small Animal Internal  
Medicine)

**IMAGING PERFORMED BY**

Shari Reffi, CVT

**HOSPITAL NAME**

Parsippany Troy Hills

**REFERRING VET**

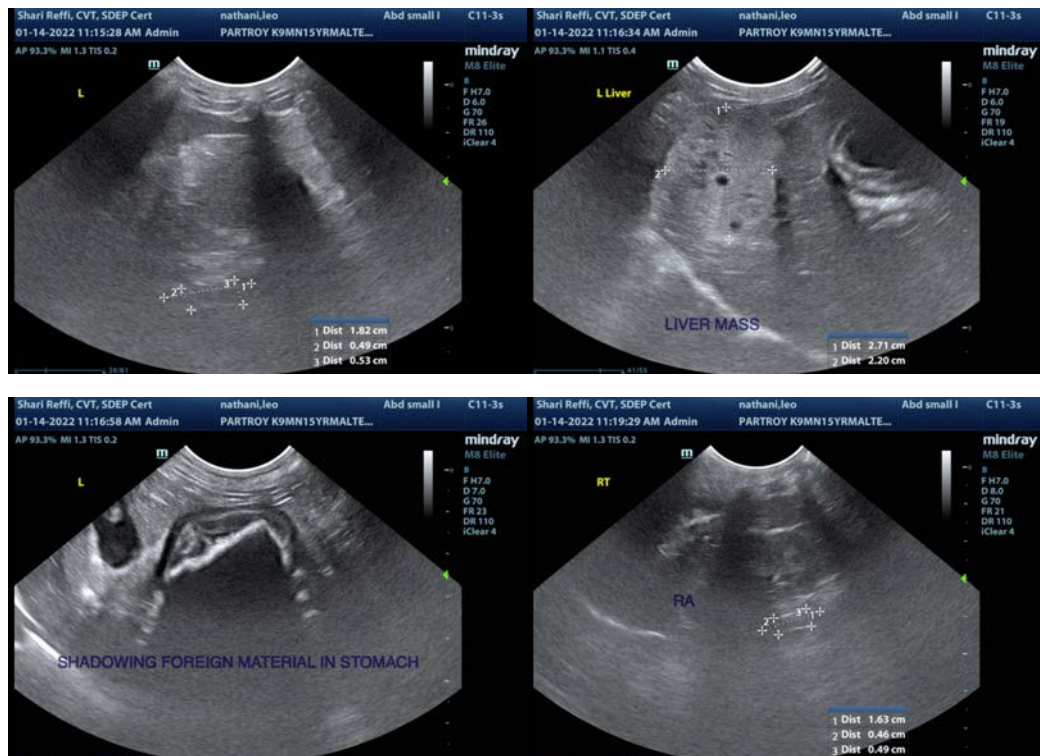
Dr. Dulude

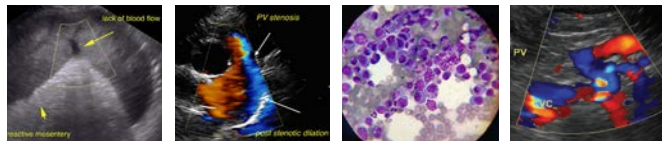
**INVOICE**

34253

**DATE**

1/14/22





**PATIENT**

Leo Nathani

**SPECIES**

Canine

**BREED**

Maltese

**SEX**

Neutered Male

**AGE**

15 Years

**WEIGHT**

Not Given

**INTERPRETED BY**

Kathleen Sennello DVM,  
MS, Diplomate ACVIM  
(Small Animal Internal  
Medicine)

**IMAGING  
PERFORMED BY**

Shari Reffi, CVT

**HOSPITAL NAME**

Parsippany Troy Hills

**REFERRING VET**

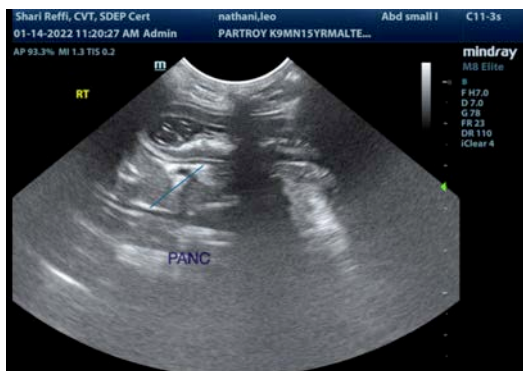
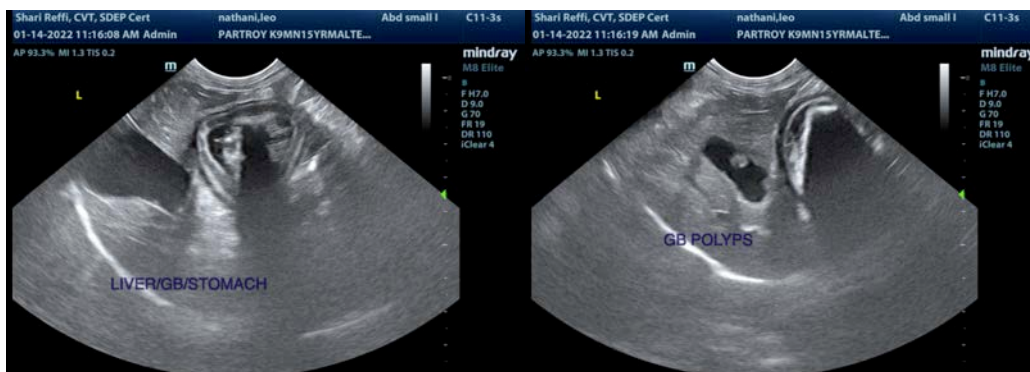
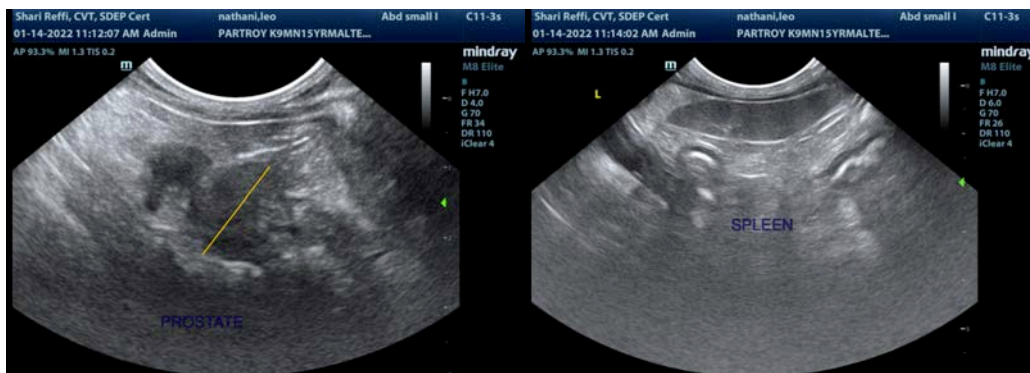
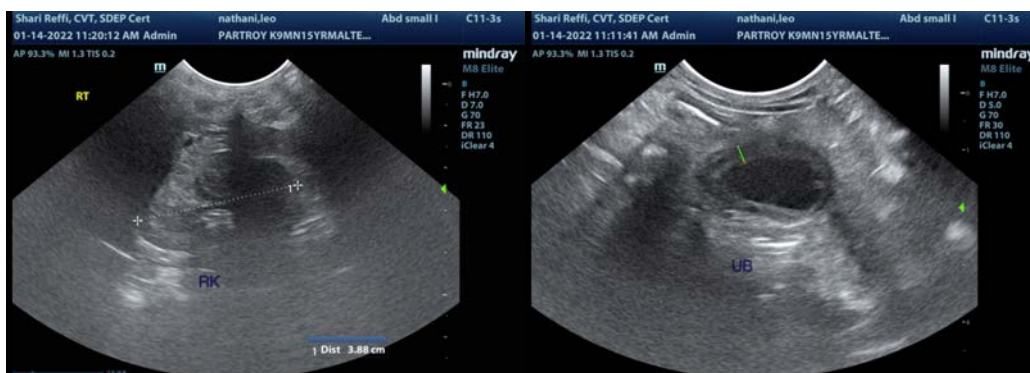
Dr. Dulude

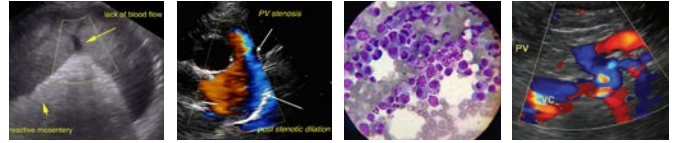
**INVOICE**

34253

**DATE**

1/14/22





**PATIENT**

Leo Nathani

The information and recommendations provided are based on the images presented by the referring veterinarian. No evaluation can be communicated regarding pathology that was not visible in the image/video clips provided.

**SPECIES**

Canine

Thank you for this referral. If the clinical or image interpretation does not parallel your findings or if I can be of any further assistance please contact me.

**BREED**

Maltese

Kathleen Sennello DVM,MS, Diplomate ACVIM (Small animal Internal Medicine)  
kathleen.sennello@sonopath.com

**SEX**

Neutered Male

**AGE**

15 Years

**WEIGHT**

Not Given

**INTERPRETED BY**

Kathleen Sennello DVM,  
MS, Diplomate ACVIM  
(Small Animal Internal  
Medicine)

**IMAGING  
PERFORMED BY**

Shari Reffi, CVT

**HOSPITAL NAME**

Parsippany Troy Hills

**REFERRING VET**

Dr. Dulude

**INVOICE**

34253

**DATE**

1/14/22