



**PATIENT**

Abby Savinovich

**SPECIES**

Canine

**BREED**

Mixed

**SEX**

Spayed Female

**AGE**

9 Years

**WEIGHT**

N/A

**INTERPRETED BY**

Kathleen Sennello DVM,  
MS, Diplomate ACVIM  
(Small Animal Internal  
Medicine)

**IMAGING  
PERFORMED BY**

Kelly Vazquez

**HOSPITAL NAME**

The Venturing Vet

**REFERRING VET**

Dr. Marisa Herzog

**INVOICE**

34253

**DATE**

1/14/22

**PRESENTING CLINICAL SIGNS**

Patient with previous history of liver failure approx. 1 year ago, presents for elevated liver values. Was on Denamarin, but drug has been difficult to obtain as of late.  
Abnormal PE/Chem/CBC/UA Results: 4/17/21: ALT 129 . 11/11/21: ALT 267, Alk. Phos. 138.

**ULTRASONOGRAPHIC EXAMINATION OF THE ABDOMEN**

**Urinary System**

The urinary bladder is moderately distended with anechoic urine. The Bladder wall, trigone, ureteral papillae and visible urethra (to a depth of 2cm) appear normal with no evidence of wall thickening, mucosal irregularities, masses or cystic calculi.

The left kidney has a normal shape and size (7.51 cm). Overall echogenicity is normal with adequate corticomedullary distinction and a typical 1:3 cortex:medulla ratio. There is no evidence of perinephric inflammation or effusion. There is no evidence of pyelectasia, nephroliths, infarcts or hydroureter. Renal vasculature is normal.

The right kidney has a normal shape and size (6.73 cm). Overall echogenicity is normal with adequate corticomedullary distinction and a typical 1:3 cortex:medulla ratio. There is no evidence of perinephric inflammation or effusion. There is no evidence of pyelectasia, nephroliths, infarcts or hydroureter. Renal vasculature is normal.

**Adrenal Glands**

The left adrenal gland is normal in size measuring 0.64 cm at the caudal pole. It is observed in its normal position cranial to the left renal artery. It is normal in appearance (uniformly hypoechoic) and shape with no evidence of a mass effect.

The right adrenal gland is normal in size measuring 0.68 cm at the caudal pole. It is observed in its normal position between the cranial aspect of the right kidney and the caudal vena cava. It is normal in appearance (uniformly hypoechoic) and shape with no evidence of a mass effect.

**Spleen**

The spleen is subjectively normal in size, echotexture is homogenous, and the splenic capsule is smooth with no irregularities. The blood flow through the hilus and splenic parenchyma appears normal. No focal parenchymal abnormalities are visualized.

**Liver**

The liver is normal to slightly small in size, and echogenicity with smooth peripheral margins. The parenchyma is heterogenous in echotexture with subtle, indistinct focal mottling. The visible portions of the vasculature and biliary tract appear normal. There is a 1.2 cm discreet hyperechoic nodule visualized in the parenchyma.

The gallbladder lumen is moderately distended. The wall of the gall bladder is not thickened and has a smooth mucosal surface. Luminal contents are primarily anechoic. The cystic and common bile ducts are normal/not visible.

**Gastrointestinal**

The stomach contains minimal luminal contents. It measures at a normal thickness of <0.7cm with some variability due to the presence of rugal folds. The distinction of the gastric wall layers is adequate and there is no impression of reduced peristaltic activity. No masses or focal lesions were observed.



## PATIENT

Abby Savinovich

## SPECIES

Canine

## BREED

Mixed

## SEX

Spayed Female

## AGE

9 Years

## WEIGHT

N/A

## INTERPRETED BY

Kathleen Sennello DVM,  
MS, Diplomate ACVIM  
(Small Animal Internal  
Medicine)

## IMAGING PERFORMED BY

Kelly Vazquez

## HOSPITAL NAME

The Venturing Vet

## REFERRING VET

Dr. Marisa Herzog

## INVOICE

34253

## DATE

1/14/22

The visualized areas of duodenum, jejunum and ileum have a relatively uniform diameter with minimal fluid distension. Wall thickness is normal. Bowel loops follow a curvilinear path with distinct wall layering maintaining the typical 1:3 muscularis:mucosa layer ratio. The duodenum measured as normal (between 0.3-0.5cm in wall thickness) and the jejunum measured as normal (between 0.2-0.47cm.) Visualized peristalsis appears appropriate. There were no focal lesions consistent with obstruction or a mass effect observed.

The ileocecal junction was visualized and exhibited normal intact wall layering and is subjectively of normal thickness. Sections of colon are visualized with formed fecal material and gas shadowing distally. There is no observed focal or generalized colon wall thickening or loss of layering.

### Pancreas

The pancreas is normal and isoechoic to surrounding mesentery. There is no evidence of nodules or cystic lesions. There is no evidence of regional mesenteric inflammation or fluid.

### Free Abdomen

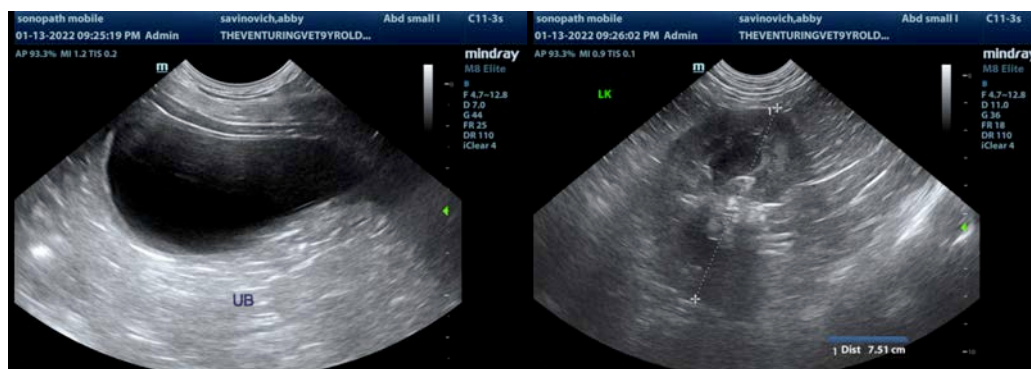
Evaluation of the peritoneal cavity did not reveal any evidence of effusion, or subjective lymphadenomegaly. The Medial iliac nodes appear normal and there was no evidence of a caudal aortic thrombus at the bifurcation. The omentum is of normal uniform echogenicity.

## ULTRASONOGRAPHIC FINDINGS

- Subjectively heterogeneous liver with a hyperechoic nodule – The diffuse hepatic changes are non-specific and could be consistent with vacuolar hepatopathy, nodular hyperplasia, inflammatory/immune-mediated disease, fibrosis, extramedullary hematopoiesis, toxic hepatopathy (e.g., copper), infiltrative neoplasia (less likely) or other hepatopathy. The appearance of the small focal hyperechoic nodule favors a benign process, but neoplastic change cannot be ruled out as a possibility.

## INTERPRETATION OF THE FINDINGS & FURTHER RECOMMENDATIONS

There are no large focal lesions associated with the liver, but unfortunately you can have significant liver disease/dysfunction and relatively mild ultrasonographic changes. Correlate these findings with the clinical history, as sometimes liver enzymes will normalize with end stage liver failure. Ideally, I would correlate these liver values with a liver function test to determine the significance of the elevation. If liver function is abnormal, a liver biopsy would likely be the most helpful step in trying to figure out if you're dealing with chronic issues from previous injury, new issues, etc. Additionally, you could consider testing for Leptospirosis, and Ursodiol can sometimes have some hepatoprotective properties.





**PATIENT**

Abby Savinovich

**SPECIES**

Canine

**BREED**

Mixed

**SEX**

Spayed Female

**AGE**

9 Years

**WEIGHT**

N/A

**INTERPRETED BY**

Kathleen Sennello DVM,  
MS, Diplomate ACVIM  
(Small Animal Internal  
Medicine)

**IMAGING  
PERFORMED BY**

Kelly Vazquez

**HOSPITAL NAME**

The Venturing Vet

**REFERRING VET**

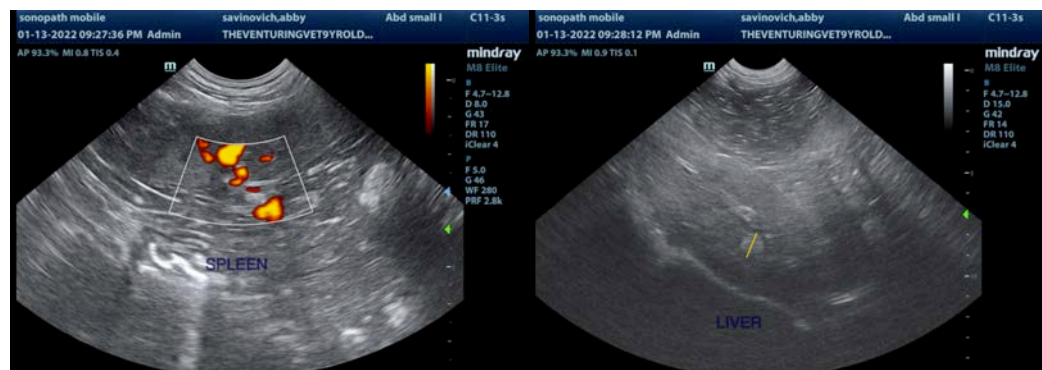
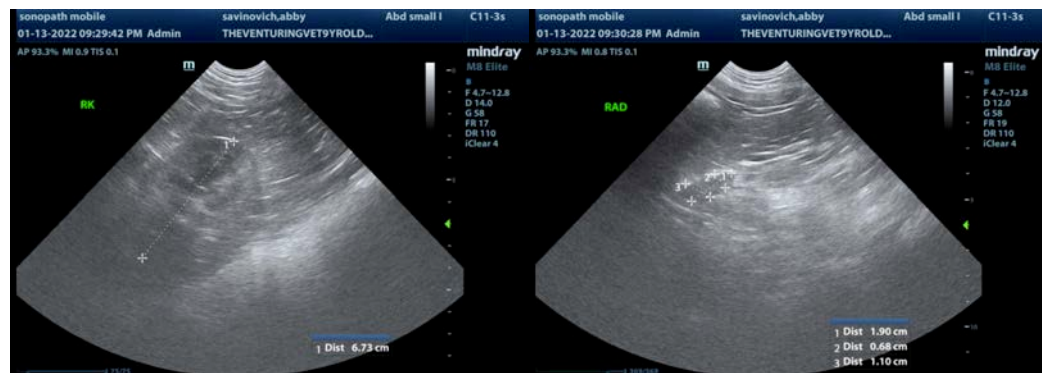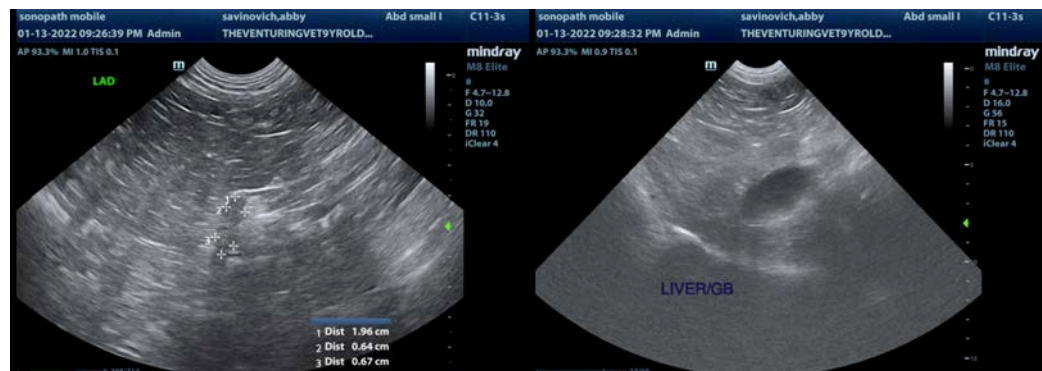
Dr. Marisa Herzog

**INVOICE**

34253

**DATE**

1/14/22



The information and recommendations provided are based on the images presented by the referring veterinarian. No evaluation can be communicated regarding pathology that was not visible in the image/video clips provided.

Thank you for this referral. If the clinical or image interpretation does not parallel your findings or if I can be of any further assistance please contact me.

Kathleen Sennello DVM,MS, Diplomate ACVIM (Small animal Internal Medicine)  
kathleen.sennello@sonopath.com