

**DATE PRESENTING CLINICAL SIGNS**

1/13/23

PATIENT

Eli McConagha

SPECIES

Canine

BREED

Poodle

SEX

Neutered Male

AGE

6/15/2009

WEIGHT

51.4 Pounds

INTERPRETED BYKathleen Sennello DVM,
MS, Diplomate ACVIM
(Small Animal Internal
Medicine)**HOSPITAL NAME**

Chadwell AH

REFERRING VET

Dr. Malick

INVOICE

20558

Presented for lethargy, lameness, diarrhea and vomiting of 1 days duration, decreased appetite. Pet depressed, strong mouth odor, new cardiac murmur Gr II/VI systolic, tense abdomen, lameness-left hind, but pet seemed generally uncomfortable. re-presented next day temperature 104.1

Current Medications: long term Gabapentin, Galliprant cerenia 24 mg 2 po q 24 hours. 1/10/2023 started cefpodoxime 200 mg q 24 hours, Baytril 136 q 24 hours, Flagyl 500 1/2 q 24 hours

Lab Results: wbc-35,900, 84% neutrophils, Hct 37.4%, globulin 5.6, Albumin 2.4, thyroid 0.4 (sick euthyroid?), BG was 33, however sat on clot. Glucometer BG the next day 81

Date of Previous IntraPet Ultrasound: No previous.

Sedation: Not required to complete full diagnostic ultrasound.

Stat Report: Declined at this time.

Imaging Performed By: Stephanie Warga RDCS, RVT.

ULTRASONOGRAPHIC EXAMINATION OF THE ABDOMEN**Urinary System**

The urinary bladder is moderately distended with anechoic urine. The bladder wall, trigone, ureteral papillae and visible urethra (to a depth of 2cm) appear normal with no evidence of wall thickening, mucosal irregularities, masses or cystic calculi.

The prostate is prominent in size (1.4 cm) and shape for this neutered male dog. The parenchyma is homogenous, and the external margins are smooth. The prostatic urethra appears normal with no evidence of irregularity, invasion, mass effect or calculi.

The left kidney has a normal shape and size (6.76 cm). Overall echogenicity is normal with adequate corticomedullary distinction and a typical 1:3 cortex:medulla ratio. There is no evidence of perinephric inflammation or effusion. There is no evidence of pyelectasia, nephroliths, infarcts or hydroureter. Renal vasculature is normal.

The right kidney has a normal shape and size (6.84 cm). Overall echogenicity is normal with adequate corticomedullary distinction and a typical 1:3 cortex:medulla ratio. There is no evidence of perinephric inflammation or effusion. There is no evidence of pyelectasia, nephroliths, infarcts or hydroureter. Renal vasculature is normal.

Adrenal Glands

The left adrenal gland is normal in size measuring 0.65 cm at the caudal pole. It is observed in its normal position cranial to the left renal artery. It is normal in appearance (uniformly hypoechoic) and shape with no evidence of a mass effect.

The right adrenal gland is normal in size measuring 0.6 cm at the caudal pole. It is observed in its normal position between the cranial aspect of the right kidney and the caudal vena cava. It is normal in appearance (uniformly hypoechoic) and shape with no evidence of a mass effect.

Spleen

The spleen is large and irregular in size, echotexture is homogenous, and the splenic capsule is smooth with no irregularities. The blood flow through the hilus and splenic parenchyma appears normal. There is a large hypoechoic somewhat mixed echogenicity cavitated mass effect arising from the spleen, measuring >5.69 cm x 7.41 cm.

Liver

The liver is subjectively normal in size, and echogenicity with smooth peripheral margins. The parenchyma is homogenous echotexture. The visible portions of the vasculature and biliary tract appear normal. No focal nodules or cystic lesions are observed.

The gall bladder lumen is moderately distended. The wall of the gall bladder is not thickened and has a smooth mucosal surface. Luminal contents are primarily anechoic. The cystic and common bile ducts are normal/not visible.

Gastrointestinal

The stomach contains minimal luminal contents. It measures at a normal thickness of <0.7cm with some variability due to the presence of rugal folds. The distinction of the gastric wall layers is adequate and there is no impression of reduced peristaltic activity. No masses or focal lesions were observed.

The visualized areas of duodenum, jejunum and ileum have a relatively uniform diameter with minimal fluid distension. Wall thickness is normal. Bowel loops follow a curvilinear path with distinct wall layering maintaining the typical 1:3 muscularis:mucosa layer ratio. The duodenum measured as normal (between 0.3-0.5 cm in wall thickness) and the jejunum measured as normal (0.23 cm) Visualized peristalsis appears appropriate. There were no focal lesions consistent with obstruction or a mass effect observed.

The ileocecal junction was visualized and exhibited normal intact wall layering and is subjectively of normal thickness. Sections of colon are visualized with formed fecal material and gas shadowing distally. There is no observed focal or generalized colon wall thickening or loss of layering.

Pancreas

The pancreas is normal and isoechoic to surrounding mesentery. There is no evidence of nodules or cystic lesions. There is no evidence of regional mesenteric inflammation or fluid.

Free Abdomen

Evaluation of the peritoneal cavity did not reveal any evidence of effusion, or subjective lymphadenomegaly. The Medial iliac nodes appear normal and there was no evidence of a caudal aortic thrombus at the bifurcation. The omentum is of normal uniform echogenicity.

Other

A brief view of the heart was submitted. No pericardial effusion was seen.

ULTRASONOGRAPHIC FINDINGS

Primary Findings

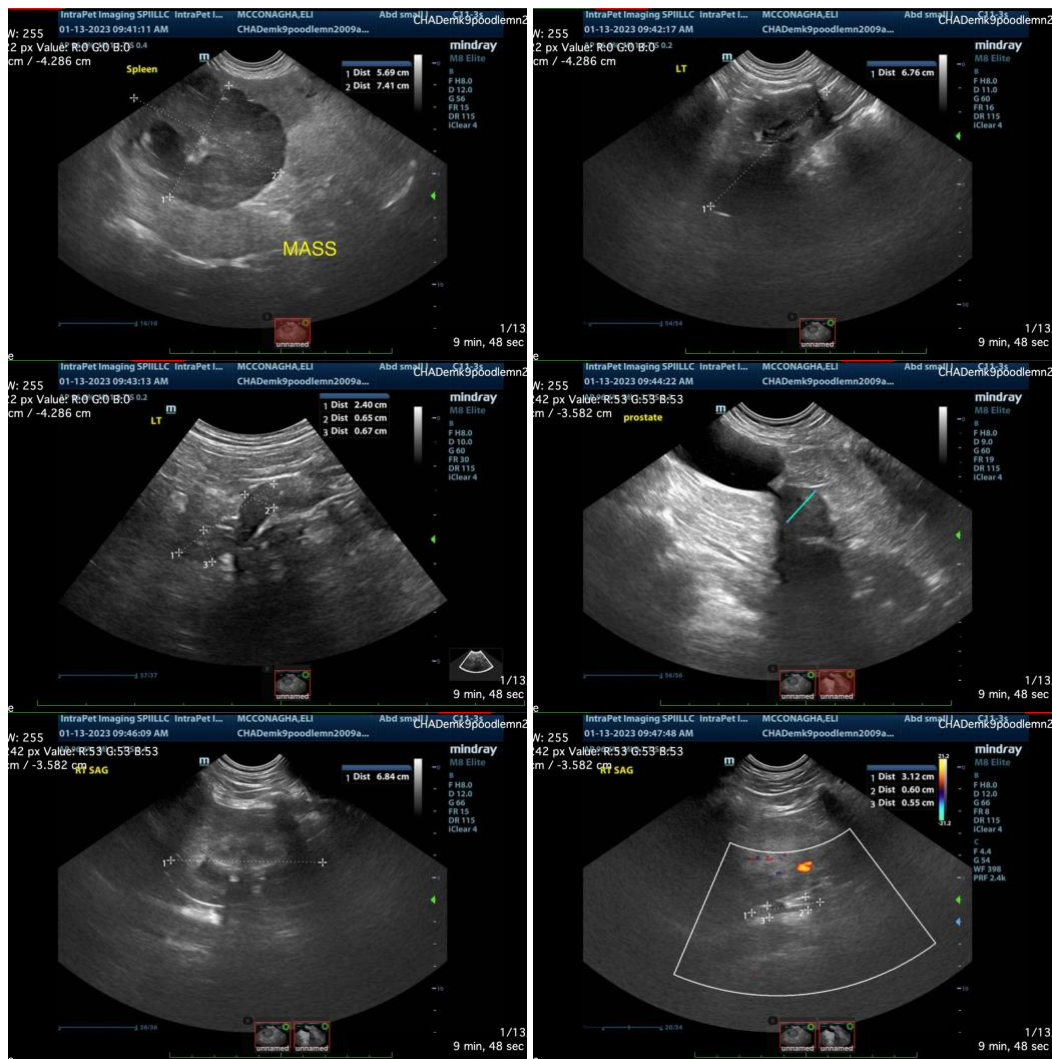
- Large mixed echogenicity, irregular, heterogenous and cavitated splenic mass. A large, heterogenous mass with cavitations is present within the splenic parenchyma. The mass distorts the splenic capsule. Differentials for the mass include neoplasia (e.g., hemangiosarcoma, hemangioma), hematoma, abscess, other. A neoplastic process is favored.

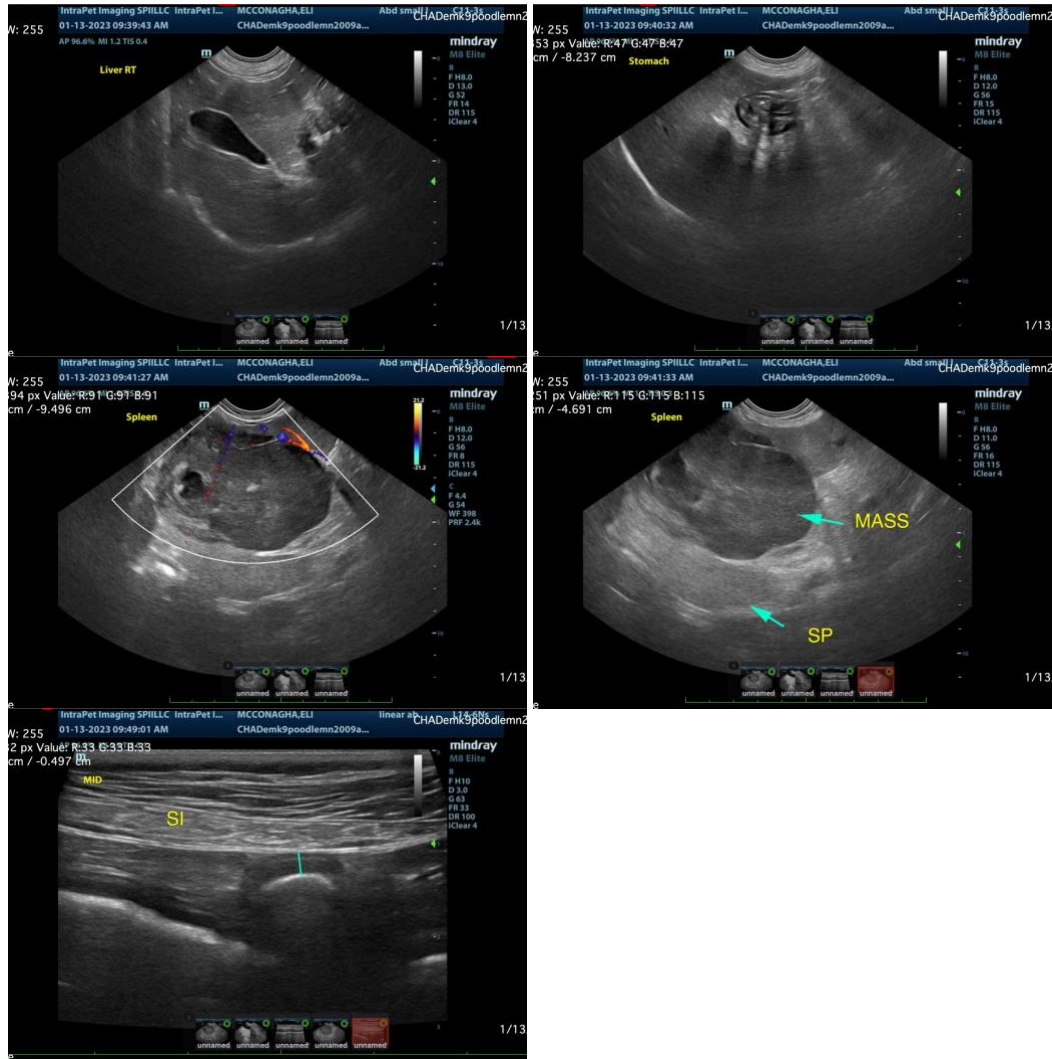
Secondary Findings

- Prominent prostate. If this patient was neutered after puberty, this is likely within normal limits. If he was neutered prior to puberty, this could be abnormal and a fine needle aspirate could be considered.

INTERPRETATION OF THE FINDINGS & FURTHER RECOMMENDATIONS

There is a large mixed echogenicity cavitated splenic mass present. I recommend a splenectomy for both diagnostic and therapeutic purposes. It is not 100% clear if the current symptoms are due to this mass effect or if there is a concurrent issue, but these symptoms could be attributable to the splenic mass. No evidence of overt metastasis is observed. Consider three view thoracic radiographs to rule out concurrent thoracic disease/involvement.





The information and recommendations provided are based on the images presented by the referring veterinarian. No evaluation can be communicated regarding pathology that was not visible in the image/video clips provided.

Thank you for this referral. If the clinical or image interpretation does not parallel your findings or if I can be of any further assistance please contact me.

Kathleen Sennello DVM,MS, Diplomate ACVIM (Small animal Internal Medicine)
 kathleen.sennello@sonopath.com