

**DATE PRESENTING CLINICAL SIGNS**

1/13/23

History: Has been having issues with chronic vomiting and not acting himself. Now is lethargic and drinking more water. BW is not revealing.

**PATIENT**

Auggie Mulqueen

Current Medications: none listed.

Date of Previous IntraPet Ultrasound: No previous.

Sedation: IV Dex domitor.

**SPECIES**

Stat Report: Not requested.

Canine

Imaging Performed By: Rachel Brillhart, RDMS.

**BREED****ULTRASONOGRAPHIC EXAMINATION OF THE ABDOMEN**

Mixed Breed

**Urinary System**

The urinary bladder is moderately distended with anechoic urine. The bladder wall, trigone, ureteral papillae and visible urethra (to a depth of 2.0 cm) appear normal with no evidence of wall thickening, mucosal irregularities, masses. There is a small pile of a dependent shadowing hyperechoic debris, measuring approximately 1.44 cm, most consistent with a pile of sandy debris or a small stone.

**SEX**

Neutered Male

**AGE**

8/17/12

The prostate is normal in size (1.99 cm) and shape for this neutered male dog. The parenchyma is homogenous, and the external margins are smooth. The prostatic urethra appears normal with no evidence of irregularity, invasion, mass effect or calculi.

**WEIGHT**

49 Pounds

The left kidney has a normal shape and size (5.74 cm). Overall echogenicity is normal with adequate corticomedullary distinction and a typical 1:3 cortex:medulla ratio. There is no evidence of perinephric inflammation or effusion. There is no evidence of pyelectasia, nephroliths, infarcts or hydroureter. Renal vasculature is normal.

**INTERPRETED BY**

The right kidney has a normal shape and size (6.34 cm). Overall echogenicity is normal with adequate corticomedullary distinction and a typical 1:3 cortex:medulla ratio. There is no evidence of perinephric inflammation or effusion. There is no evidence of pyelectasia, nephroliths, infarcts or hydroureter. Renal vasculature is normal.

**Adrenal Glands**

The left adrenal gland is normal in size measuring 0.83 cm at the caudal pole. It is observed in its normal position cranial to the left renal artery. It is normal in appearance (uniformly hypoechoic) and shape with no evidence of a mass effect.

**HOSPITAL NAME**

Homeward Bound VS

The right adrenal gland is normal in size measuring 0.73 cm at the caudal pole. It is observed in its normal position between the cranial aspect of the right kidney and the caudal vena cava. It is normal in appearance (uniformly hypoechoic) and shape with no evidence of a mass effect.

**REFERRING VET**

Dr. Vance

**Spleen**

The spleen is normal in size and slightly irregular in shape. The blood flow through the hilus and splenic parenchyma appears normal. There is a hypoechoic nodule visualized in the periphery of the spleen, measuring 1.28 cm x 0.92 cm, which is deviating the splenic capsule.

**INVOICE**

20558

**Liver**

The liver is subjectively large in size, and echogenicity with smooth peripheral margins. The parenchyma is heterogenous in echotexture with subtle, indistinct focal mottling. The visible portions of the vasculature and biliary tract appear normal. No focal nodules or cystic lesions are observed

The gall bladder lumen is moderately distended. The wall of the gall bladder is not thickened and has a smooth mucosal surface. Luminal contents are primarily anechoic. The cystic and common bile ducts are normal/not visible.

### ***Gastrointestinal***

The stomach contains minimal luminal contents. It measures at a normal thickness of <0.7cm with some variability due to the presence of rugal folds. The distinction of the gastric wall layers is adequate and there is no impression of reduced peristaltic activity. No masses or focal lesions were observed.

The visualized areas of duodenum, jejunum and ileum have a relatively uniform diameter with minimal fluid distension. Wall thickness is normal. Bowel loops follow a curvilinear path with distinct wall layering maintaining the typical 1:3 muscularis:mucosa layer ratio. The duodenum measured as normal (between 0.57 cm in wall thickness) and the jejunum measured as normal (0.49 cm) Visualized peristalsis appears appropriate. There were no focal lesions consistent with obstruction or a mass effect observed.

The ileocecal junction was visualized and exhibited normal intact wall layering and is subjectively of normal thickness. Sections of colon are visualized with formed fecal material and gas shadowing distally. There is no observed focal or generalized colon wall thickening or loss of layering.

### ***Pancreas***

The pancreas is prominent and mottled compared to the surrounding isoechoic mesentery. There is no evidence of nodules or cystic lesions. There is no evidence of regional mesenteric inflammation or fluid.

### ***Free Abdomen***

Evaluation of the peritoneal cavity did not reveal any evidence of effusion, or subjective lymphadenomegaly. The Medial iliac nodes appear normal and there was no evidence of a caudal aortic thrombus at the bifurcation. The omentum is of normal uniform echogenicity.

## **ULTRASONOGRAPHIC FINDINGS**

- Hyperechoic shadowing debris in the dependent portion of the urinary bladder. This could represent a small stone or a pile of sandy debris. Correlate with abdominal radiographs urinalysis and culture.
- Hypoechoic nodule in the spleen, which bulges the splenic capsule. There is a non-cavitated, hypoechoic splenic nodule visualized. Differentials include lymphoid hyperplasia, extramedullary hematopoiesis, infiltrative neoplasia, inflammation, other. Cytology or histopathology would be necessary to get a definitive diagnosis. The deviation of the splenic capsule trends toward a more potentially aggressive lesion.
- Prominent mottled pancreas. The pancreatic changes are most consistent with mild pancreatitis or a recent episode of pancreatic inflammation.
- Large heterogenous liver. The diffuse hepatic changes are non-specific and could be consistent with vacuolar hepatopathy, nodular hyperplasia, inflammatory/immune-mediated disease, fibrosis, extramedullary hematopoiesis, toxic hepatopathy (e.g., copper), infiltrative neoplasia (less likely) or other hepatopathy.

## **INTERPRETATION OF THE FINDINGS & FURTHER RECOMMENDATIONS**

The changes observed on today's scan are relatively mild. No focal lesions are visualized to explain the vomiting reported. There is a small hyperechoic shadowing area in the dependent portion of the urinary bladder most consistent with a small stone or pile of sandy debris. Correlate these findings with abdominal radiographs and urinalysis and culture.

The hypoechoic nodule in the spleen is small but it does deviate the capsule somewhat. Consider a fine needle aspirate or close monitoring with ultrasound.

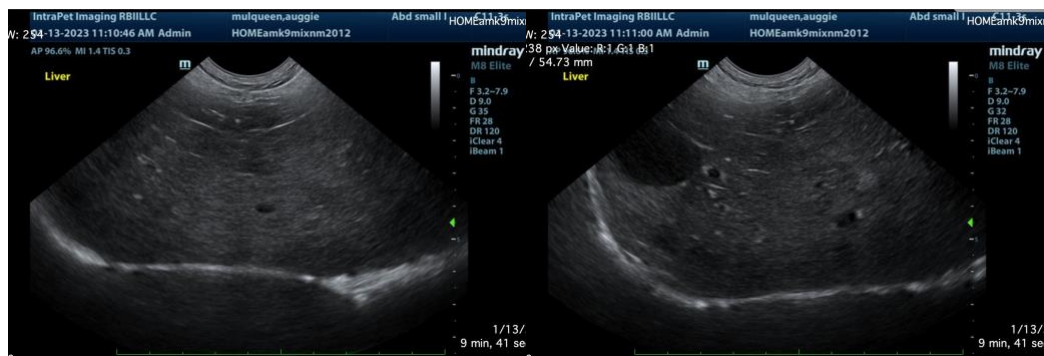
The pancreas is somewhat prominent and mottled. It does not appear overtly inflamed but these changes could be consistent with mild chronic pancreatitis or previous episodes of pancreatitis. Correlate with a quantitative cPLI level.

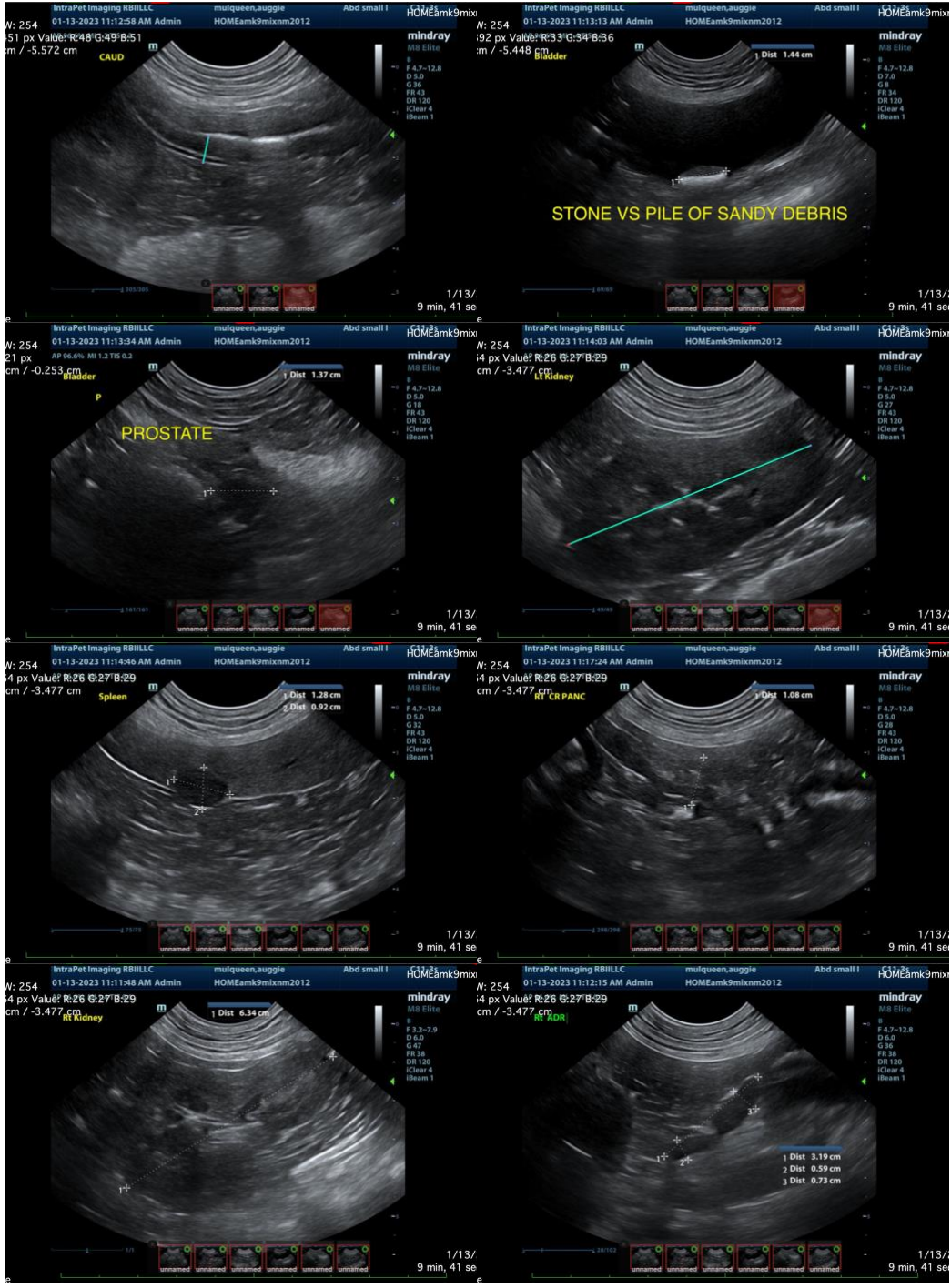
The significance of the heterogenous liver is uncertain. This is a nonspecific finding. Correlate with blood work results. If liver enzymes are elevated, you could consider further evaluation with a liver function test, fine needle aspirate, etc.

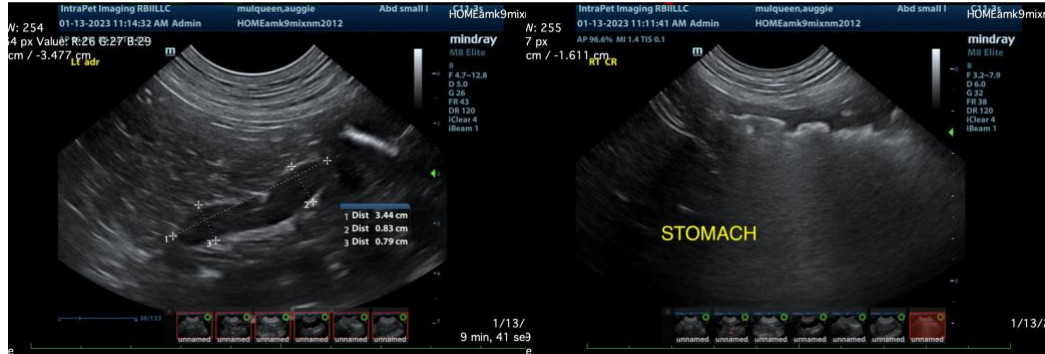
If no metabolic causes are identified for the vomiting reported, then consider the possibility of primary gastrointestinal disease, as this does not always result in significant ultrasonographic lesions.

Consider such differentials as food allergy/dietary intolerance, GI parasitism, chronic pancreatitis, IBD and less likely neoplasia, etc.

- Consider a novel protein/hydrolyzed protein diet (exclusively at least 4-6 weeks)
- Consider a GI panel to Texas A&M for evaluation of B12 levels, folate, PLI/TLI etc.. to further evaluate for pancreatic/small intestinal disease.
- Consider chronic probiotic therapy
- If chronic vomiting persists, consider obtaining GI biopsies







**The information and recommendations provided are based on the images presented by the referring veterinarian. No evaluation can be communicated regarding pathology that was not visible in the image/video clips provided.**

Thank you for this referral. If the clinical or image interpretation does not parallel your findings or if I can be of any further assistance please contact me.

Kathleen Sennello DVM,MS, Diplomate ACVIM (Small animal Internal Medicine)  
kathleen.sennello@sonopath.com