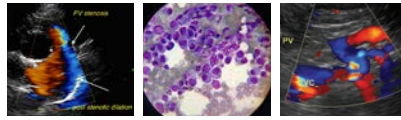


IMAGING PERFORMED BY

IntraPet.com



**SonoPath**

Clinical Sonography & Telecytology

EDUCATIONAL TELECONSULTATION SERVICES™

1-800-838-4268 info@sonopath.com SonoPath.com

**DATE PRESENTING CLINICAL SIGNS**

1/13/22 History: Patient hasn't been acting right and breathing heavy. Blood work showing HCT at 28%. Suspecting splenic tumor.

**PATIENT**

Millie Shorts Lab Results: Attached separately.  
Date of Previous IntraPet Ultrasound: No previous IntraPet scans.  
Sedation: Not required to complete full diagnostic ultrasound.  
Stat Report: Not requested.

**SPECIES**

Canine

**BREED**

Labrador Retriever

**SEX**

Spayed Female

**AGE**

4/8/10

**WEIGHT**

76 Pounds

**INTERPRETED BY**

Kathleen Sennello DVM,  
MS, Diplomate ACVIM  
(Small Animal Internal  
Medicine)

**IMAGING PERFORMED BY**

Rachel Brilhart RDMS

**HOSPITAL NAME**

Padonia Vet Hospital

**REFERRING VET**

Dr. Youssef

**INVOICE**

34227

**ULTRASONOGRAPHIC EXAMINATION OF THE ABDOMEN**

**Urinary System**

The urinary bladder is moderately distended with anechoic urine. The Bladder wall, trigone, ureteral papillae and visible urethra (to a depth of 2cm) appear normal with no evidence of wall thickening, mucosal irregularities, masses or cystic calculi.

The left kidney is somewhat large in size and has an irregular shape. The typical area of the left kidney measures approximately 7.41 cm with reduction in corticomedullary distinction. At the caudal pole of the left kidney, there is irregular, hypoechoic tissue with some cystic areas. This extends caudally into the retroperitoneal space. This abnormal area measures approximately 5.9 cm x 4.2 cm with a 1.21 cm hypoechoic cystic area. There is evidence of surrounding free fluid. There is no evidence of pyelectasia, nephroliths, infarcts or hydroureter. Renal vasculature is normal. Findings are most consistent with a mass lesion arising from the caudal pole of the left kidney .

The right kidney has a normal shape and size (6.87 cm) with mildly reduced corticomedullary distinction. Overall echogenicity is normal. There is no evidence of perinephric inflammation or effusion. While there is no overt mass effect associated with the right kidney, there is some free fluid in the area around the kidney (in the perinephric space). There is no evidence of pyelectasia, nephroliths or hydroureter.

**Adrenal Glands**

The left adrenal gland is normal in size measuring 0.88 cm at the caudal pole. It is observed in its normal position cranial to the left renal artery. It is normal in appearance (uniformly hypoechoic) and shape with no evidence of a mass effect.

The right adrenal gland is normal in size measuring 0.71 cm at the caudal pole. It is observed in its normal position between the cranial aspect of the right kidney and the caudal vena cava. It is normal in appearance (uniformly hypoechoic) and shape with no evidence of a mass effect.

**Spleen**

The spleen is subjectively normal in size, echotexture is homogenous, and the splenic capsule is smooth with no irregularities. The blood flow through the hilus and splenic parenchyma appears normal. No focal parenchymal abnormalities are visualized.

**Liver**

The liver is subjectively normal in size, and echogenicity with smooth peripheral margins. The parenchyma is homogenous echotexture. The visible portions of the vasculature and biliary tract appear normal. No focal nodules or cystic lesions are observed.

The gall bladder lumen is moderately distended. The wall of the gall bladder is not thickened and has a smooth mucosal surface. There is a moderate amount of non-organized echogenic debris. The cystic and common bile ducts are normal/not visible.

### ***Gastrointestinal***

The stomach contains minimal luminal contents. It measures at a normal thickness of <0.7cm with some variability due to the presence of rugal folds. The distinction of the gastric wall layers is adequate and there is no impression of reduced peristaltic activity. No masses or focal lesions were observed.

The visualized areas of duodenum, jejunum and ileum have a relatively uniform diameter with minimal fluid distension. Wall thickness is normal. Bowel loops follow a curvilinear path with distinct wall layering maintaining the typical 1:3 muscularis:mucosa layer ratio. The duodenum measured as normal (between 0.3-0.5cm in wall thickness) and the jejunum measured as normal (between 0.2-0.47cm.) Visualized peristalsis appears appropriate. There were no focal lesions consistent with obstruction or a mass effect observed.

The ileocecal junction was visualized and exhibited normal intact wall layering and is subjectively of normal thickness. Sections of colon are visualized with formed fecal material and gas shadowing distally. There is no observed focal or generalized colon wall thickening or loss of layering.

### ***Pancreas***

The pancreas is normal and isoechoic to surrounding mesentery. There is no evidence of nodules or cystic lesions. There is no evidence of regional mesenteric inflammation or fluid.

### ***Free Abdomen***

Scant free abdominal fluid is present. A small to moderate amount of retroperitoneal fluid is noted. No significant lymphadenomegaly is visualized. The omentum is hyperechoic surrounding both kidneys.

## **PRIMARY FINDINGS**

- Irregular left kidney with a suspected mass effect and free fluid in the retroperitoneal space – Findings are concerning for a renal mass (primary or metastatic) with surrounding fluid (possible hemorrhage?). The appearance of this lesion would favor a neoplastic lesion (hemangiosarcoma, carcinoma, etc.).
- Mild fluid in the retroperitoneal space surrounding the right kidney. No overt lesion is visualized associated with the right kidney, but the parenchyma appears somewhat irregular.

## **SECONDARY FINDINGS**

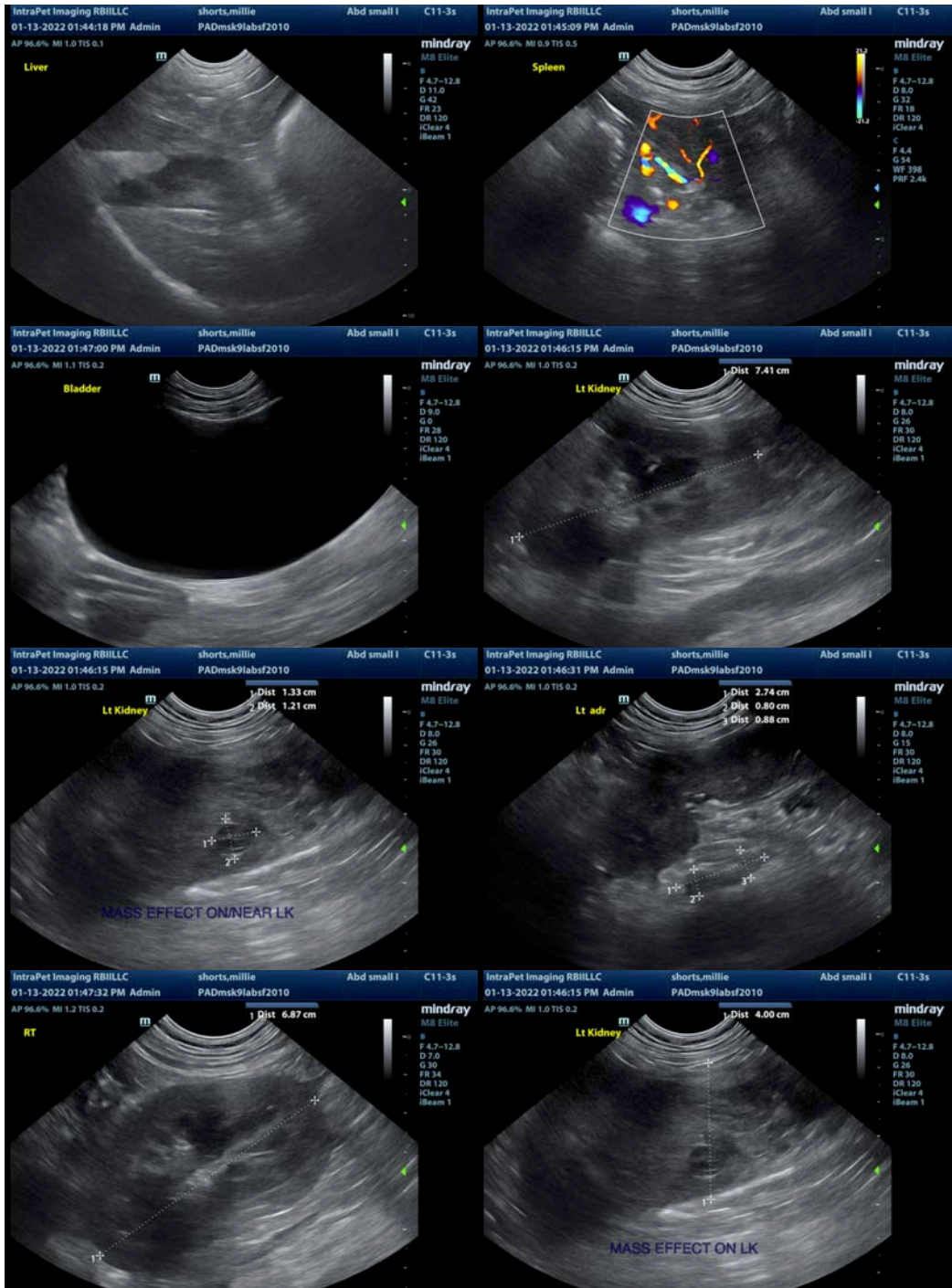
- Mild gallbladder debris – The significance of the aggregated gallbladder sludge is unclear. This could represent an early mucocele, cholestasis, or may be secondary to fasting.

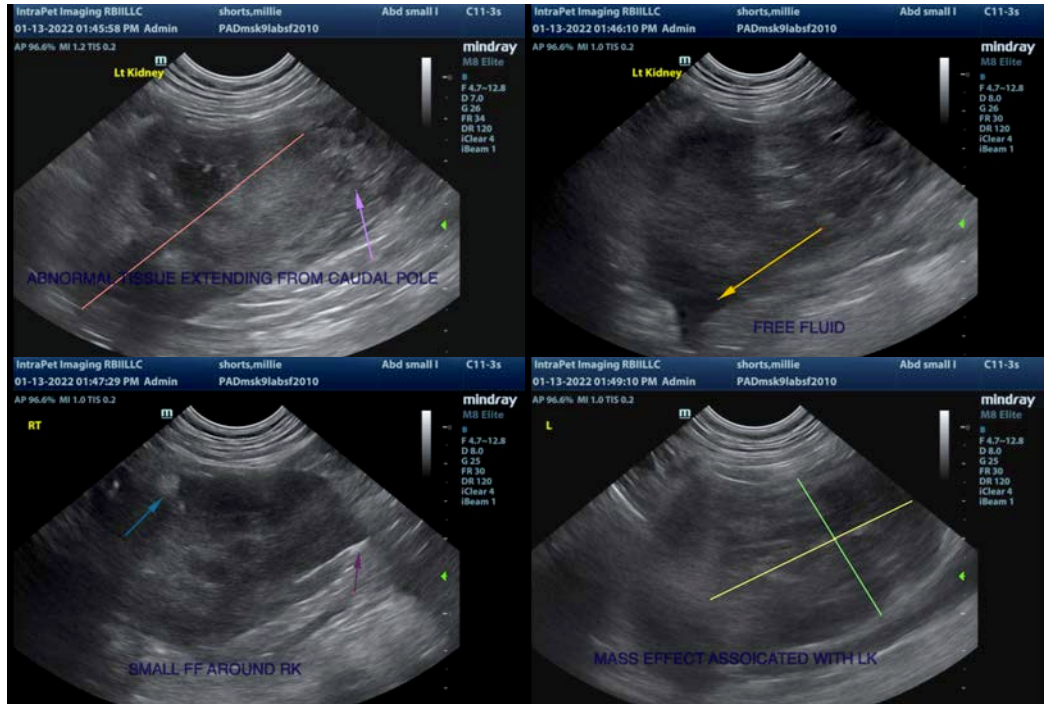
## **INTERPRETATION OF THE FINDINGS & FURTHER RECOMMENDATIONS**

There is irregular tissue associated with the caudal pole of the left kidney. There is free fluid in this area, and I am concerned about the possibility of a bleeding retroperitoneal mass. Additionally, there is some fluid on the right side, but no overt lesion is visualized. Of primary concern would be hemangiosarcoma in this location, but other possibilities exist.

- In the ideal situation, a CT scan would be recommended to further evaluate this area in addition to the right side to look for obvious lesions. Additionally, a fine needle aspirate could be considered under anesthesia at the same time. Recommend 3-view thoracic radiographs.
- If CT scan is not possible, then consider referral to a veterinary surgeon for evaluation and possible exploratory surgery.
- Prior to considering surgery, recommend bloodwork in a hydrated state along with a urinalysis to see if urine concentrating ability is present, as removal of the kidney may be necessary.

- Recommend a coagulation profile and blood pressure evaluation.





The information and recommendations provided are based on the images presented by the referring veterinarian. No evaluation can be communicated regarding pathology that was not visible in the image/video clips provided.

Thank you for this referral. If the clinical or image interpretation does not parallel your findings or if I can be of any further assistance please contact me.

Kathleen Sennello DVM,MS, Diplomate ACVIM (Small animal Internal Medicine)  
 kathleen.sennello@sonopath.com