



PATIENT

Maddie Morin

SPECIES

Canine

BREED

Chihuahua

SEX

Spayed Female

AGE

10 ½ years

WEIGHT

8.1 lbs

INTERPRETED BY

Kathleen Sennello
DVM, MS, Diplomate
ACVIM (Small Animal
Internal Medicine)

IMAGING PERFORMED BY

Dr. Sorbo

HOSPITAL NAME

Back Bay VC

REFERRING VET

Dr. Sorbo

INVOICE

95183

DATE

1/12/22

PRESENTING CLINICAL SIGNS

Hx of UTI in the past, but been fine of late. New: Nocturia new as of December 2021. Abnormal PE/Chem/CBC/UA Results: Proteinuria of 0.9p:c ratio (cystocentesis - doing free catch recheck today).. Anemia of 25.3%, SDMA 16 ug/L, CREA 1.2mg/dL, BUN 80mg/dL.

ULTRASONOGRAPHIC EXAMINATION OF THE ABDOMEN

Urinary System

The urinary bladder is moderately distended with anechoic urine. The Bladder wall, trigone, ureteral papillae and visible urethra (to a depth of 2cm) appear normal with no evidence of wall thickening, mucosal irregularities, masses or cystic calculi.

The left kidney has a normal shape and size (3.2 cm). Overall echogenicity is slightly hyperechoic with poor corticomedullary distinction and a typical 1:3 cortex:medulla ratio. There is no evidence of perinephric inflammation or effusion. Small, non-obstructive nephroliths were noted. There is no evidence of pyelectasia, infarcts or hydroureter. Renal vasculature is normal.

The right kidney has a normal shape and size (2.8 cm). Overall echogenicity is slightly hyperechoic with poor corticomedullary distinction and a typical 1:3 cortex:medulla ratio. There is no evidence of perinephric inflammation or effusion. Small, non-obstructive nephroliths were noted. There is no evidence of pyelectasia, infarcts or hydroureter. Renal vasculature is normal.

Adrenal Glands

The left adrenal gland is normal in size measuring 0.6 cm at the caudal pole. It is observed in its normal position cranial to the left renal artery. It is normal in appearance (uniformly hypoechoic) and shape with no evidence of a mass effect.

The right adrenal gland is normal in size measuring 0.4 cm at the caudal pole It is observed in its normal position between the cranial aspect of the right kidney and the caudal vena cava. It is normal in appearance (uniformly hypoechoic) and shape with no evidence of a mass effect.

Spleen

The spleen is subjectively normal in size, echotexture is homogenous, and the splenic capsule is smooth with no irregularities. The blood flow through the hilus and splenic parenchyma appears normal. No focal parenchymal abnormalities are visualized.

Liver

The liver is subjectively large in size, and echogenicity with smooth peripheral margins. The parenchyma is heterogenous in echotexture with subtle, indistinct focal mottling. The visible portions of the vasculature and biliary tract appear normal. There are numerous, ill-defined, hypoechoic nodules diffusely throughout the parenchyma and measured 0.25-0.5 cm. These nodules do not appear to disrupt the hepatic margins. The gallbladder lumen is moderately distended. The wall of the gallbladder



PATIENT

is not thickened and has a smooth mucosal surface. Luminal contents are primarily anechoic. The cystic and common bile ducts are normal/not visible.

Maddie Morin

SPECIES

Gastrointestinal

Canine

The stomach contains minimal luminal contents. It measures at a normal thickness of <0.7cm with some variability due to the presence of rugal folds. The distinction of the gastric wall layers is adequate and there is no impression of reduced peristaltic activity. No masses or focal lesions were observed.

BREED

Chihuahua

The visualized areas of duodenum, jejunum and ileum have a relatively uniform diameter with minimal fluid distension. Wall thickness is normal. Bowel loops follow a curvilinear path with distinct wall layering maintaining the typical 1:3 muscularis:mucosa layer ratio. The duodenum measured as normal (between 0.3-0.5cm in wall thickness) and the jejunum measured as normal (between 0.2-0.47cm.)

SEX

Spayed Female

Visualized peristalsis appears appropriate. There were no focal lesions consistent with obstruction or a mass effect observed.

AGE

10 ½ years

The ileocecal junction was visualized and exhibited normal intact wall layering and is subjectively of normal thickness. Sections of colon are visualized with formed fecal material and gas shadowing distally. There is no observed focal or generalized colon wall thickening or loss of layering.

WEIGHT

8.1 lbs

Pancreas

The pancreas is normal and isoechoic to surrounding mesentery. There is no evidence of nodules or cystic lesions. There is no evidence of regional mesenteric inflammation or fluid.

INTERPRETED BY

Kathleen Sennello
DVM, MS, Diplomate
ACVIM (Small Animal
Internal Medicine)

Free Abdomen

Evaluation of the peritoneal cavity did not reveal any evidence of effusion, or subjective lymphadenomegaly. The Medial iliac nodes appear normal and there was no evidence of a caudal aortic thrombus at the bifurcation. The omentum is of normal uniform echogenicity.

IMAGING PERFORMED BY

Dr. Sorbo

Heart

A brief view of the heart was submitted. No pericardial effusion was seen.

HOSPITAL NAME

Back Bay VC

ULTRASONOGRAPHIC FINDINGS

PRIMARY FINDINGS:

REFERRING VET

Dr. Sorbo

- Decreased corticomedullary distinction in both kidneys with non-obstructive nephroliths. Mild loss of corticomedullary distinction in both kidneys could be consistent with chronic degenerative disease or interstitial nephrosis. The hyperechoic mineralized foci observed at the corticomedullary junction of the left/right kidney are consistent with small, non-obstructive nephroliths.

INVOICE

95183

- Large, heterogenous liver with ill-defined, hypoechoic nodules. The diffuse hepatic changes are non-specific and could be consistent with vacuolar hepatopathy, nodular hyperplasia, inflammatory/immune-mediated disease, fibrosis, extramedullary hematopoiesis, toxic

DATE

1/12/22



PATIENT

hepatopathy (e.g., copper), infiltrative neoplasia (less likely) or other hepatopathy.

Maddie Morin

SPECIES

INTERPRETATION OF THE FINDINGS & FURTHER RECOMMENDATIONS

Canine

The changes observed in the kidneys are non-specific and most consistent with chronic, progressive kidney disease-likely age related.

BREED

Chihuahua

- Recommend urinalysis and culture to rule out a concurrent urinary tract infection.
- Recommend blood pressure evaluation.
- If symptomatic then I recommend supportive treatment for azotemia including anti-nausea medication, appetite stimulants, phosphate binders if necessary, antacids if necessary and a low-protein diet if tolerated.

SEX

Spayed Female

Additionally the liver is large and heterogenous with ill-defined, hypoechoic nodules. This appearance favors benign nodules, but correlate with how the patient is feeling and liver values. If there is concern consider liver function test and FNA of the liver.

AGE

10 ½ years

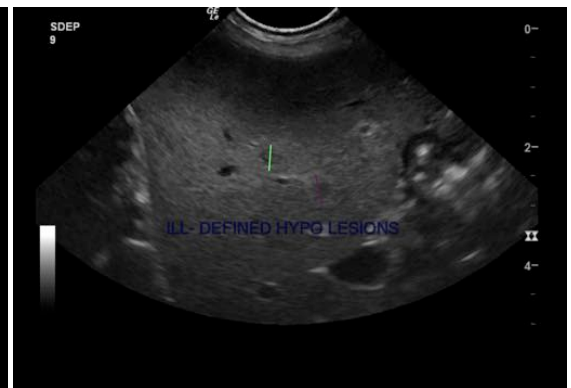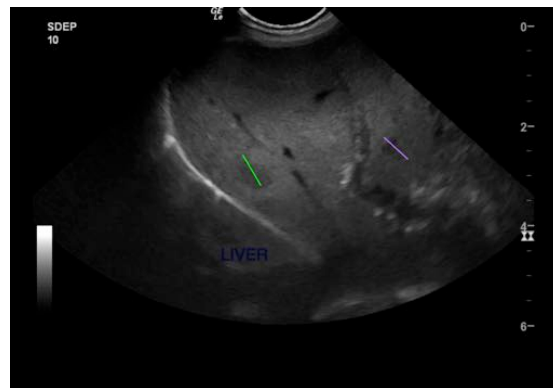
An obvious cause for the visualized nocturia is not observed. If blood pressure is normal you can consider a low dose of Proin. A cause for the anemia reported is not readily identified. Consider treatment for GI ulceration and close monitoring.

WEIGHT

8.1 lbs

INTERPRETED BY

Kathleen Sennello
DVM, MS, Diplomate
ACVIM (Small Animal
Internal Medicine)

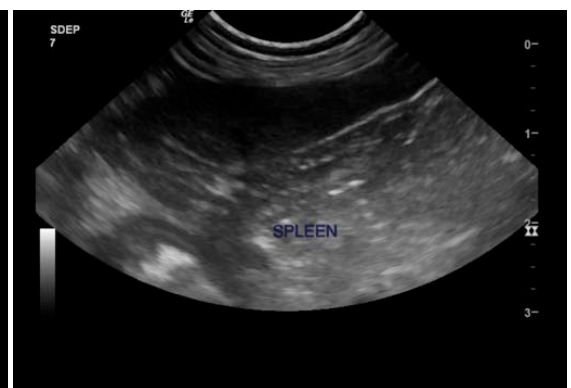
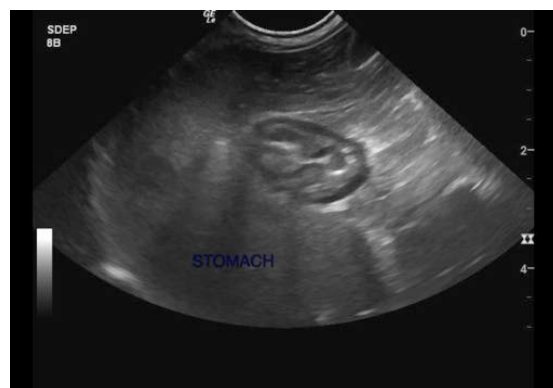

IMAGING PERFORMED BY

Dr. Sorbo

HOSPITAL NAME

Back Bay VC



REFERRING VET

Dr. Sorbo

INVOICE

95183

DATE

1/12/22



PATIENT

Maddie Morin

SPECIES

Canine

BREED

Chihuahua

SEX

Spayed Female

AGE

10 ½ years

WEIGHT

8.1 lbs

INTERPRETED BY

Kathleen Sennello
DVM, MS, Diplomate
ACVIM (Small Animal
Internal Medicine)

**IMAGING
PERFORMED BY**

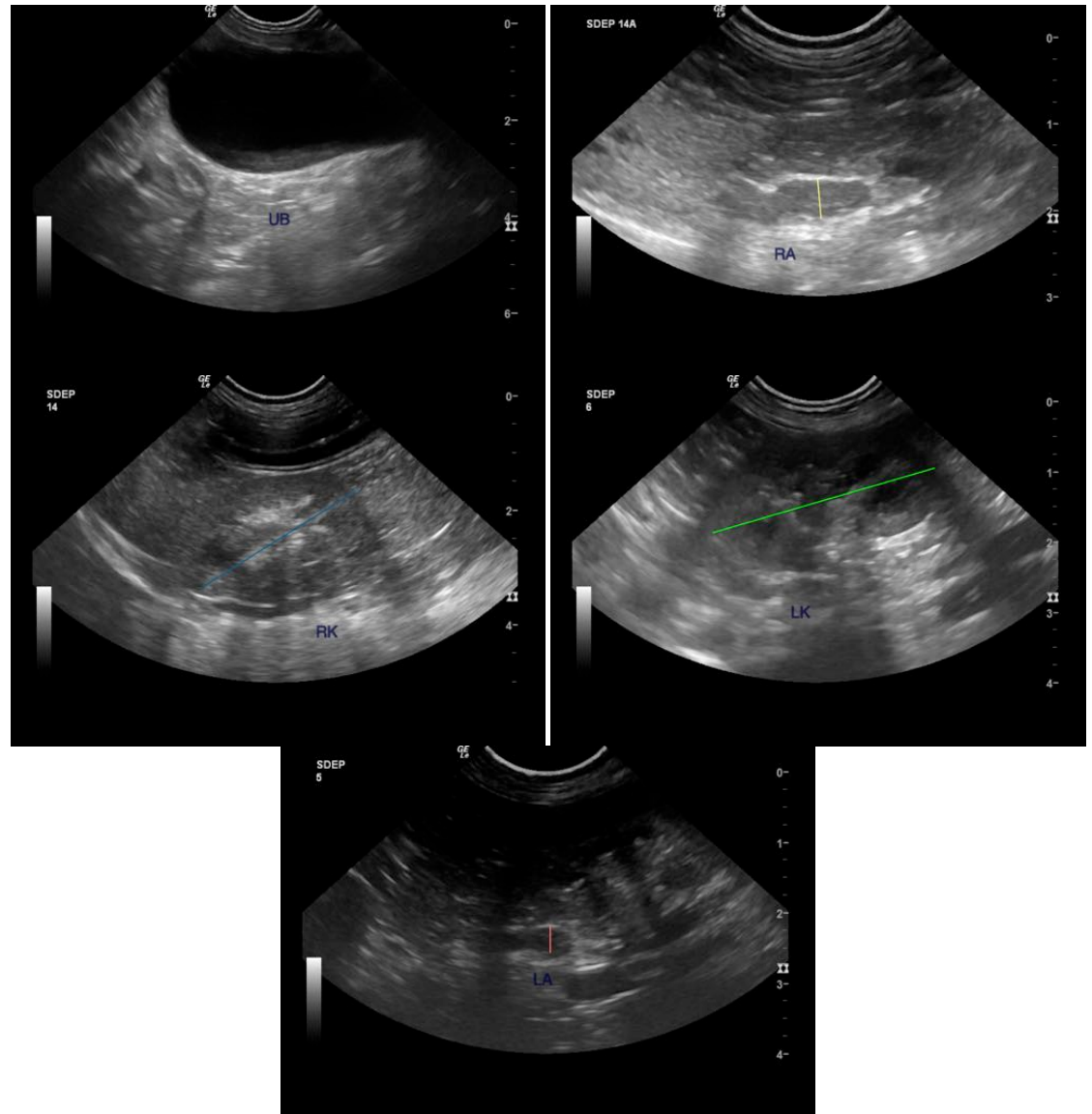
Dr. Sorbo

HOSPITAL NAME

Back Bay VC

REFERRING VET

Dr. Sorbo



The information and recommendations provided are based on the images presented by the referring veterinarian. No evaluation can be communicated regarding pathology that was not visible in the image/video clips provided.

Thank you for this referral. If the clinical or image interpretation does not parallel your findings or if I can be of any further assistance please contact me.

Kathleen Sennello DVM,MS, Diplomate ACVIM (Small animal Internal Medicine)
kathleen.sennello@sonopath.com

INVOICE

95183

DATE

1/12/22