

**PATIENT PRESENTING CLINICAL SIGNS**

**PATIENT** Cinnamon Chastain  
**SPECIES** Canine  
**BREED** Brittany Spaniel

Physical Exam BCS 5/9 EENTO: Eyes cataracts. Ears clean. Nose clean/clear. Throat palpates normally. Oral cavity - moderate tartar Skin/Coat: Dry, coarse coat. No visible abnormalities seen, no parasites noted. Musculoskeletal: Ambulatory x 4, musculature appears WNL. Neurological: Appropriate mentation, no CN deficits, symmetrical pupils. Heart: No heart murmur or arrhythmia. Strong, synchronous and symmetrical femoral pulses. Lungs: Clear breath sounds auscultated in all lung fields bilaterally, eupneic. LN: WNL Abdomen: Soft, non-painful palpation. Urogenital: WNL Rectal: N/E Pain score: CSU Laboratory findings: Assessment: r/o hypothyroidism, hepatopathy  
Abnormal PE/Chem/CBC/UA Results: Bile Acids WNL- LABS attached- AUS to check liver

**ULTRASONOGRAPHIC EXAMINATION OF THE ABDOMEN**

**Urinary System**

**SEX** Spayed Female  
The urinary bladder is moderately distended with mild primarily suspended echogenic debris present. The bladder wall, trigone, ureteral papillae and visible urethra (to a depth of 2cm) appear normal with no evidence of wall thickening, mucosal irregularities, masses or calculi. Echogenic debris of this type can be associated with small crystals, cellular debris and proteinaceous debris.

**AGE** 11 years  
The left kidney has a normal shape and size (5.3 cm). Overall echogenicity is normal with adequate corticomedullary distinction and a typical 1:3 cortex:medulla ratio. There is no evidence of perinephric inflammation or effusion. There is no evidence of pyelectasia, nephroliths, infarcts or hydroureter. Renal vasculature is normal.

**WEIGHT** 47 Pounds  
The right kidney has a normal shape and size (3.3 cm). Overall echogenicity is normal with adequate corticomedullary distinction and a typical 1:3 cortex:medulla ratio. There is no evidence of perinephric inflammation or effusion. There is no evidence of pyelectasia, nephroliths, infarcts or hydroureter. Renal vasculature is normal.

**INTERPRETED BY**

Kathleen Sennello DVM,  
MS, Diplomate ACVIM  
(Small Animal Internal  
Medicine)

**Adrenal Glands**

The left adrenal gland is normal in size measuring 0.77 cm at the caudal pole It is observed in its normal position cranial to the left renal artery. It is normal in appearance (uniformly hypoechoic) and shape with no evidence of a mass effect.

The right adrenal gland is normal in size measuring 0.48 cm at the caudal pole It is observed in its normal position between the cranial aspect of the right kidney and the caudal vena cava. It is normal in appearance (uniformly hypoechoic) and shape with no evidence of a mass effect.

**IMAGING PERFORMED BY**

Loetitia Saint-Jacques, RVT

**HOSPITAL NAME**

Options VC

**REFERRING VET**

Dr. Pearson

**Spleen**

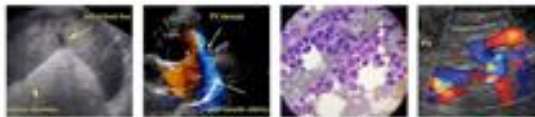
The spleen is subjectively normal in size The spleen echotexture is heterogenous and mottled, the splenic capsule is smooth with no irregularities. The blood flow through the hilus and splenic parenchyma appears normal. No focal parenchymal abnormalities are visualized.

**INVOICE**

95182

**DATE**

1/12/22



**PATIENT** *Liver*

Cinnamon Chastain

**SPECIES**

Canine

**BREED**

Brittany Spaniel

**SEX**

Spayed Female

**AGE**

11 years

**WEIGHT**

47 Pounds

**INTERPRETED BY**

Kathleen Sennello DVM,  
MS, Diplomate ACVIM  
(Small Animal Internal  
Medicine)

**IMAGING PERFORMED BY**

Loetitia Saint-Jacques, RVT

**HOSPITAL NAME**

Options VC

**REFERRING VET**

Dr. Pearson

**INVOICE**

95182

**DATE**

1/12/22

The liver is subjectively large in size, and echogenicity with smooth peripheral margins. The parenchyma is heterogenous in echotexture with subtle, indistinct focal mottling. The visible portions of the vasculature and biliary tract appear normal. There is a very large mass effect visualized obscuring most of the normal hepatic parenchyma. The mass is somewhat irregular and measured > 7.14 x 9.54 cm. . The gallbladder lumen is moderately distended. The wall of the gallbladder is not thickened and has a smooth mucosal surface. Luminal contents are primarily anechoic. The cystic and common bile ducts are normal/not visible.

**Gastrointestinal**

The stomach is moderately dilated with fluid and irregular shadowing material most consistent with normal ingesta and gas. It measures at a normal thickness of <0.7cm with some variability due to the presence of rugal folds. The distinction of the gastric wall layering is adequate and there is no impression of reduced peristaltic activity. No masses or focal lesions were observed.

The visualized areas of duodenum, jejunum and ileum have a relatively uniform diameter with minimal fluid distension. Wall thickness is normal. Bowel loops follow a curvilinear path with distinct wall layering maintaining the typical 1:3 muscularis:mucosa layer ratio. The duodenum measured as normal (between 0.3-0.5cm in wall thickness) and the jejunum measured as normal (between 0.2-0.47cm.) Visualized peristalsis appears appropriate. There were no focal lesions consistent with obstruction or a mass effect observed.

The ileocecal junction was visualized and exhibited normal intact wall layering and is subjectively of normal thickness. Sections of colon are visualized with formed fecal material and gas shadowing distally. There is no observed focal or generalized colon wall thickening or loss of layering.

**Pancreas**

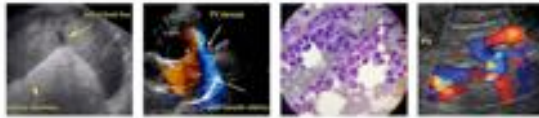
The pancreas is normal and isoechoic to surrounding mesentery. There is no evidence of nodules or cystic lesions. There is no evidence of regional mesenteric inflammation or fluid.

**Free Abdomen**

Evaluation of the peritoneal cavity did not reveal any evidence of effusion, or subjective lymphadenomegaly. The Medial iliac nodes appear normal and there was no evidence of a caudal aortic thrombus at the bifurcation. The omentum is of normal uniform echogenicity.

**Heart**

A brief view of the heart was submitted. No pericardial effusion was seen.



**PATIENT**      **ULTRASONOGRAPHIC FINDINGS**

Cinnamon Chastain

**PRIMARY FINDINGS:**

**SPECIES**

Canine

**BREED**

Brittany Spaniel

**SEX**

Spayed Female

**AGE**

11 years

**WEIGHT**

47 Pounds

- Large, solid, mixed echogenic hepatic mass. This is most consistent with a primary liver mass (adenoma or carcinoma).
- Echogenic debris in the urinary bladder. The echogenic debris in the bladder lumen could be consistent with cells, crystals, and/or mucus. Recommend urinalysis and culture
- Mildly mottled spleen. The diffuse splenic changes are non-specific and could be consistent with lymphoid hyperplasia, extramedullary hematopoiesis, infiltrative neoplasia, inflammation, other. Cytology or histopathology would be necessary to get a definitive diagnosis.

**INTERPRETATION OF THE FINDINGS & FURTHER RECOMMENDATIONS**

There is a very large, solid, hepatic mass visualized. This mass effect obscures visualization of the “normal” remaining liver. If surgical resection is to be considered a contrast CT scan would be recommended to determine how much of the liver is actually involved and if surgical resection is possible. If surgical resection is successful these large hepatic masses can have a favorable prognosis.

I recommend three view thoracic radiographs.

I recommend urinalysis and culture to further evaluate the echogenic debris in the urinary bladder.

The significance of the mild mottling in the spleen is unknown. I think this is unlikely to be related to the liver changes, but a FNA of the spleen can be considered.

**INTERPRETED BY**

Kathleen Sennello DVM,  
MS, Diplomate ACVIM  
(Small Animal Internal  
Medicine)

**IMAGING PERFORMED BY**

Loetitia Saint-Jacques, RVT

**HOSPITAL NAME**

Options VC

**REFERRING VET**

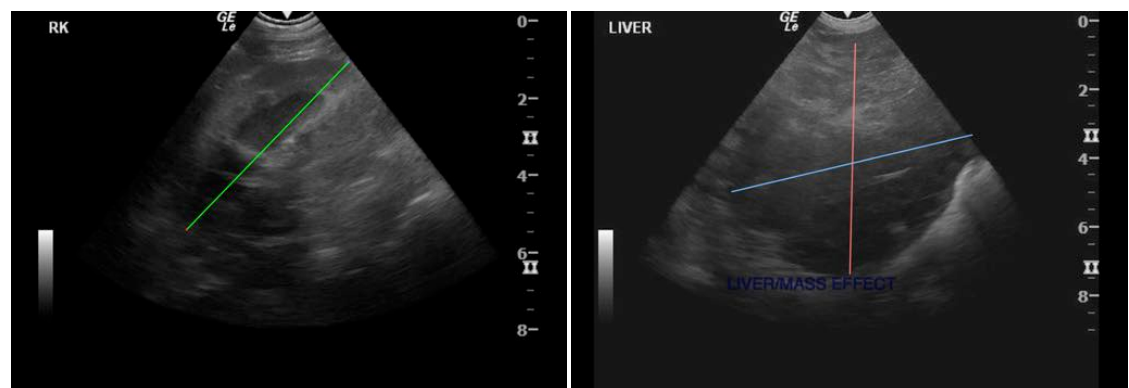
Dr. Pearson

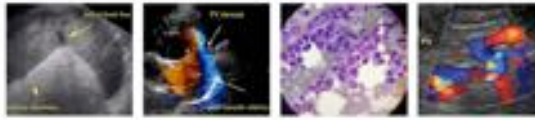
**INVOICE**

95182

**DATE**

1/12/22





**PATIENT**

Cinnamon Chastain

**SPECIES**

Canine

**BREED**

Brittany Spaniel

**SEX**

Spayed Female

**AGE**

11 years

**WEIGHT**

47 Pounds

**INTERPRETED BY**

Kathleen Sennello DVM,  
 MS, Diplomate ACVIM  
 (Small Animal Internal  
 Medicine)

**IMAGING PERFORMED  
 BY**

Loetitia Saint-Jacques, RVT

**HOSPITAL NAME**

Options VC

**REFERRING VET**

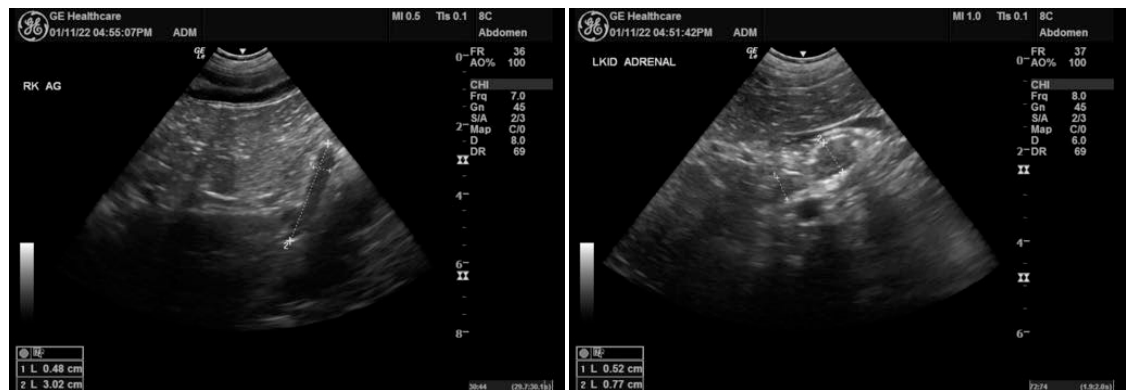
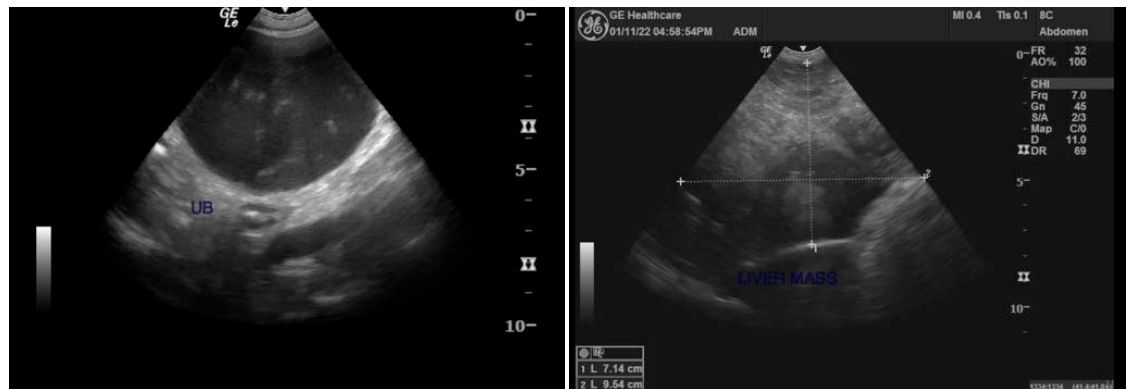
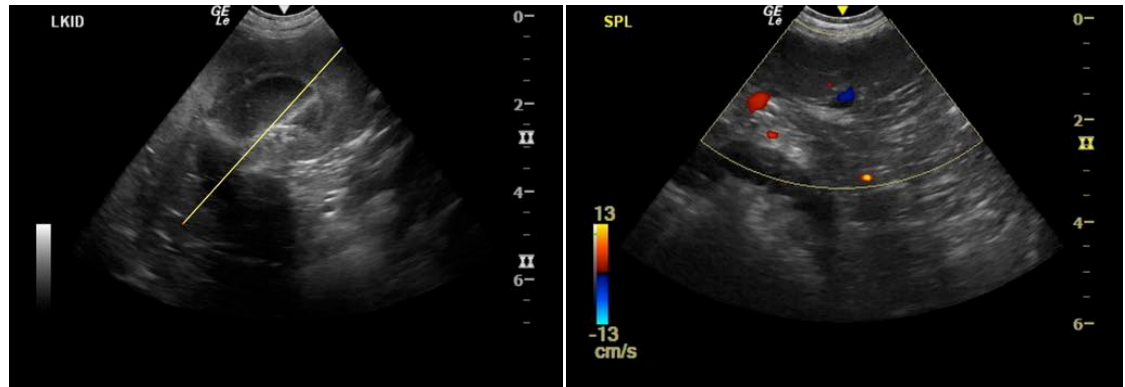
Dr. Pearson

**INVOICE**

95182

**DATE**

1/12/22



The information and recommendations provided are based on the images presented by the referring veterinarian. No evaluation can be communicated regarding pathology that was not visible in the image/video clips provided.

Thank you for this referral. If the clinical or image interpretation does not parallel your findings or if I can be of any further assistance please contact me.

Kathleen Sennello DVM,MS, Diplomate ACVIM (Small animal Internal Medicine)

kathleen.sennello@sonopath.com