



**PATIENT PRESENTING CLINICAL SIGNS**

Loli Nelson  
Liver values elevated

**SPECIES**  
Canine  
Abnormal PE/Chem/CBC/UA Results: ALKP 258, ALT 159, Chol 485, GGT 151, Trig 6632, HGB 22.5, MCHC 44.0, Baso 0.38, MCH 29.6, RDW 18.8, MPV 13.3

**BREED ULTRASONOGRAPHIC EXAMINATION OF THE ABDOMEN**

Lab  
**Urinary System**

**SEX**  
Spayed Female  
The urinary bladder is moderately distended with anechoic urine. The Bladder wall, trigone, ureteral papillae and visible urethra (to a depth of 2cm) appear normal with no evidence of wall thickening, mucosal irregularities, masses or cystic calculi.

**AGE**  
8 Years  
The left kidney has a normal shape and size (5.79 cm). Overall echogenicity is normal with adequate corticomedullary distinction and a typical 1:3 cortex:medulla ratio. There is no evidence of focal perinephric inflammation or effusion. There is no evidence of pyelectasia, nephroliths, infarcts or hydroureter. Renal vasculature is normal.

**WEIGHT**  
65 Pounds  
The right kidney has a normal shape and size (5.87 cm). Overall echogenicity is normal with adequate corticomedullary distinction and a typical 1:3 cortex:medulla ratio. There is no evidence of focal perinephric inflammation or effusion. There is no evidence of pyelectasia, nephroliths, infarcts or hydroureter. Renal vasculature is normal.

**INTERPRETED BY**

Kathleen Sennello DVM,  
MS, Diplomate ACVIM  
(Small Animal Internal  
Medicine)

**Adrenal Glands**

The left adrenal gland is normal in size measuring 0.49 cm at the caudal pole. It is observed in its normal position cranial to the left renal artery. It is normal in appearance (uniformly hypoechoic) and shape with no evidence of a mass effect.

**IMAGING PERFORMED BY**

Jessica Miller

The right adrenal gland is normal in size measuring 0.48 cm at the caudal pole. It is observed in its normal position between the cranial aspect of the right kidney and the caudal vena cava. It is normal in appearance (uniformly hypoechoic) and shape with no evidence of a mass effect.

**HOSPITAL NAME**

Summit Dog & Cat  
Hospital

**Spleen**

The spleen is subjectively normal in size, echotexture is homogenous, and the splenic capsule is smooth with no irregularities. The blood flow through the hilus and splenic parenchyma appears normal. No focal parenchymal abnormalities are visualized.

**REFERRING VET**

Dr. Vogler

**Liver**

The liver is borderline small, with normal echogenicity and smooth peripheral margins. The parenchyma is mildly heterogenous in echotexture with subtle, indistinct focal mottling. The visible portions of the vasculature and biliary tract appear normal. No focal nodules or cystic lesions are observed.

**INVOICE**

44149

**DATE**

1/11/23

The gallbladder lumen is moderately distended. The wall of the gall bladder is not thickened and has a smooth mucosal surface. Luminal contents are mild and primarily anechoic. The cystic and common bile ducts are normal/not visible.

**Gastrointestinal**

The stomach contains mild fluid. It measures at a normal thickness of <0.7cm with some variability due to the presence of rugal folds. The distinction of the gastric wall layers is adequate and there is no impression of reduced peristaltic activity. No masses or focal lesions were observed.



**PATIENT**

Loli Nelson

**SPECIES**

Canine

**BREED**

Lab

**SEX**

Spayed Female

**AGE**

8 Years

**WEIGHT**

65 Pounds

**INTERPRETED BY**

Kathleen Sennello DVM,  
MS, Diplomate ACVIM  
(Small Animal Internal  
Medicine)

**IMAGING PERFORMED BY**

Jessica Miller

**HOSPITAL NAME**

Summit Dog & Cat  
Hospital

**REFERRING VET**

Dr. Vogler

**INVOICE**

44149

**DATE**

1/11/23

The visualized areas of duodenum, jejunum and ileum have a relatively uniform diameter with minimal fluid distension. Wall thickness is normal. Bowel loops follow a curvilinear path with distinct wall layering maintaining the typical 1:3 muscularis:mucosa layer ratio. Duodenum wall measures 0.63 cm. Jejunum wall measures 0.37 cm. Visualized peristalsis appears appropriate. There were no focal lesions consistent with obstruction or a mass effect observed.

The ileocecal junction was visualized and exhibited normal intact wall layering and is subjectively of normal thickness. Sections of colon are visualized with formed fecal material and gas shadowing distally. There is no observed focal or generalized colon wall thickening or loss of layering.

**Pancreas**

The pancreas is normal and isoechoic to surrounding mesentery. There is no evidence of nodules or cystic lesions. There is no evidence of regional mesenteric inflammation or fluid.

**Free Abdomen**

Evaluation of the peritoneal cavity did not reveal any evidence of effusion, or subjective lymphadenomegaly. The Medial iliac nodes appear normal and there was no evidence of a caudal aortic thrombus at the bifurcation. The omentum is of normal uniform echogenicity.

**ULTRASONOGRAPHIC FINDINGS**

- Mildly heterogeneous, borderline small liver – The diffuse hepatic changes are non-specific and could be consistent with vacuolar hepatopathy, nodular hyperplasia, inflammatory/immune-mediated disease, fibrosis, extramedullary hematopoiesis, toxic hepatopathy (e.g., copper), infiltrative neoplasia (less likely) or other hepatopathy.

**INTERPRETATION OF THE FINDINGS & FURTHER RECOMMENDATIONS**

No focal lesions are visualized associated with the liver or biliary tract. There is very mild heterogeneity of the parenchyma, but this could be appropriate for age. These are my recommendations for further evaluation of a non-specific elevation in liver enzymes:

- Consider close evaluation of history for possible toxic changes examine medications, diet, dietary indiscretion etc...
- Consider PCR on urine/serum for leptospirosis (if not on antibiotics)/serology if recent antibiotic history
- If not already done, consider pre and post prandial bile acids to evaluate liver function
- If the ALP is significantly elevated relative to the ALT and symptoms consistent with Cushing's are present, consider adrenal function testing (ACTH stim)
- Consider Fine needle aspirate if round cell neoplasia is on your differentia list (25 g needle, normal coags)
- If no response to supportive care (Denamarin, fluids, antibiotics, +/- ursodiol etc.) Consider liver biopsy with samples obtained for histopathology, culture, and copper levels.

The triglyceride level is very elevated in the lab work provided in the history. Recommend repeat evaluation of the chemistry panel after a strict 12-24 hour fast, as sometimes the lipidemia will cause artifactual increases in liver enzymes on lab work. If liver enzyme values are persistently high, recommend a liver function test and the previously recommended steps. Additionally, if the triglyceride levels are that significantly elevated despite a persistent fast, consider further workup (thyroid



**PATIENT**

Loli Nelson

evaluation, diet change, etc.) and evaluation for this issue, and immediately start an ultra-low-fat prescription diet.

**SPECIES**

Canine

The liver is subjectively small, but this could be normal for this individual. If liver function testing is abnormal, strongly recommend a liver biopsy, as female Labradors can get chronic active hepatitis, which can progress to liver failure over time.

**BREED**

Lab

**SEX**

Spayed Female

**AGE**

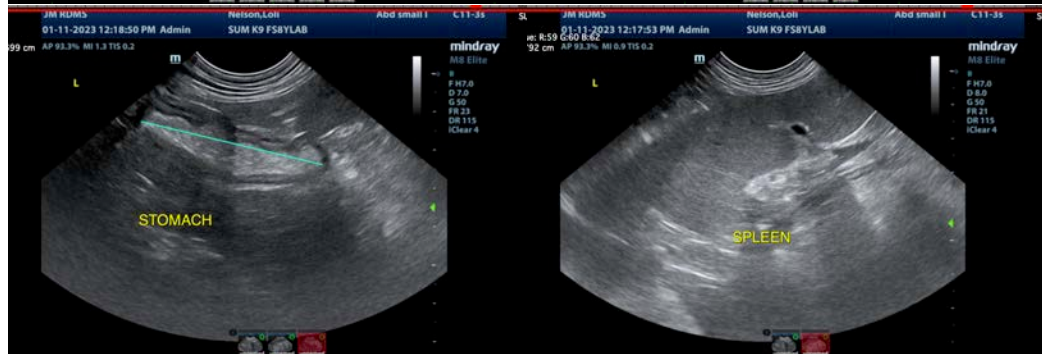
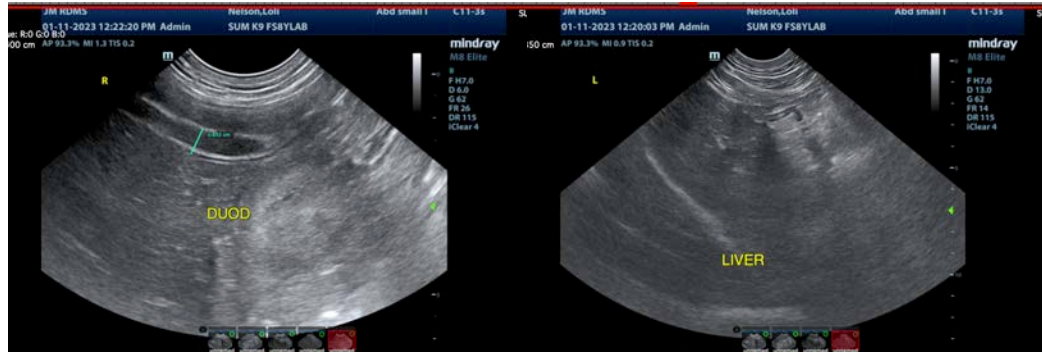8 Years

**WEIGHT**

65 Pounds

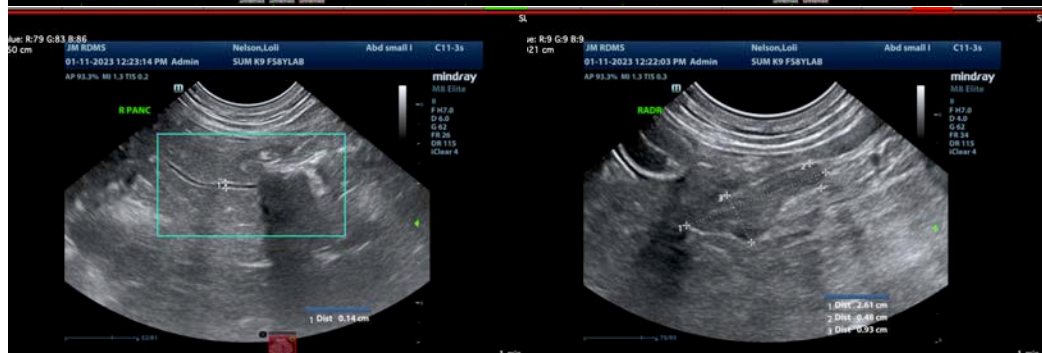
**INTERPRETED BY**

Kathleen Sennello DVM, MS, Diplomate ACVIM (Small Animal Internal Medicine)



**IMAGING PERFORMED BY**

Jessica Miller



**HOSPITAL NAME**

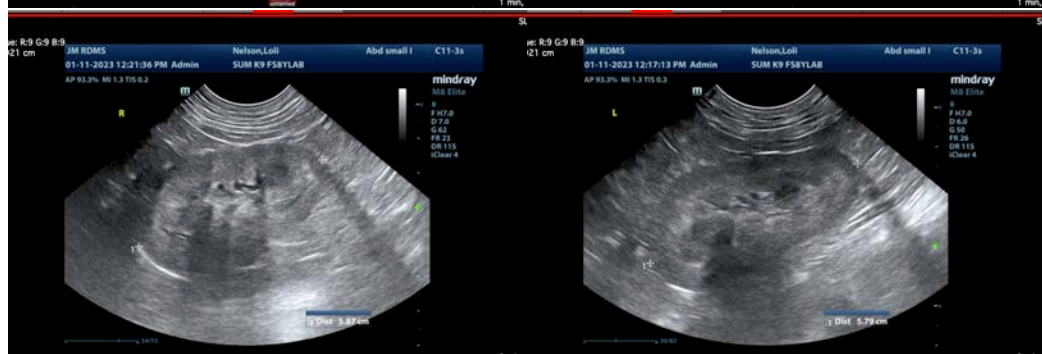
Summit Dog & Cat Hospital

**REFERRING VET**

Dr. Vogler

**INVOICE**

44149



**DATE**

1/11/23



**PATIENT**

Loli Nelson

**SPECIES**

Canine

**BREED**

Lab

**SEX**

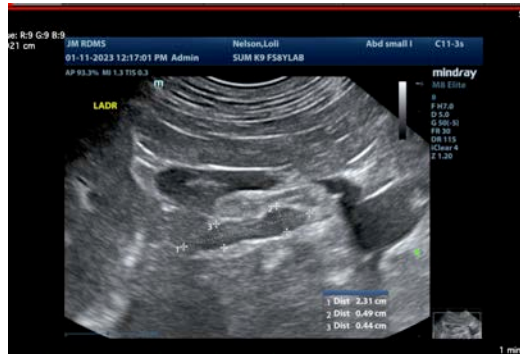Spayed Female

**AGE**

8 Years

**WEIGHT**

65 Pounds



The information and recommendations provided are based on the images presented by the referring veterinarian/sonographer. No evaluation can be communicated regarding pathology that was not visible in the image/video clips provided.

Thank you for this referral. If the clinical or image interpretation does not parallel your findings or if I can be of any further assistance please contact me.

Kathleen Sennello DVM,MS, Diplomate ACVIM (Small animal Internal Medicine)

kathleen.sennello@sonopath.com

**INTERPRETED BY**

Kathleen Sennello DVM,  
MS, Diplomate ACVIM  
(Small Animal Internal  
Medicine)

**IMAGING PERFORMED BY**

Jessica Miller

**HOSPITAL NAME**

Summit Dog & Cat  
Hospital

**REFERRING VET**

Dr. Vogler

**INVOICE**

44149

**DATE**

1/11/23