



PATIENT

Gracie Vitt

SPECIES

Canine

BREED

Labradoodle

SEX

Spayed Female

AGE

11 Years

WEIGHT

39 Pounds

INTERPRETED BY

Kathleen Sennello DVM,
MS, Diplomate ACVIM
(Small Animal Internal
Medicine)

**IMAGING
PERFORMED BY**

Dr. Gallick

HOSPITAL NAME

Magnolia Springs VC

REFERRING VET

Dr. Gallick

INVOICE

44105

DATE

1/11/23

PRESENTING CLINICAL SIGNS

Patient doing clinically well, has history of elevated liver values. Chronically getting more elevated.

ULTRASONOGRAPHIC EXAMINATION OF THE ABDOMEN

Urinary System

The urinary bladder is moderately distended with anechoic urine. The Bladder wall, trigone, ureteral papillae and visible urethra (to a depth of 2cm) appear normal with no evidence of wall thickening, mucosal irregularities, masses or cystic calculi.

The left kidney has a normal shape and size (5.49 cm). Overall echogenicity is normal with adequate corticomedullary distinction and a typical 1:3 cortex:medulla ratio. There is no evidence of focal perinephric inflammation or effusion. There is no evidence of pyelectasia, nephroliths, infarcts or hydroureter. Renal vasculature is normal.

The right kidney has a normal shape and size (5.6 cm). Overall echogenicity is normal with adequate corticomedullary distinction and a typical 1:3 cortex:medulla ratio. There is no evidence of focal perinephric inflammation or effusion. There is no evidence of pyelectasia, nephroliths, infarcts or hydroureter. Renal vasculature is normal.

Adrenal Glands

The left adrenal gland is borderline large, measuring 0.87 cm at the cranial pole, 0.70 cm at the caudal pole, and 2.3 cm in length. It is observed in its normal position cranial to the left renal artery. It is somewhat abnormal in appearance in that there is a hyperechoic nodule in the cranial pole measuring 0.64 cm x 0.56 cm. There is no obvious evidence of vascular invasion visualized.

The right adrenal gland is normal in size measuring 0.61 cm at the caudal pole. It is observed in its normal position between the cranial aspect of the right kidney and the caudal vena cava. It is normal in appearance (uniformly hypoechoic) and shape with no evidence of a mass effect.

Spleen

The spleen is subjectively normal in size, echotexture is homogenous, and the splenic capsule is smooth with no irregularities. The blood flow through the hilus and splenic parenchyma appears normal. There are numerous small hyperechoic nodules visualized within the parenchyma, most consistent with myelolipomas.

Liver

The liver is large and hyperechoic with smooth peripheral margins. The parenchyma is heterogenous in echotexture with subtle, indistinct focal mottling. The visible portions of the vasculature and biliary tract appear normal. There are too numerous to count ill-defined, hypoechoic nodules throughout the liver, varying in size from 0.5-1.0 cm.

The gall bladder lumen is moderately distended. The wall of the gall bladder is not thickened and has a smooth mucosal surface. There is a moderate amount of non-organized echogenic debris. The cystic and common bile ducts are normal/not visible.

Gastrointestinal

The stomach contains minimal luminal contents. It measures at a normal thickness of <0.7cm with some variability due to the presence of rugal folds. The distinction of the gastric wall layers is adequate and there is no impression of reduced peristaltic activity. No masses or focal lesions were observed.



PATIENT

Gracie Vitt

SPECIES

Canine

BREED

Labradoodle

SEX

Spayed Female

AGE

11 Years

WEIGHT

39 Pounds

INTERPRETED BY

Kathleen Sennello DVM,
MS, Diplomate ACVIM
(Small Animal Internal
Medicine)

**IMAGING
PERFORMED BY**

Dr. Gallick

HOSPITAL NAME

Magnolia Springs VC

REFERRING VET

Dr. Gallick

INVOICE

44105

DATE

1/11/23

The visualized areas of duodenum, jejunum and ileum have a uniform diameter with minimal fluid distension. Wall appears subjectively, mildly increased. Bowel loops follow a typical curvilinear path with distinct wall layering. Mild mucosal fogging is visualized. Visualized peristalsis appears appropriate. There were no focal lesions consistent with obstruction or a mass effect observed. Duodenum wall measures 0.40 cm. Jejunum wall measures 0.36 cm.

The ileocecal junction was visualized and exhibited normal intact wall layering and is subjectively of normal thickness. Sections of colon are visualized with formed fecal material and gas shadowing distally. There is no observed focal or generalized colon wall thickening or loss of layering.

Pancreas

The pancreas is normal and isoechoic to surrounding mesentery. There is no evidence of nodules or cystic lesions. There is no evidence of regional mesenteric inflammation or fluid.

Free Abdomen

There is scant free abdominal fluid. No lymphadenopathy. The omentum is of normal echogenicity.

Other

A small anechoic structure is visualized in the mid abdomen measuring 0.47 cm x 0.82 cm, most consistent with an omental cyst.

PRIMARY FINDINGS

- Hyperechoic nodule in the cranial pole of the left adrenal – Left/right adrenomegaly could be consistent with neoplasia (e.g., adenoma, carcinoma, pheochromocytoma), hyperplasia, inflammation, other.
- Large, hyperechoic, heterogeneous liver with ill-defined hypoechoic nodules – The diffuse hepatic changes are non-specific and could be consistent with vacuolar hepatopathy, nodular hyperplasia, inflammatory/immune-mediated disease, fibrosis, extramedullary hematopoiesis, toxic hepatopathy (e.g., copper), infiltrative neoplasia (less likely) or other hepatopathy. The hypoechoic nodules are diffuse and likely benign in nature, but recommend a fine needle aspirate.
- Moderate gallbladder debris – The significance of the aggregated gallbladder debris is unclear. This could represent an early mucocele, cholestasis, or may be secondary to fasting but seems unlikely to be causing a current issue. Recommend continued monitoring.
- Mild mucosal fogging of the small intestine – The significance of this is unclear, but this can be associated with underlying gastrointestinal disease.
- Scant free abdominal fluid

SECONDARY FINDINGS

- Hyperechoic nodules visualized in the spleen – These are most consistent with benign myelolipomas, but continued monitoring is warranted, as underlying neoplasia cannot be definitively ruled out.
- Small cystic structure visualized in the omentum – suspect a benign omental cyst.



PATIENT

Gracie Vitt

SPECIES

Canine

BREED

Labradoodle

SEX

Spayed Female

AGE

11 Years

WEIGHT

39 Pounds

INTERPRETED BY

Kathleen Sennello DVM,
MS, Diplomate ACVIM
(Small Animal Internal
Medicine)

IMAGING PERFORMED BY

Dr. Gallick

HOSPITAL NAME

Magnolia Springs VC

REFERRING VET

Dr. Gallick

INVOICE

44105

DATE

1/11/23

INTERPRETATION OF THE FINDINGS & FURTHER RECOMMENDATIONS

The liver is large, hyperechoic, and heterogeneous, with ill-defined hypoechoic nodules. The gallbladder has moderate debris but does not appear enlarged, and the wall appears relatively normal. These findings are most consistent with a primary hepatopathy. Liver enzymes were not reported, so it is unknown if this is a primary ALP or ALT elevation, as this would affect recommendations. Consider a liver function test and a fine needle aspirate of the liver (provided coagulation parameters are normal).

There is a hyperechoic nodule in the cranial pole of the left adrenal gland. This could be an incidental finding, a benign lesion, an early cancerous lesion, and could be secretory or non-active. These are considerations for further evaluation of an adrenal nodule.

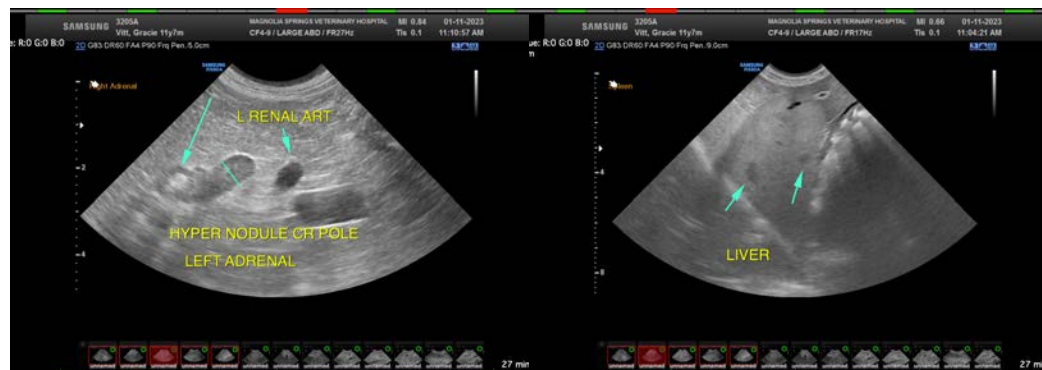- If signs of cushings are present, consider adrenal function testing. I prefer an ACTH stimulation test combined with an adrenal panel to the University of Tennessee's endocrine lab to look for atypical adrenal hormones as well as cortisol. (other testing can suffice)
- If adrenal dependent cushings is suspected and supported by adrenal function testing consider medical therapy with lysodren or trilostane or consider surgical removal (recommend referral to a board certified veterinary surgeon and possible pre op CT)
- Recommend blood pressure evaluation-if hypertensive consider testing catecholamine levels for a possible pheochromocytoma.
- If no symptoms of cushings are present, consider either referral for surgery or continued monitoring with ultrasound (in 3-4 months).
- Many of these nodules can be benign and incidental in nature, unfortunately that is difficult to determine with a single ultrasound.

If the liver enzymes are primarily an ALP elevations and symptoms are present, you could consider screening for Cushing's.

There is mild mucosal fogging visualized. The significance of this is unclear. If this patient has a history of underlying small intestinal disease, further evaluation could be considered.

Additionally, there is a small cystic structure visualized in the omentum. This is likely a benign omental cyst but continued monitoring is warranted.

Recommend three view thoracic radiographs to evaluate for possible concurrent thoracic disease/involvement.





PATIENT

Gracie Vitt

SPECIES

Canine

BREED

Labradoodle

SEX

Spayed Female

AGE

11 Years

WEIGHT

39 Pounds

INTERPRETED BY

Kathleen Sennello DVM,
MS, Diplomate ACVIM
(Small Animal Internal
Medicine)

**IMAGING
PERFORMED BY**

Dr. Gallick

HOSPITAL NAME

Magnolia Springs VC

REFERRING VET

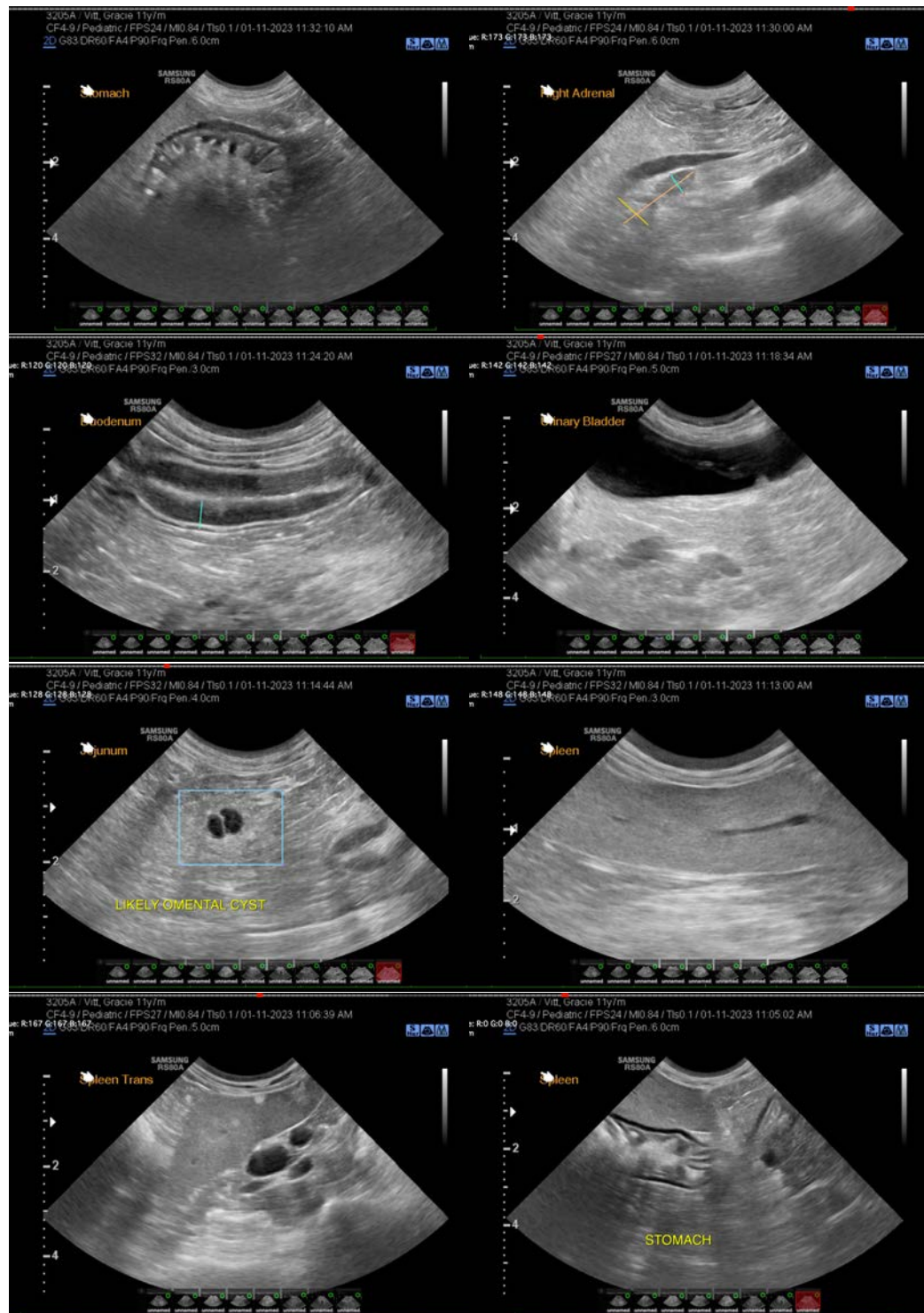
Dr. Gallick

INVOICE

44105

DATE

1/11/23





PATIENT

Gracie Vitt

SPECIES

Canine

BREED

Labradoodle

SEX

Spayed Female

AGE

11 Years

WEIGHT

39 Pounds

INTERPRETED BY

Kathleen Sennello DVM,
MS, Diplomate ACVIM
(Small Animal Internal
Medicine)

**IMAGING
PERFORMED BY**

Dr. Gallick

HOSPITAL NAME

Magnolia Springs VC

REFERRING VET

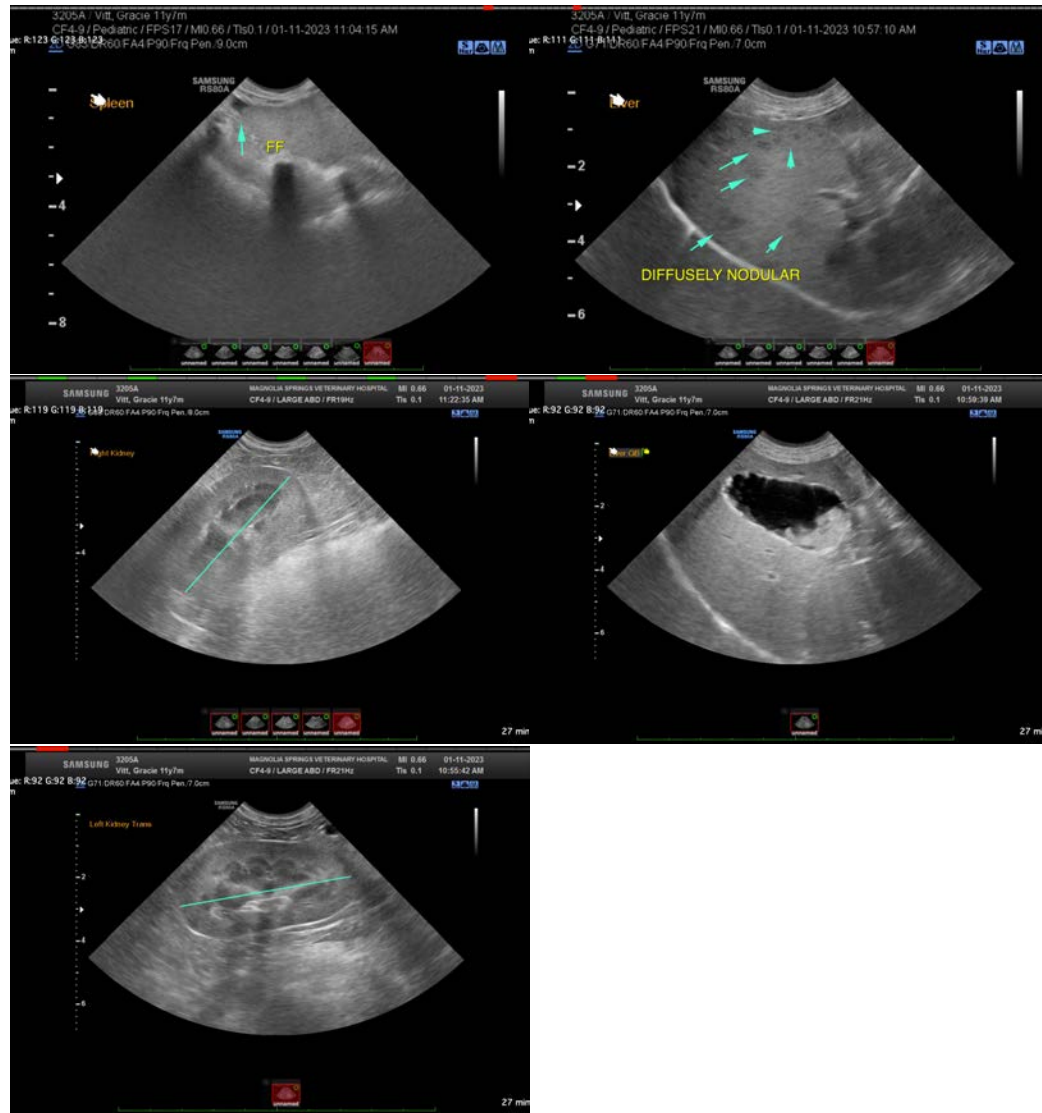
Dr. Gallick

INVOICE

44105

DATE

1/11/23



The information and recommendations provided are based on the images presented by the referring veterinarian/sonographer. No evaluation can be communicated regarding pathology that was not visible in the image/video clips provided.

Thank you for this referral. If the clinical or image interpretation does not parallel your findings or if I can be of any further assistance please contact me.

Kathleen Sennello DVM,MS, Diplomate ACVIM (Small animal Internal Medicine)

kathleen.sennello@sonopath.com