



PATIENT PRESENTING CLINICAL SIGNS

Beanz Prosser

Acute onset of vomiting and diarrhea. Hypersalivation and very tense abdomen. Started IVF, Cerenia, Pantoprazole, Metronidazole, Ampicillin and Methadone.

SPECIES

Canine

Abnormal PE/Chem/CBC/UA Results: CBC moderate lymphopenia, mild elevation MPV, mild elevation Amylase, Marked elevation of Lipase, no SNAP cPL available in clinic.

BREED

Terrier X

ULTRASONOGRAPHIC EXAMINATION OF THE ABDOMEN

Urinary System

The urinary bladder is moderately distended with anechoic urine. The Bladder wall, trigone, ureteral papillae and visible urethra (to a depth of 2cm) appear normal with no evidence of wall thickening, mucosal irregularities, masses or cystic calculi.

SEX

Neutered Male

The visualized areas of prostate and surrounding tissue appear normal. Unfortunately, the prostate is not fully visualized likely due to its intrapelvic location. Correlate with rectal exam findings.

AGE

3.5 Years

The left kidney has a normal shape and size (4.42 cm). Overall echogenicity is normal with adequate corticomedullary distinction and a typical 1:3 cortex:medulla ratio. There is no evidence of focal perinephric inflammation or effusion. There is no evidence of pyelectasia, nephroliths, infarcts or hydroureter. Renal vasculature is normal.

WEIGHT

8.5 kg

The right kidney has a normal shape and size (5.11 cm). Overall echogenicity is normal with adequate corticomedullary distinction and a typical 1:3 cortex:medulla ratio. There is no evidence of focal perinephric inflammation or effusion. There is no evidence of pyelectasia, nephroliths, infarcts or hydroureter. Renal vasculature is normal.

INTERPRETED BY

Kathleen Sennello DVM,
MS, Diplomate ACVIM
(Small Animal Internal
Medicine)

Adrenal Glands

The left adrenal gland is normal in size measuring 0.49 cm at the caudal pole. It is observed in its normal position cranial to the left renal artery. It is normal in appearance (uniformly hypoechoic) and shape with no evidence of a mass effect.

IMAGING PERFORMED BY

Crystal Hill

The right adrenal gland is normal in size measuring 0.70 cm at the caudal pole. It is observed in its normal position between the cranial aspect of the right kidney and the caudal vena cava. It is normal in appearance (uniformly hypoechoic) and shape with no evidence of a mass effect.

HOSPITAL NAME

Hamilton Region
Emergency Clinic

Spleen

The spleen is subjectively normal in size, echotexture is homogenous, and the splenic capsule is smooth with no irregularities. The blood flow through the hilus and splenic parenchyma appears normal. No focal parenchymal abnormalities are visualized.

REFERRING VET

Dr. Grewal

Liver

The liver is normal/borderline small, and normal in echogenicity with smooth peripheral margins. The parenchyma is homogenous echotexture. The visible portions of the vasculature and biliary tract appear normal. No focal nodules or cystic lesions are observed.

INVOICE

44093

The gallbladder lumen is moderately distended. The wall of the gall bladder is not thickened and has a smooth mucosal surface. Luminal contents are mild and primarily anechoic. The cystic and common bile ducts are normal/not visible.

DATE

1/11/23


PATIENT

Beanz Prosser

SPECIES

Canine

BREED

Terrier X

SEX

Neutered Male

AGE

3.5 Years

WEIGHT

8.5 kg

INTERPRETED BY

 Kathleen Sennello DVM,
 MS, Diplomate ACVIM
 (Small Animal Internal
 Medicine)

**IMAGING
 PERFORMED BY**

Crystal Hill

HOSPITAL NAME

 Hamilton Region
 Emergency Clinic

REFERRING VET

Dr. Grewal

INVOICE

44093

DATE

1/11/23

Gastrointestinal

The stomach contains minimal luminal contents. It measures at a normal thickness of <0.7cm with some variability due to the presence of rugal folds. The distinction of the gastric wall layers is adequate and there is no impression of reduced peristaltic activity. No masses or focal lesions were observed.

The visualized areas of jejunum and ileum have a relatively uniform diameter with minimal fluid distension. Wall thickness is normal. Bowel loops follow a curvilinear path with distinct wall layering maintaining the typical 1:3 muscularis:mucosa layer ratio. Duodenum wall measures 0.40 cm. Jejunum wall measures 0.80 cm. Visualized peristalsis appears appropriate. The proximal duodenum appears somewhat corrugated and irritated in the region associated with the pancreas, consistent with focal enteritis.

The ileocecal junction was visualized and exhibited normal intact wall layering and is subjectively of normal thickness. Sections of colon are visualized with formed fecal material and gas shadowing distally. There is no observed focal or generalized colon wall thickening or loss of layering.

Pancreas

The pancreas is large and hypoechoic to surrounding mesentery. There is no evidence of nodules or cystic lesions. There is evidence of regional mesenteric inflammation. Consistent with mild pancreatitis.

Free Abdomen

Evaluation of the peritoneal cavity did not reveal any evidence of effusion, or subjective lymphadenomegaly. The Medial iliac nodes appear normal and there was no evidence of a caudal aortic thrombus at the bifurcation. The omentum is hyperechoic in the right cranial abdomen around the pancreas.

PRIMARY FINDINGS

- Slightly prominent pancreas with surrounding hyperechoic mesentery and focal duodenitis – The pancreatic changes are most consistent with mild pancreatitis/pancreatic inflammation. Recommend fPLI testing and continued monitoring for improvement or possible development of a pancreatic abscess. Consider fine needle aspirate if not improving.

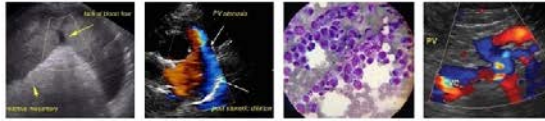
SECONDARY FINDINGS

- Subjectively small liver – This could be within normal limits for this individual. Liver function testing could be considered to rule out a portosystemic shunt.

INTERPRETATION OF THE FINDINGS & FURTHER RECOMMENDATIONS

There appears to be some inflammation and corrugation of the proximal duodenum in the region of the right limb of the pancreas. There is some mildly prominent, mottled, hypoechoic pancreas in this region, most consistent with mild pancreatitis. No other prominent gastrointestinal lesions are observed. Recommend treatment for acute pancreatitis/gastroenteritis. If the patient is not responding to treatment in an appropriate amount of time, consider repeat imaging.

The liver appears normal but is subjectively slightly small. The significance of this uncertain.



PATIENT

Beanz Prosser

SPECIES

Canine

BREED

Terrier X

SEX

Neutered Male

AGE

3.5 Years

WEIGHT

8.5 kg

INTERPRETED BY

Kathleen Sennello DVM,
MS, Diplomate ACVIM
(Small Animal Internal
Medicine)

**IMAGING
PERFORMED BY**

Crystal Hill

HOSPITAL NAME

Hamilton Region
Emergency Clinic

REFERRING VET

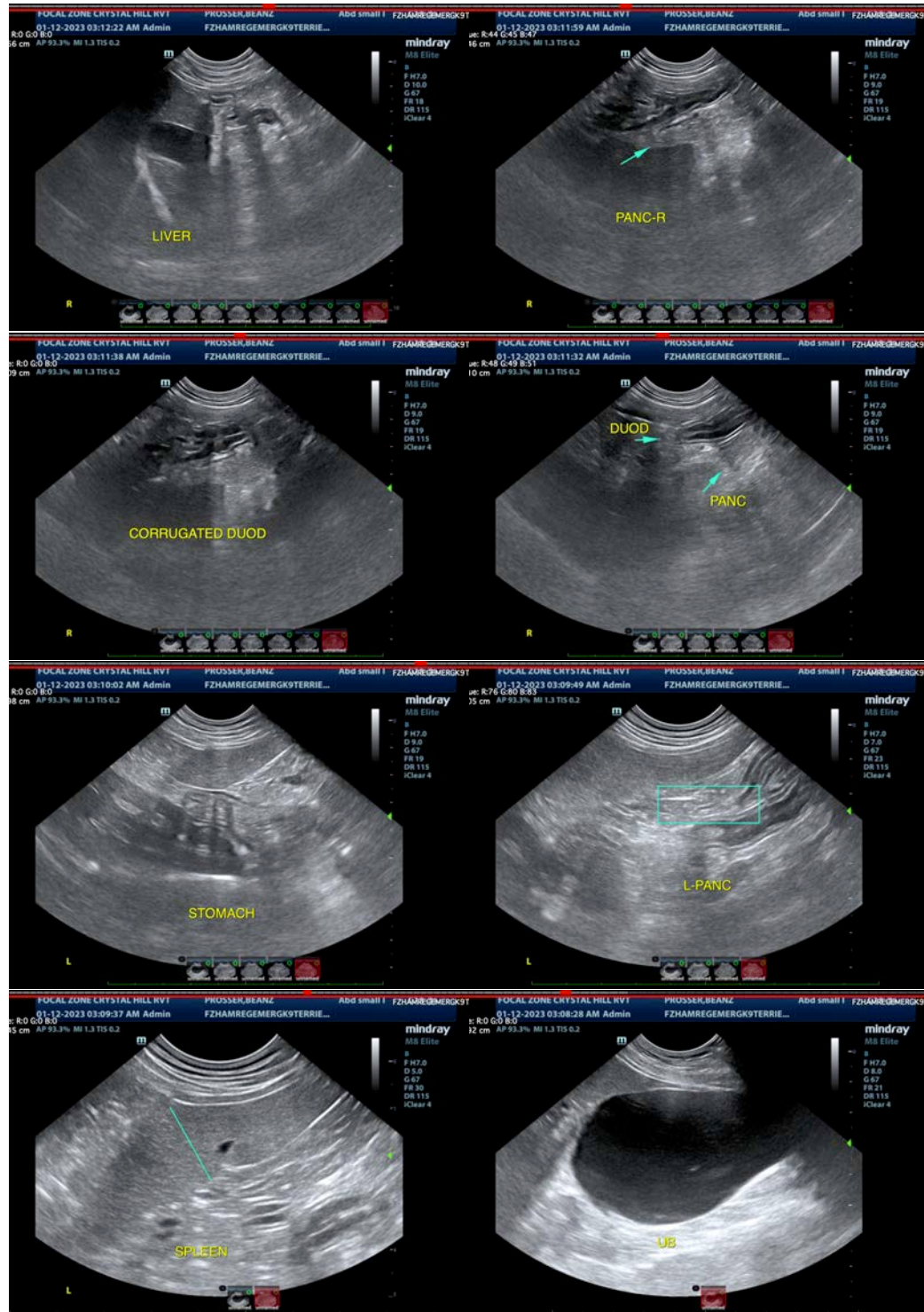
Dr. Grewal

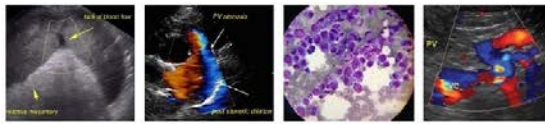
INVOICE

44093

DATE

1/11/23





PATIENT

Beanz Prosser

SPECIES

Canine

BREED

Terrier X

SEX

Neutered Male

AGE

3.5 Years

WEIGHT

8.5 kg

INTERPRETED BY

Kathleen Sennello DVM,
MS, Diplomate ACVIM
(Small Animal Internal
Medicine)

**IMAGING
PERFORMED BY**

Crystal Hill

HOSPITAL NAME

Hamilton Region
Emergency Clinic

REFERRING VET

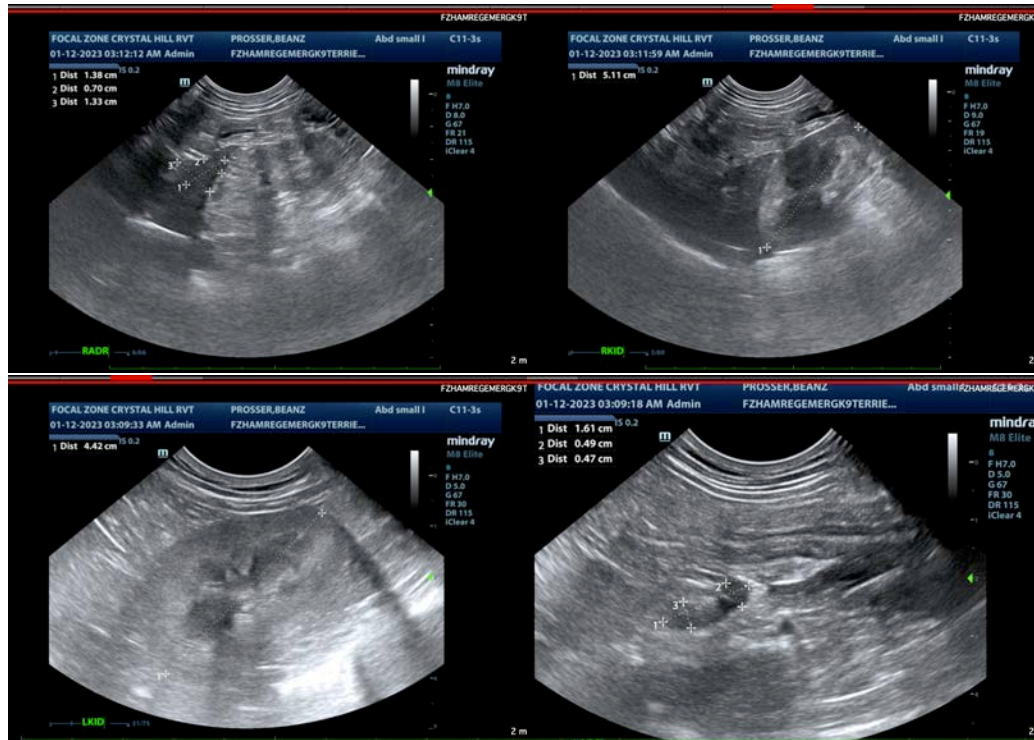
Dr. Grewal

INVOICE

44093

DATE

1/11/23



The information and recommendations provided are based on the images presented by the referring veterinarian/sonographer. No evaluation can be communicated regarding pathology that was not visible in the image/video clips provided.

Thank you for this referral. If the clinical or image interpretation does not parallel your findings or if I can be of any further assistance please contact me.

Kathleen Sennello DVM,MS, Diplomate ACVIM (Small animal Internal Medicine)

kathleen.sennello@sonopath.com