

IMAGING PERFORMED BY

IntraPet.com



SonoPath

Clinical Sonography & Telectology

EDUCATIONAL TELECONSULTATION SERVICES™

1-800-838-4268 info@sonopath.com SonoPath.com

DATE PRESENTING CLINICAL SIGNS

1/11/22 History: weight loss 11lbs in 4 months. Loss of appetite recently.

PATIENT

Riley Brooks

Lab Results: decrease Albumin 2.6, increase AST 102, increase Globulin 4.5, increase ALT 126, increase ALK P 857, increase GGTP 23. CBC- Increase Neutrophils 10,934, increase Monocytes 1136.

Date of Previous IntraPet Ultrasound: No previous IntraPet scans.

Sedation: Not required to complete full diagnostic ultrasound.

Stat Report: Not requested.

SPECIES

Canine

ULTRASONOGRAPHIC EXAMINATION OF THE ABDOMEN

BREED

Labrador Retriever

Urinary System

The urinary bladder is moderately distended with anechoic urine. The Bladder wall, trigone, ureteral papillae and visible urethra (to a depth of 2cm) appear normal with no evidence of wall thickening, mucosal irregularities, masses or cystic calculi.

SEX

Spayed Female

The left kidney has a normal shape and size (7.72 cm). Overall echogenicity is normal with adequate corticomedullary distinction and a typical 1:3 cortex:medulla ratio. There is no evidence of perinephric inflammation or effusion. There is no evidence of pyelectasia, nephroliths, infarcts or hydroureter. Renal vasculature is normal.

AGE

10/22/14

The right kidney has a normal shape and size (8.1 cm). Overall echogenicity is normal with adequate corticomedullary distinction and a typical 1:3 cortex:medulla ratio. There is no evidence of perinephric inflammation or effusion. There is no evidence of pyelectasia, nephroliths, infarcts or hydroureter. Renal vasculature is normal.

WEIGHT

62.1 Pounds

INTERPRETED BY

Kathleen Sennello DVM,
MS, Diplomate ACVIM
(Small Animal Internal
Medicine)

Adrenal Glands

The left adrenal gland is normal in size measuring 0.63 cm at the caudal pole. It is observed in its normal position cranial to the left renal artery. It is normal in appearance (uniformly hypoechoic) and shape with no evidence of a mass effect.

The right adrenal gland is normal in size measuring 0.55 cm at the caudal pole. It is observed in its normal position between the cranial aspect of the right kidney and the caudal vena cava. It is normal in appearance (uniformly hypoechoic) and shape with no evidence of a mass effect.

IMAGING PERFORMED BY

Rachel Brilhart RDMS

Spleen

The spleen is subjectively normal in size. It is heterogenous, mottled and irregular. The blood flow through the hilus and splenic parenchyma appears normal. The spleen is diffusely nodular with too numerous to count hypoechoic lesions varying in size from 0.2-1.5 cm.

HOSPITAL NAME

Bel Air Vet Hospital

Liver

The liver is large in size and irregular. The parenchyma is heterogenous in echotexture with subtle, indistinct focal mottling. The visible portions of the vasculature and biliary tract appear normal. There are too numerous to count, variably sized, hypoechoic nodules and target lesion varying in size from 0.25-2.5 cm. Additionally, there is a larger irregular isoechoic focal mass effect measuring 6.22 cm x 7.19 cm.

REFERRING VET

Dr. Schmidt

INVOICE

34114

The gallbladder lumen is moderately distended. The wall of the gall bladder is not thickened and has a smooth mucosal surface. Luminal contents are primarily anechoic. The cystic and common bile ducts are normal/not visible.

Gastrointestinal

The stomach contains minimal luminal contents. It measures at a normal thickness of <0.7cm with some variability due to the presence of rugal folds. The distinction of the gastric wall layers is adequate and there is no impression of reduced peristaltic activity. No masses or focal lesions were observed.

The visualized areas of duodenum, jejunum and ileum have a relatively uniform diameter with minimal fluid distension. Wall thickness is normal. Bowel loops follow a curvilinear path with distinct wall layering maintaining the typical 1:3 muscularis:mucosa layer ratio. The duodenum measured as normal (between 0.3-0.5cm in wall thickness) and the jejunum measured as normal (between 0.2-0.47cm.) Visualized peristalsis appears appropriate. There were no focal lesions consistent with obstruction or a mass effect observed.

The ileocecal junction was visualized and exhibited normal intact wall layering and is subjectively of normal thickness. Sections of colon are visualized with formed fecal material and gas shadowing distally. There is no observed focal or generalized colon wall thickening or loss of layering.

Pancreas

The pancreas is normal and isoechoic to surrounding mesentery. There is no evidence of nodules or cystic lesions. There is no evidence of regional mesenteric inflammation or fluid.

Free Abdomen

There is a moderate amount of free fluid in the abdomen. No lymphadenopathy noted. The mesentery appears hyperechoic around the liver and spleen.

Other

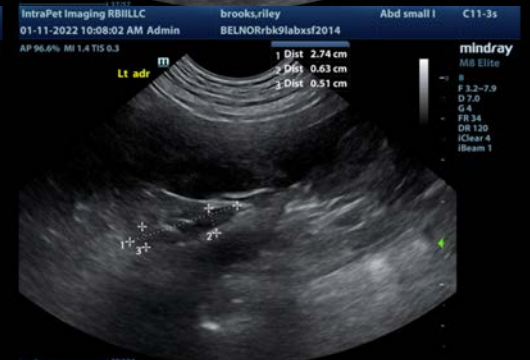
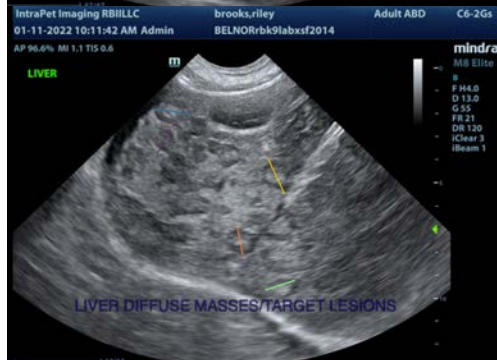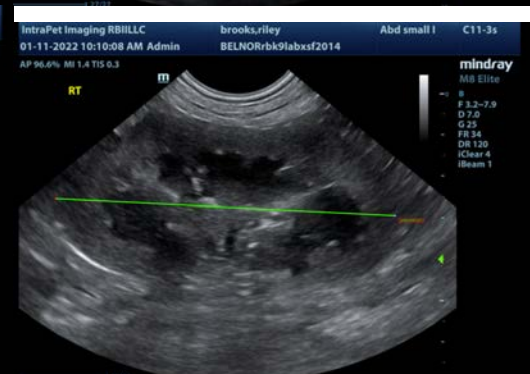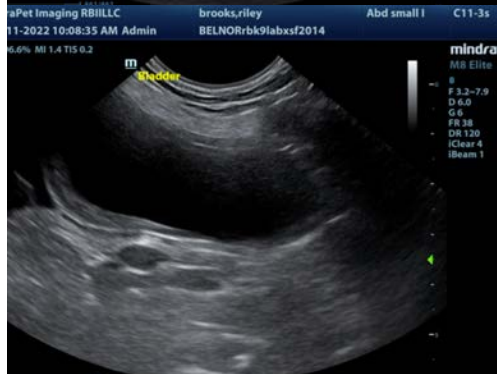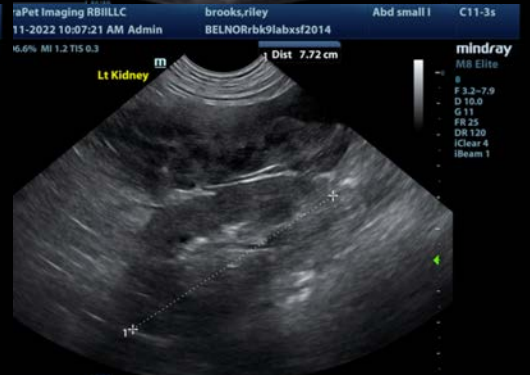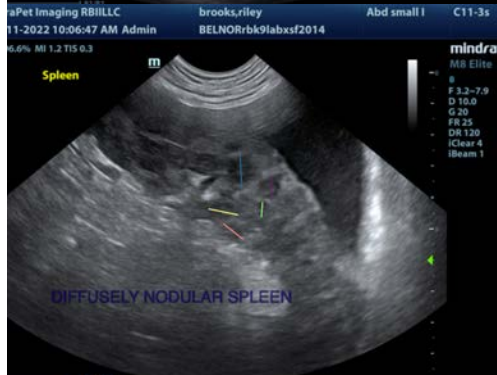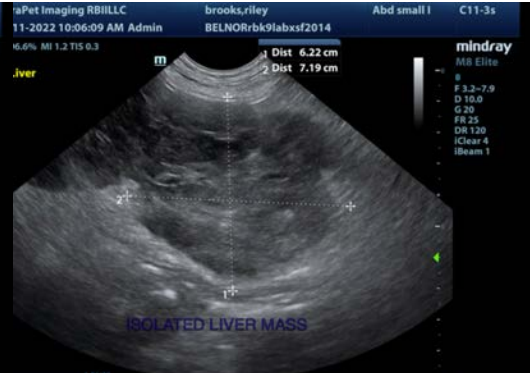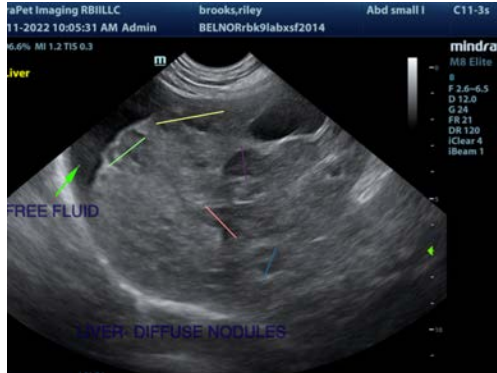A brief view of the heart was submitted. No significant pericardial effusion was seen.

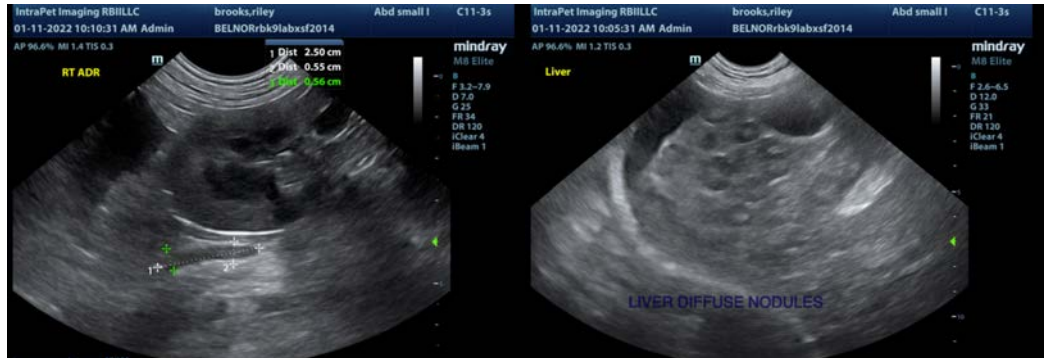ULTRASONOGRAPHIC FINDINGS

- Diffuse hypoechoic splenic nodule – The number and nature of the lesions visualized is most concerning for a metastatic neoplastic process. Benign differentials such as lymphoid hyperplasia, hematomas, abscesses, etc. exist, but are much less likely.
- Diffuse hypoechoic liver nodules with numerous target lesions – Most concerning for an underlying metastatic neoplastic process. While benign can lesions exist, no normal liver tissue is visualized.
- Free abdominal fluid – Recommend sampling, fluid analysis and cytology if appropriate. This could represent hemorrhage.

INTERPRETATION OF THE FINDINGS & FURTHER RECOMMENDATIONS

The liver and spleen are comprised of diffuse hypoechoic nodules with virtually no normal tissue visualized. These findings are very concerning for an underlying neoplastic process. Consider a fine needle aspirate of the liver and spleen and 3-view thoracic radiographs. If a cytologic diagnosis can be obtained, recommend consultation with a veterinary oncologist regarding treatment options and prognosis, as I do not suspect this is a readily surgical lesion.





The information and recommendations provided are based on the images presented by the referring veterinarian. No evaluation can be communicated regarding pathology that was not visible in the image/video clips provided.

Thank you for this referral. If the clinical or image interpretation does not parallel your findings or if I can be of any further assistance please contact me.

Kathleen Sennello DVM,MS, Diplomate ACVIM (Small animal Internal Medicine)
kathleen.sennello@sonopath.com