

**DATE**

1/11/22

**PRESENTING CLINICAL SIGNS**

History: Presents for vomiting/diarrhea. On radiographs liver looks large, questionable abdominal mass. Liver values high on lab work.

Current Medications: Cerenia, Omeprazole.

**PATIENT**

Date of Previous IntraPet Ultrasound: No previous IntraPet scans.

Sedation: Not required to complete full diagnostic ultrasound.

Bailey Lotz

Stat Report: Not requested.

Imaging Performed By: Rachel Brillhart, RDMS.

**SPECIES**

Canine

**ULTRASONOGRAPHIC EXAMINATION OF THE ABDOMEN****Urinary System****BREED**

The urinary bladder is moderately distended with anechoic urine. The Bladder wall, trigone, ureteral papillae and visible urethra (to a depth of 2cm) appear normal with no evidence of wall thickening, mucosal irregularities, masses or cystic calculi.

Mix

**SEX**

Spayed Female

The left kidney has a normal shape and size (6.12 cm). Overall echogenicity is slightly hyperechoic with poor corticomedullary distinction and a typical 1:3 cortex:medulla ratio. There is no evidence of perinephric inflammation or effusion. There is no evidence of pyelectasia, nephroliths, infarcts or hydroureter. Renal vasculature is normal.

**AGE**

2/8/07

The right kidney has a normal shape and size (5.82 cm). Overall echogenicity is slightly hyperechoic with poor corticomedullary distinction and a typical 1:3 cortex:medulla ratio. There is no evidence of perinephric inflammation or effusion. There is no evidence of pyelectasia, nephroliths, infarcts or hydroureter. Renal vasculature is normal.

**WEIGHT**

61.1 lbs

**Adrenal Glands****INTERPRETED BY**

The left adrenal gland is normal in size measuring 0.87 cm at the caudal pole It is observed in its normal position cranial to the left renal artery. It is normal in appearance (uniformly hypoechoic) and shape with no evidence of a mass effect.

The right adrenal gland is slightly enlarged in size and somewhat irregular measuring 1.27 cm at the cranial pole and 0.96 cm at the caudal pole and 2.25 cm in length. It is observed in its normal position between the cranial aspect of the right kidney and the caudal vena cava. It is somewhat irregular in that the cranial pole has an ill-defined, hyperechoic area that measured 1.12 x 1.12 cm. This is most consistent with focal mottling or an ill-defined, cranial adrenal nodule.

Kathleen Sennello  
DVM, MS, Diplomate  
ACVIM (Small Animal  
Internal Medicine)

**HOSPITAL NAME**

Homeward Bound VS

**Spleen****REFERRING VET**

The spleen is subjectively normal in size, echotexture is homogenous, and the splenic capsule is smooth with no irregularities. The blood flow through the hilus and splenic parenchyma appears normal. No focal parenchymal abnormalities are visualized.

Dr. Vance

**INVOICE**

95125

**Liver**

The liver is subjectively large in size, and echogenicity with smooth peripheral margins. The parenchyma is heterogenous in echotexture with subtle, indistinct focal mottling. The visible portions of the vasculature and biliary tract appear normal. There is large, somewhat rounded, ill-defined mass effect in the right side of the liver. This is most consistent with an atypical rounded liver lobe or a primary hepatic mass. This measured 9.99 x 6.62 cm. The gallbladder lumen is moderately distended. The wall of the gallbladder is not thickened and has a smooth mucosal surface. There is a moderate amount of non-organized echogenic debris. The cystic and common bile ducts are normal/not visible.

### ***Gastrointestinal***

The stomach contains minimal luminal contents. It measures at a normal thickness of <0.7cm with some variability due to the presence of rugal folds. The distinction of the gastric wall layers is adequate and there is no impression of reduced peristaltic activity. No masses or focal lesions were observed.

The visualized areas of duodenum, jejunum and ileum have a relatively uniform diameter with minimal fluid distension. Wall thickness is normal. Bowel loops follow a curvilinear path with distinct wall layering maintaining the typical 1:3 muscularis:mucosa layer ratio. The duodenum measured as normal (between 0.3-0.5cm in wall thickness) and the jejunum measured as normal (between 0.2-0.47cm.) Visualized peristalsis appears appropriate. There were no focal lesions consistent with obstruction or a mass effect observed.

The ileocecal junction was visualized and exhibited normal intact wall layering and is subjectively of normal thickness. Sections of colon are visualized with formed fecal material and gas shadowing distally. There is no observed focal or generalized colon wall thickening or loss of layering.

### ***Pancreas***

The pancreas is prominent and mottled compared to the surrounding isoechoic mesentery. There is no evidence of nodules or cystic lesions. There is no evidence of regional mesenteric inflammation or fluid.

### ***Free Abdomen***

Evaluation of the peritoneal cavity did not reveal any evidence of effusion, or subjective lymphadenomegaly. The Medial iliac nodes appear normal and there was no evidence of a caudal aortic thrombus at the bifurcation. The omentum is of normal uniform echogenicity.

## **ULTRASONOGRAPHIC FINDINGS**

### **PRIMARY FINDINGS:**

- Mottled, prominent pancreas. The pancreatic changes are most consistent with mild pancreatitis or a recent episode of pancreatic inflammation.
- Large heterogenous liver with ill-defined mass effect in the right side. This lesion could represent a rounded, irregular liver lobe or a primary hepatic mass.
- Moderate gallbladder debris. The significance of the aggregated gallbladder debris is unclear. This could represent an early mucocele, cholestasis, or may be secondary to fasting.
- Irregularity in the right adrenal gland. Right adrenomegaly could be consistent with neoplasia (e.g., adenoma, carcinoma, pheochromocytoma), hyperplasia, inflammation, other. This lesion is somewhat benign in appearance, but should be monitored closely.

### **SECONDARY FINDINGS:**

- Decreased corticomedullary distinction in both kidneys. Mild loss of corticomedullary distinction in both kidneys could be consistent with chronic degenerative disease or interstitial nephrosis.

## **INTERPRETATION OF THE FINDINGS & FURTHER RECOMMENDATIONS**

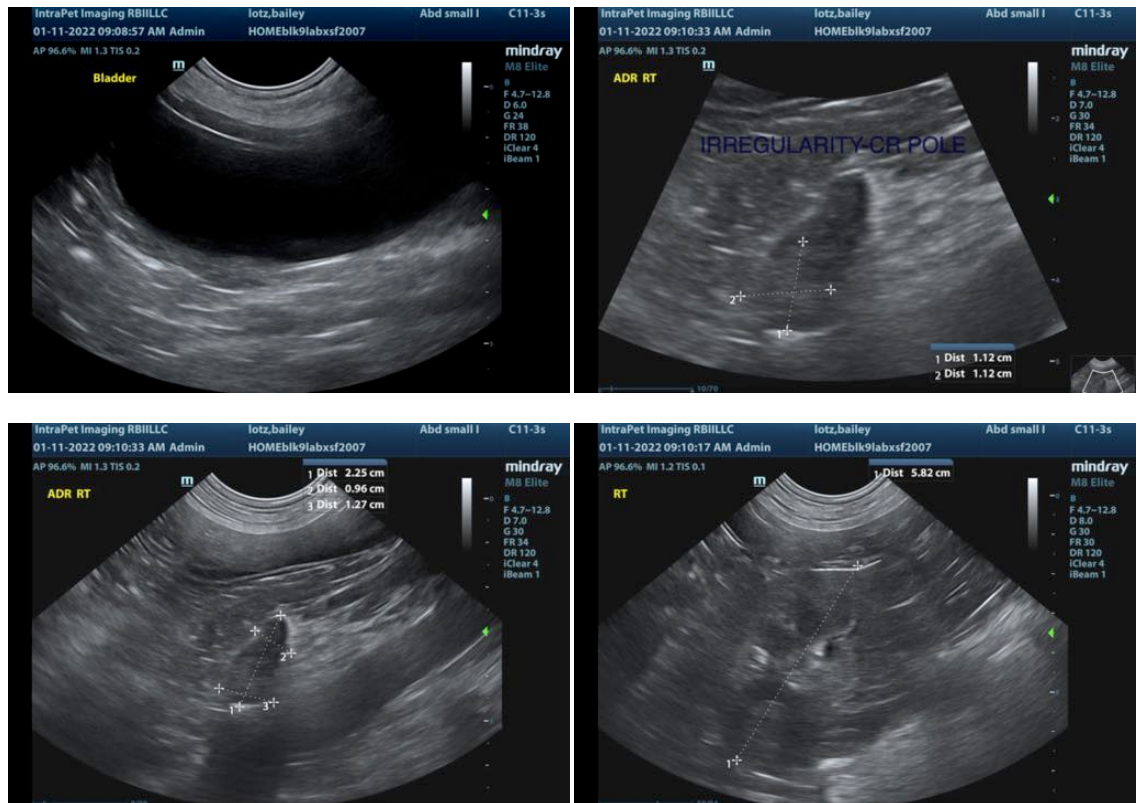
There are some significant findings on today's scan, but it is unclear if these are actually related to the symptoms of vomiting and diarrhea described. The liver is somewhat large with an ill-defined, hyperechoic

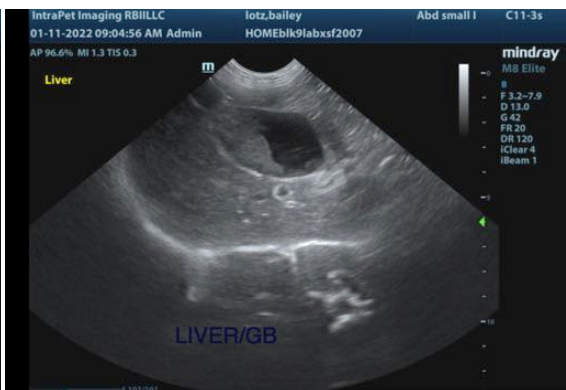
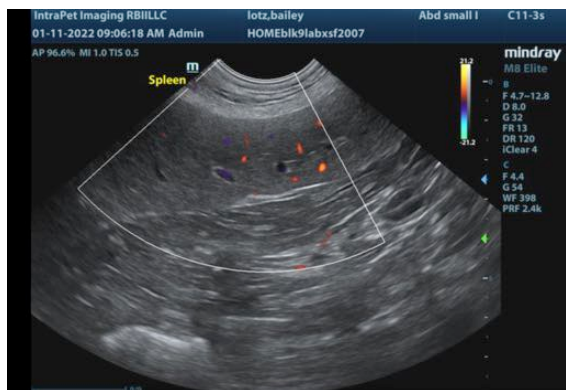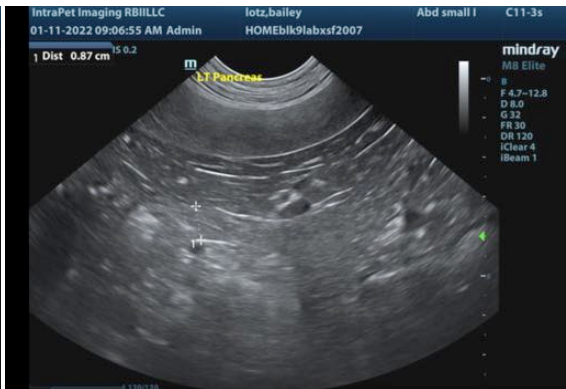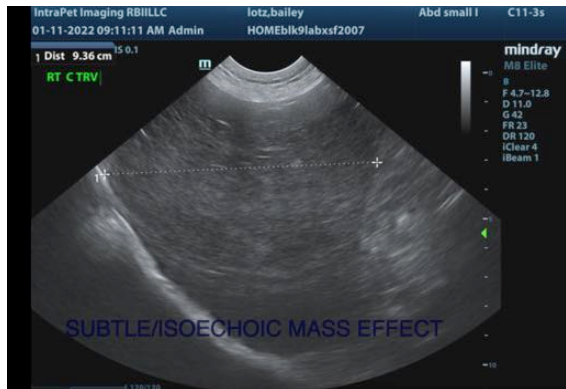
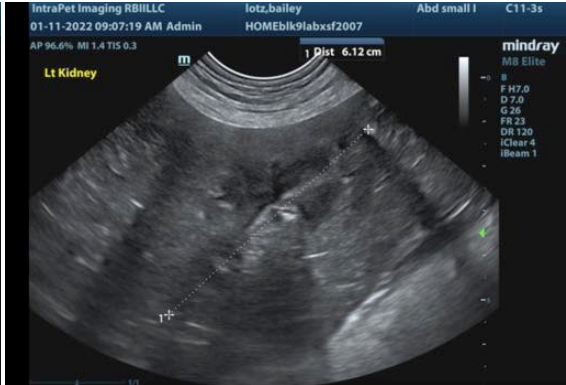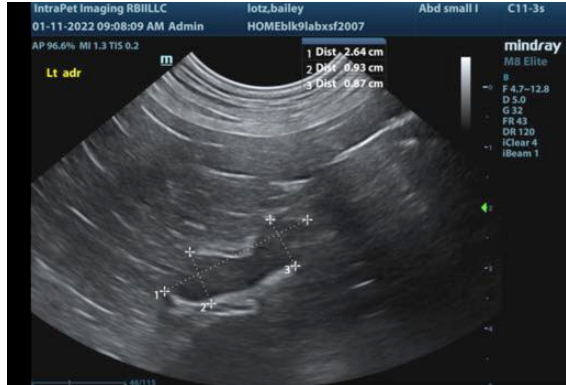area in the right lobe. This could represent a benign, rounded atypical liver lobe or could be a large mass effect. Options moving forward include a FNA of the right side of the liver or contrast CT scan to further evaluate this area. Even if this is a true mass effect this may represent a large, slow growing hepatic mass.

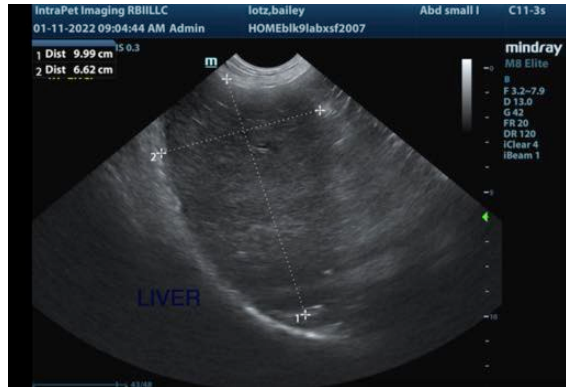Additionally there is an irregular area on the cranial pole of the right adrenal gland. The significance of this is unclear as it does not look like a distinct mass effect. If signs of Cushing's are present you can consider adrenal function testing, measuring a blood pressure and continue monitoring this area with ultrasound as occasionally adrenal masses can change rapidly.

An obvious cause for the vomiting and diarrhea is not visualized. The pancreas is somewhat prominent. Consider a GI panel (Texas A&M) for a qualitative PLI, TLI, cobalamin and folate to further evaluate the pancreas and small intestine.

- Recommend supportive care for acute gastroenteritis.
- Recommend probiotic therapy.
- Recommend symptomatic treatment for pancreatic inflammation.
- Consider a bland diet.
- If symptoms persist consider reimaging (including abdominal radiographs) or you can consider a CT scan to further evaluate the abnormal liver and right adrenal gland.







The information and recommendations provided are based on the images presented by the referring veterinarian. No evaluation can be communicated regarding pathology that was not visible in the image/video clips provided.

Thank you for this referral. If the clinical or image interpretation does not parallel your findings or if I can be of any further assistance please contact me.

Kathleen Sennello DVM,MS, Diplomate ACVIM (Small animal Internal Medicine)  
kathleen.sennello@sonopath.com