



## PATIENT

Moxie Cleveland

## SPECIES

Feline

## BREED

Domestic Shorthair

## SEX

Neutered male

## AGE

6 ½ years

## WEIGHT

9.3 lbs

## INTERPRETED BY

Kim Radway, DVM,  
DABVP (Canine/  
Feline)

## IMAGING PERFORMED BY

Dr. Pfannenstiel

## HOSPITAL NAME

Mill Brook Animal  
Clinic VBF

## REFERRING VET

Dr. Pfannenstiel

## INVOICE

71872

## DATE

2/24/26

## PRESENTING CLINICAL SIGNS

- Came in for wellness and urine showed changes. O thinks there are litterbox changes of pollakiuria
- Urinalysis cysto: Findings included an alkaline pH of 9.0 (reference 6.0-7.5), 2+ proteinuria, 2+ blood, 10-15 red blood cells/HPF, and 1+ ammonium magnesium phosphate (struvite) crystals. The urine specific gravity was 1.040.

## ULTRASONOGRAPHIC EXAMINATION OF THE ABDOMEN

### Urinary System

The **urinary bladder**, trigone and pelvic urethra presented with normal wall thicknesses. The urine had an anechoic background, but contained a small amount of hyperechoic, non-shadowing gravity dependent cellular material within the lumen of the bladder. No uroliths or masses were noted in the lumen of the bladder. No evidence of inflammatory or neoplastic changes were noted. The ureters were not visible and considered normal.

The **kidneys** revealed normal size, corticomedullary definition and ratio with the cortex being 1/3 of medulla. Medullary echogenicity differed distinctly from that of the cortex and no evidence of dilation could be seen. The renal pelvic diverticuli were distinct in character. The capsules were acceptably uniform without dramatic irregularities. The left kidney was 3.64 cm and the right kidney was 3.9 cm in length.

### Adrenal Glands

The regions of the **adrenal glands** were evaluated and found no evidence of abnormal pathology; however, the adrenal glands were not imaged in this study.

### Spleen

The **spleen** presented with a smooth homogeneous parenchyma hyperechoic to liver and kidney. The capsule was smooth and linear in its contour. The splenic vasculature demonstrated normal volume without signs of congestion, significant contraction, or thrombosis.

### Liver

The **liver** revealed normal size, contour, and structure. Parenchymal echogenicity was smooth and homogenous in appearance. Vascular and biliary tracts were of normal volume and no evidence of congestion was noted. The gallbladder presented with anechoic contents and a thin hyperechoic wall. The cystic and common bile ducts were normal. No periportal lymphadenopathy was evident.



**PATIENT**

Moxie Cleveland

**SPECIES**

Feline

**BREED**

Domestic Shorthair

**SEX**

Neutered male

**AGE**

6 ½ years

**WEIGHT**

9.3 lbs

**INTERPRETED BY**

Kim Radway, DVM,  
DABVP (Canine/  
Feline)

**IMAGING PERFORMED BY**

Dr. Pfannenstiel

**HOSPITAL NAME**

Mill Brook Animal  
Clinic VBF

**REFERRING VET**

Dr. Pfannenstiel

**INVOICE**

71872

**DATE**

2/24/26

**Gastrointestinal**

The **gastrointestinal tract** revealed a stomach and intestine free of stasis, of normal wall thickness, acceptable curvilinear mural detail, and peristaltic activity. There was a small amount of gas in the lumen of the stomach. No obstructive or overt infiltrative disease was noted. There was a large amount of hyperechoic, distal shadowing stool within the lumen of the colon. No abnormal lymphatic activity was noted and the abdomen was free of gastrointestinal masses and pathological fluid.

**Pancreas**

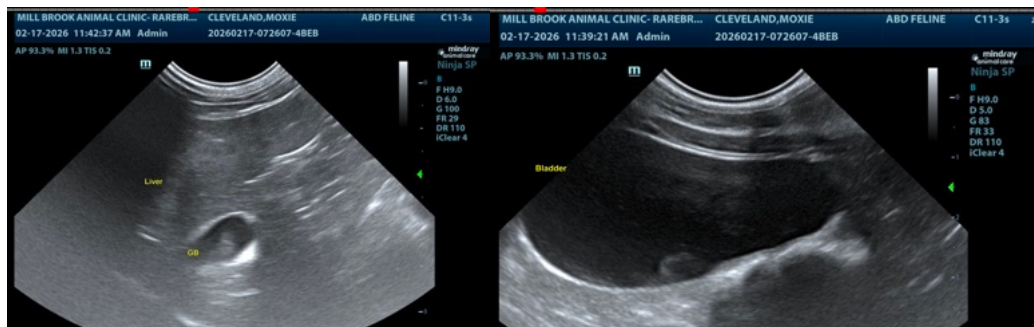
The right and left limbs of the **pancreas** were observed to be largely isoechoic to surrounding omental fat. Pancreatic capsular contour were acceptably normal. No overt evidence of active inflammatory or neoplastic disease was noted.

**ULTRASONOGRAPHIC FINDINGS**

Small amount of hyperechoic, non-shadowing, gravity dependent cellular material within the lumen of the bladder.

**INTERPRETATION OF THE FINDINGS & FURTHER RECOMMENDATIONS**

This patient did not have evidence of discrete uroliths or masses within the bladder to explain the recent pollakiuria or abnormal changes on the urinalysis. It is recommended to obtain a cystocentesis urine sample for urine culture. A urinary diet should be considered with encouraging increased water consumption. This can be accomplished by providing a cat drinking fountain, adding water to the food and feeding canned food over dry food. Any treatment of an underlying urinary tract infection should be based upon the urine culture results.





**PATIENT**

Moxie Cleveland

**SPECIES**

Feline

**BREED**

Domestic Shorthair

**SEX**

Neutered male

**AGE**

6 ½ years

**WEIGHT**

9.3 lbs

**INTERPRETED BY**

Kim Radway, DVM,  
DABVP (Canine/  
Feline)

**IMAGING  
PERFORMED BY**

Dr. Pfannenstiel

**HOSPITAL NAME**

Mill Brook Animal  
Clinic VBF

**REFERRING VET**

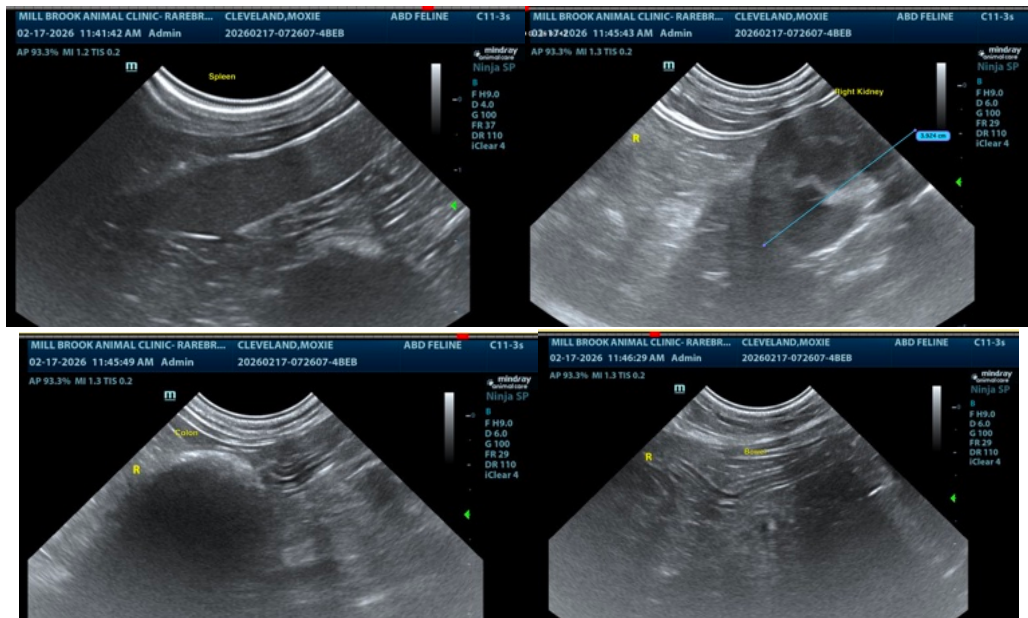
Dr. Pfannenstiel

**INVOICE**

71872

**DATE**

2/24/26



The information and recommendations provided are based on the images presented by the referring veterinarian/sonographer. No evaluation can be communicated regarding pathology that was not visible in the image/video clips provided.

Thank you for this referral. If the clinical or image interpretation does not parallel your findings or if I can be of any further assistance please contact me.

Kim Radway, DVM, DABVP (Canine/ Feline)

MV Esp Ultrasound in Domestic and Wild Animals

[info@SonoPath.com](mailto:info@SonoPath.com)