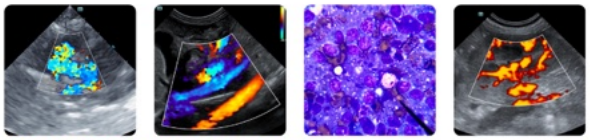

PATIENT
Hippie Li

SPECIES
Feline

BREED
Domesti Shorthair

SEX
Spayed female

AGE
10 years

WEIGHT
7.6 lbs

INTERPRETED BY
Kim Radway, DVM, DABVP (Canine/ Feline)

IMAGING PERFORMED BY
Adrienne Hou

HOSPITAL NAME
Marina Village Veterinary & Integrative Care

REFERRING VET
Dr. Hou

INVOICE
71093

DATE
1/29/26

PRESENTING CLINICAL SIGNS

- History of chronic urine leakage on the bed when she's sleeping- progressed from 1-2 times a year to every few days. Small volume. Normal urination otherwise- no straining, no dribbling when awake.
- November 2025: Unremarkable abdominal radiograph; no spinal lesions. Unremarkable CBC/chem/urinalysis. USG=1.055 with RBC 21-50/hpf and struvites 2-3/hpf on cysto sample.

ULTRASONOGRAPHIC EXAMINATION OF THE ABDOMEN

Urinary System

The **urinary bladder**, trigone and pelvic urethra presented with normal wall thicknesses with anechoic urine and normal tone. High quality images obtained with a linear probe were provided of the urinary bladder and pelvic urethra. There was no evidence of stones or masses present. No evidence of inflammatory or neoplastic changes were noted. The ureters were not dilated, which would be expected for an ectopic ureter.

The **kidneys** revealed normal size, corticomedullary definition and ratio with the cortex being 1/3 of medulla. Medullary echogenicity differed distinctly from that of the cortex and no evidence or dilation could be seen. The renal pelvic diverticuli were distinct in character. The capsules were acceptably uniform without dramatic irregularities. The left kidney was 3.9 cm and the right kidney was 4.0 cm in length.

Adrenal Glands

The region of the left **adrenal gland** was evaluated, but not specifically identified. The right adrenal gland was visualized and recognized as having normal shape, size, position and echogenicity for this breed. The phrenic vasculature, glandular echogenicity and detail were acceptable. The right adrenal gland was 0.74 cm by 0.48 cm in size.

Spleen

The **spleen** presented with a smooth homogeneous parenchyma hyperechoic to liver and kidney. The capsule was smooth and linear in its contour. The splenic vasculature demonstrated normal volume without signs of congestion, significant contraction, or thrombosis.

Liver

The **liver** revealed normal size, contour, and structure. Parenchymal echogenicity was smooth and homogenous in appearance. Vascular and biliary tracts were of normal volume and no evidence of congestion was noted. The gallbladder presented with anechoic contents and a thin hyperechoic wall. The cystic and common bile ducts were normal. No periportal lymphadenopathy was evident.

PATIENT
Hippie Li

SPECIES
Feline

BREED
Domesti Shorthair

SEX
Spayed female

AGE
10 years

WEIGHT
7.6 lbs

INTERPRETED BY
Kim Radway, DVM, DABVP (Canine/ Feline)

IMAGING PERFORMED BY
Adrienne Hou

HOSPITAL NAME
Marina Village Veterinary & Integrative Care

REFERRING VET
Dr. Hou

INVOICE
71093

DATE
1/29/26

Gastrointestinal

The **gastrointestinal tract** revealed a stomach and intestine free of stasis, of normal wall thickness, acceptable curvilinear mural detail, and peristaltic activity. There was a small amount of gas in the lumen of the stomach. No obstructive or overt infiltrative disease was noted. No abnormal lymphatic activity was noted and the abdomen was free of gastrointestinal masses and pathological fluid.

Pancreas

The right and left limbs of the **pancreas** were observed to be largely isoechoic to surrounding omental fat. Pancreatic capsular contour were acceptably normal. No overt evidence of active inflammatory or neoplastic disease was noted.

ULTRASONOGRAPHIC FINDINGS

Normal abdomen.

INTERPRETATION OF THE FINDINGS & FURTHER RECOMMENDATIONS

This was a normal abdomen with no evidence of underlying gross pathology that would be expected to lead to urinary incontinence or inappropriate urination.

It is recommended to evaluate this patient's environment closely for any evidence of stress that may be able to be addressed to decrease any inappropriate urination.

Since the urinary accidents are historically happening during sleep or rest, additional diagnostics including a thyroid level and systemic blood pressure measurements should be considered. If this patient continues to have abnormal urination, then referral for cystoscopy or a urethrocystogram can be considered.

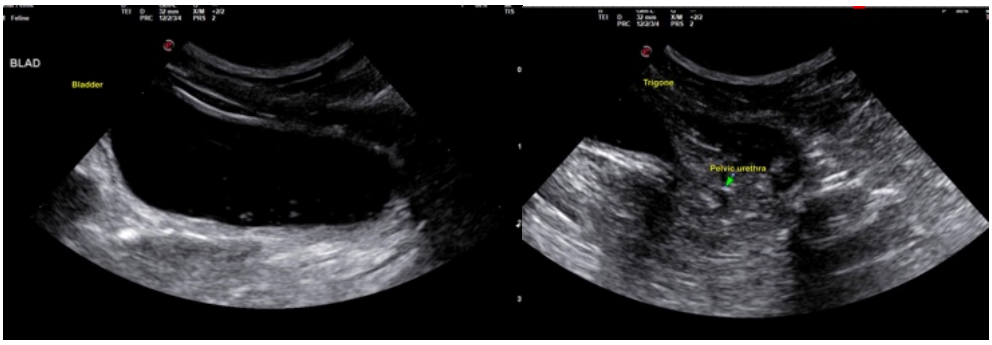

SonoPath

FOSTERING THE ART OF VETERINARY MEDICINE™

SonoPath.com info@sonopath.com 1.800.838.4268

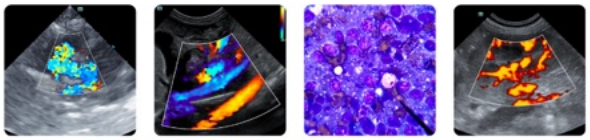

Clinical Sonography & Telecytology

Educational Teleconsultation Services™

PATIENT

Hippie Li

SPECIES

Feline

BREED

Domesti Shorthair

SEX

Spayed female

AGE

10 years

WEIGHT

7.6 lbs

INTERPRETED BY

Kim Radway, DVM, DABVP (Canine/ Feline)

IMAGING PERFORMED BY

Adrienne Hou

HOSPITAL NAME

Marina Village Veterinary & Integrative Care

REFERRING VET

Dr. Hou

INVOICE

71093

DATE

1/29/26

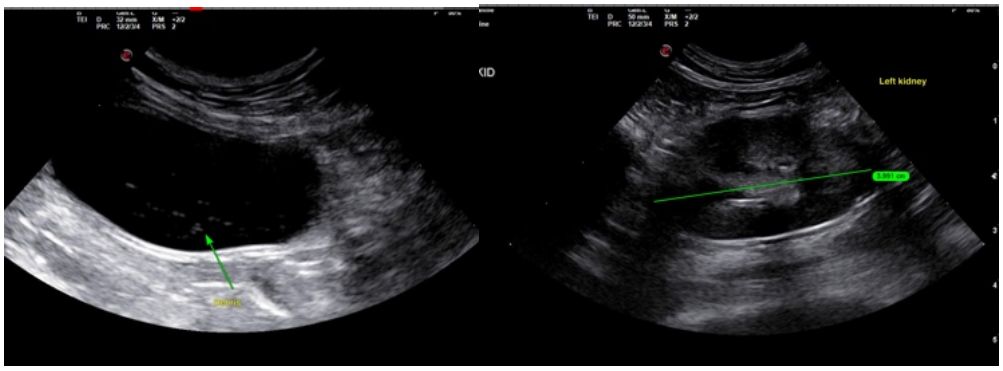

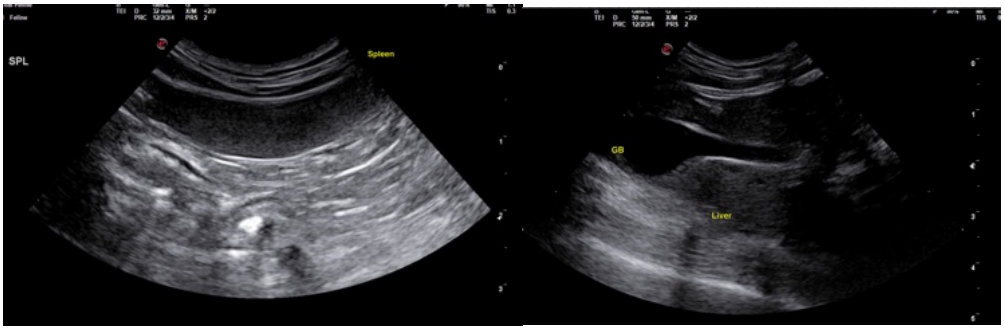

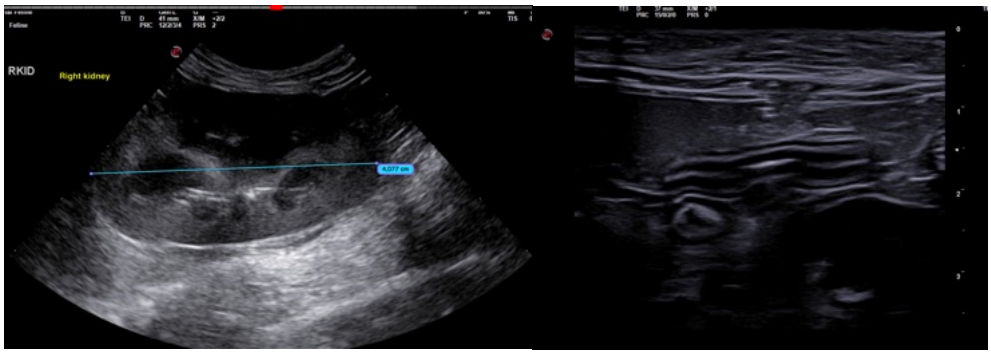

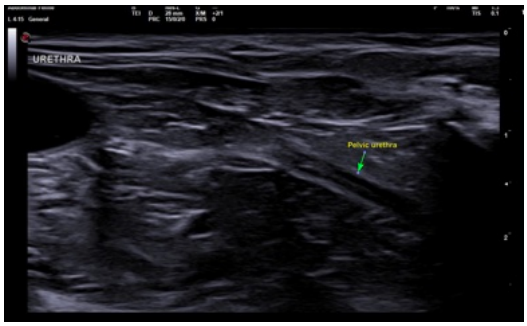

The information and recommendations provided are based on the images presented by the referring veterinarian/sonographer. No evaluation can be communicated regarding pathology that was not visible in the image/video clips provided.

Thank you for this referral. If the clinical or image interpretation does not parallel your findings or if I

PATIENT

Hippie Li

SPECIES

Feline

BREED

Domesti Shorthair

SEX

Spayed female

AGE

10 years

WEIGHT

7.6 lbs

INTERPRETED BY

Kim Radway, DVM, DABVP (Canine/ Feline)

IMAGING PERFORMED BY

Adrienne Hou

HOSPITAL NAME

Marina Village Veterinary & Integrative Care

REFERRING VET

Dr. Hou

INVOICE

71093

DATE

1/29/26

can be of any further assistance please contact me.

Kim Radway, DVM, DABVP (Canine/ Feline)

info@SonoPath.com