



PATIENT	PRESENTING CLINICAL SIGNS
Fynn Hodge	Presented to the ER for lethargy and ataxia. Fever of 104, lab work unremarkable. Treated with NSAID and SQF, ondansetron with minimal improved. HCT 40 but dehydrated on exam. Presented today to us for recheck; rec'd abdominal ultrasound
SPECIES	
Canine	ULTRASONOGRAPHIC EXAMINATION OF THE ABDOMEN
BREED	Urinary System
German Shepherd	The urinary bladder , trigone and pelvic urethra presented with normal wall thicknesses with anechoic urine and normal tone. No uroliths or masses were noted in the lumen of the bladder. No evidence of inflammatory or neoplastic changes were noted. The ureters were not visible and considered normal.
SEX	
Male	The kidneys revealed normal size, corticomedullary definition and ratio with the cortex being 1/3 of medulla. Medullary echogenicity differed distinctly from that of the cortex and no evidence of dilation could be seen. The renal pelvic diverticuli were distinct in character. The capsules were acceptably uniform without dramatic irregularities. The left kidney was <u>9.1 cm</u> and the right kidney was <u>9.8 cm</u> in length.
AGE	
10 years	
WEIGHT	
87 lbs	The prostate was identified and found to be hyperechoic and coarse in echogenicity. There was an overall increase in size measuring 4.32 cm in width. There were no cysts, masses or nodules present within the prostate.
INTERPRETED BY	Both testees were imaged and the right testees measured 2.36 x 4.2 cm in size. There was a single, hypoechoic nodule within the right testees that measured 1.41 x 0.76 cm in size. The left testees measured 1.99 x 4.68 and was hyperechoic and coarse in echogenicity.
Kim Radway, DVM, DABVP (Canine/ Feline)	
IMAGING PERFORMED BY	Adrenal Glands
Kimberly Morgan	The region of the left adrenal gland was evaluated and no masses were identified. However, the left adrenal gland was not specifically present within the images provided. The right adrenal gland was visualized and recognized as having normal shape, size, position and echogenicity for this breed. The phrenic vasculature, glandular echogenicity and detail were acceptable. The right adrenal gland was <u>2.06 cm by 0.81 cm by 0.62 cm</u> in size.
HOSPITAL NAME	
Seven Fields VH	
REFERRING VET	Spleen
Dr. Pearson	The spleen presented with a smooth homogeneous parenchyma hyperechoic to liver and kidney. The capsule was smooth and linear in its contour. The splenic vasculature demonstrated normal volume without signs of congestion, significant contraction, or thrombosis.
INVOICE	
71091	
DATE	Liver
1/29/26	The liver revealed normal size, contour, and structure. Parenchymal echogenicity was smooth and homogenous in appearance. Vascular and biliary tracts were of normal volume and no evidence of



PATIENT	congestion was noted. The gallbladder revealed a moderate amount of hyperechoic suspended debris within the lumen of the gallbladder. No periportal lymphadenopathy was evident.
Fynn Hodge	
SPECIES	<i>Gastrointestinal</i>
Canine	The gastrointestinal tract revealed a stomach and intestine free of stasis, of normal wall thickness, acceptable curvilinear mural detail, and peristaltic activity. There was a small amount of gas in the lumen of the stomach. No obstructive or overt infiltrative disease was noted. No abnormal lymphatic activity was noted and the abdomen was free of gastrointestinal masses and pathological fluid.
BREED	
German Shepherd	
SEX	<i>Pancreas</i>
Male	The right and left limbs of the pancreas were observed to be largely isoechoic to surrounding omental fat. Pancreatic capsular contour were acceptably normal. No overt evidence of active inflammatory or neoplastic disease was noted.
AGE	
10 years	
WEIGHT	ULTRASONOGRAPHIC FINDINGS
87 lbs	Gallbladder debris. Large prostate. Nodule in the right testes.
INTERPRETED BY	
Kim Radway, DVM, DABVP (Canine/ Feline)	
IMAGING PERFORMED BY	<u>INTERPRETATION OF THE FINDINGS & FURTHER RECOMMENDATIONS</u>
Kimberly Morgan	This was generally a normal abdomen with no evidence of discrete changes that would explain the recent lethargy, ataxia and fever. There was a moderate amount of hyperechoic debris within the lumen of the gallbladder; however, the liver enzymes were reported as being normal on recent lab work. Supportive care with Denamarin could still be considered in this patient.
HOSPITAL NAME	There was a large to hyperechoic and coarse prostate which is considered to be consistent with benign prostatic hypertrophy from being an intact male. The right testes had a single, hypoechoic nodule which is likely a benign, age related change. However, emerging testicular neoplasia cannot be completely excluded without sampling. It is recommended to consider castration in order to decrease future risk of testicular cancer and to resolve the current, benign, prostatic hypertrophy.
Seven Fields VH	
REFERRING VET	The fever, lethargy and ataxia could be secondary to prostatitis if this patient has additional clinical signs supportive of this including prostatic pain on rectal palpation.
Dr. Pearson	
INVOICE	Additional infectious disease testing should be considered since there was no other pathology within the abdomen. This could include a fever of unknown origin panel from IDEXX or a 4DX as screening tools.
71091	
DATE	Additional considerations would be thoracic radiographs and a thorough neurologic exam to determine if there are changes supportive of other causes of the fever and ataxia symptoms.
1/29/26	Referral to neurologist should also be considered if this patient's fever and ataxia continue.



PATIENT

Fynn Hodge

SPECIES

Canine

BREED

German Shepherd

SEX

Male

AGE

10 years

WEIGHT

87 lbs

INTERPRETED BY

Kim Radway, DVM,
DABVP (Canine/
Feline)

IMAGING PERFORMED BY

Kimberly Morgan

HOSPITAL NAME

Seven Fields VH

REFERRING VET

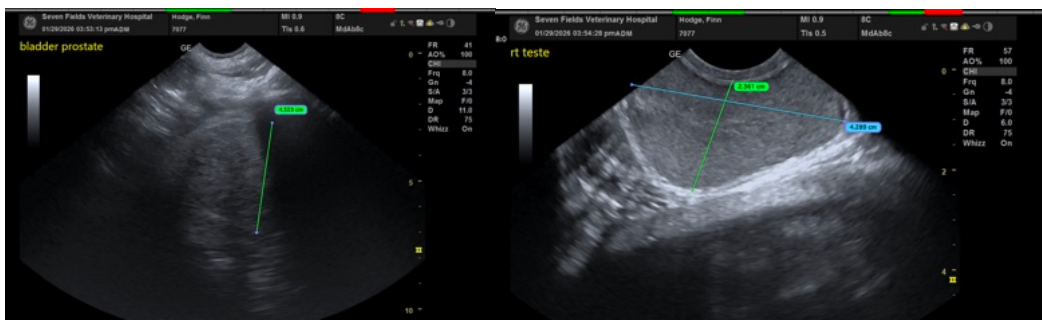
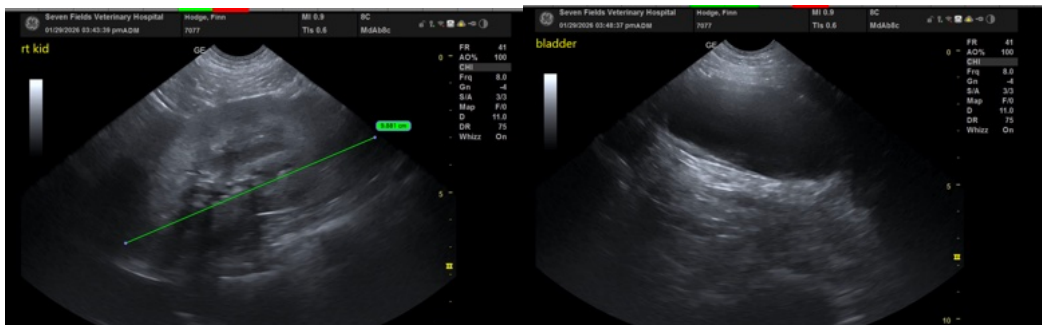
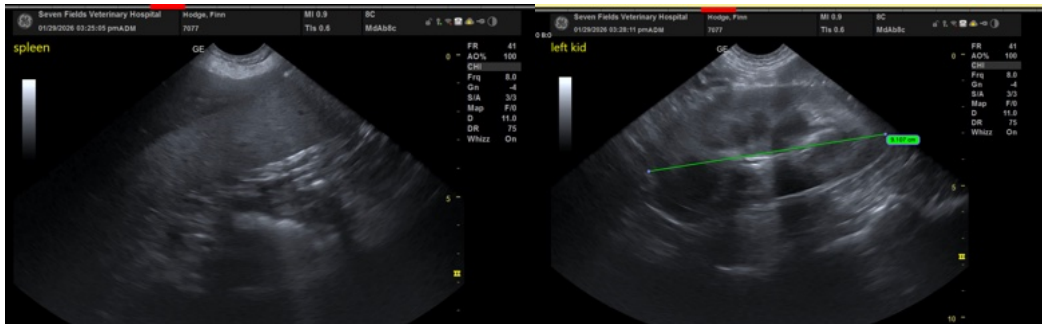
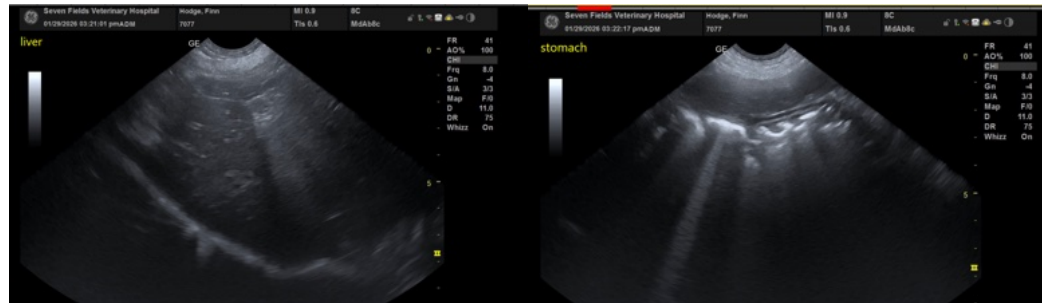
Dr. Pearson

INVOICE

71091

DATE

1/29/26





PATIENT

Fynn Hodge

SPECIES

Canine

BREED

German Shepherd

SEX

Male

AGE

10 years

WEIGHT

87 lbs

INTERPRETED BY

Kim Radway, DVM,
DABVP (Canine/
Feline)

IMAGING PERFORMED BY

Kimberly Morgan

HOSPITAL NAME

Seven Fields VH

REFERRING VET

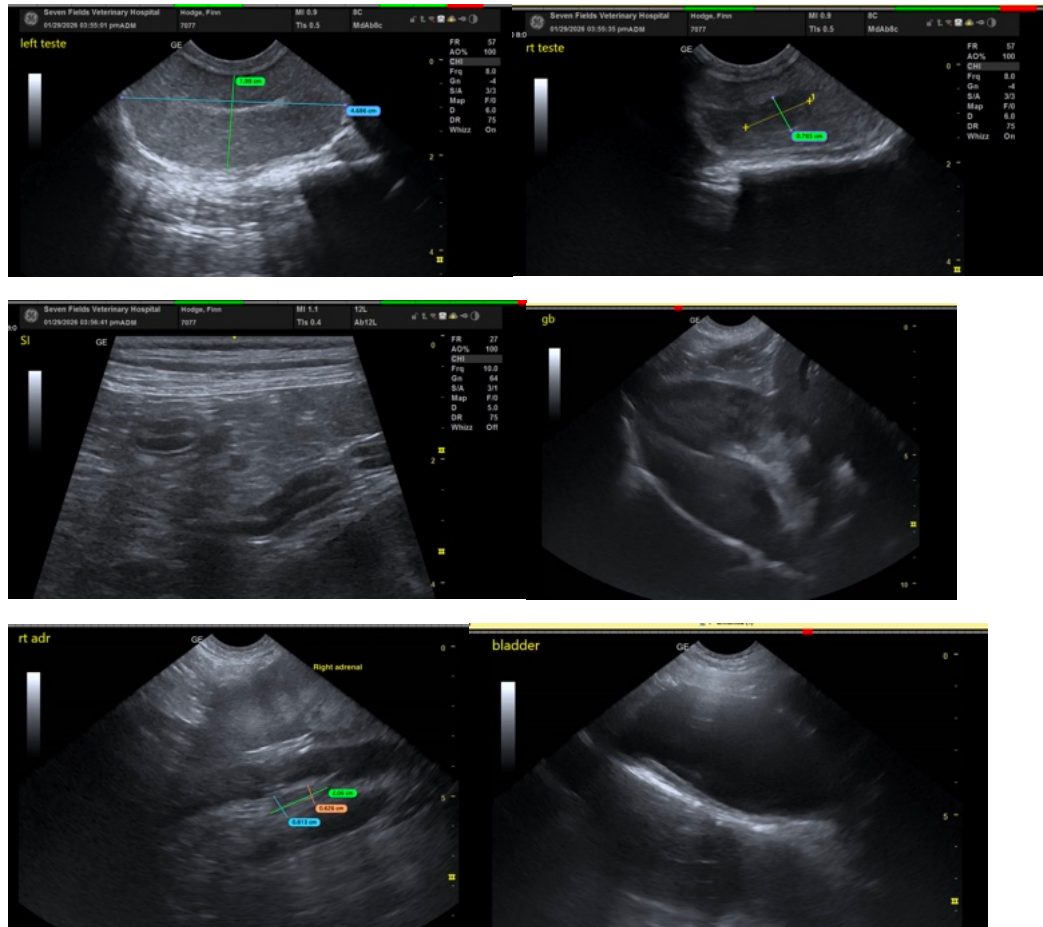
Dr. Pearson

INVOICE

71091

DATE

1/29/26



The information and recommendations provided are based on the images presented by the referring veterinarian/sonographer. No evaluation can be communicated regarding pathology that was not visible in the image/video clips provided.

Thank you for this referral. If the clinical or image interpretation does not parallel your findings or if I can be of any further assistance please contact me.

Kim Radway, DVM, DABVP (Canine/ Feline)

info@SonoPath.com