

**PATIENT PRESENTING CLINICAL SIGNS**

**PATIENT** Blue Fremgen  
**SPECIES** History: Presented 7/20 for not drinking as much water & sleeping a lot. Ascites found when doing cysto for urinalysis. Therapeutic abdominocentesis performed prior to U/S- removed ~500ml clear-serosanguineous fluid from abdomen.

Feline Abnormal PE/Chem/CBC/UA Results: T4- 7.1 ALP- 121 ALB- 1.9 TP- 5.1 BUN- 11 Creatinine- 0.4 CPK- 547 3+ proteinuria

**BREED**

DLH

**SEX**

Neutered Male

**AGE**

Unknown

**WEIGHT**

4.3 kg

**INTERPRETED BY**

Karen Ebersole, DVM,  
DABVP (Canine and  
Feline)

**IMAGING PERFORMED BY**

Dallas Reynolds, LVT

**HOSPITAL NAME**

Lone Mountain AH

**REFERRING VET**

Dr. Taylor Parker

**INVOICE**

13792

**DATE**

7.21.23

**ULTRASONOGRAPHIC EXAMINATION OF THE ABDOMEN**

**Urinary System**

The urinary bladder was normal in size and shape. The serosal and mucosal surfaces were smooth and curvilinear. The bladder wall was normal in thickness for the volume of urine present. The urine was anechoic with a moderate amount of suspended, non-shadowing, echogenic debris. This could represent mucous, epithelial cells, inflammatory cells, red blood cells or crystals. Correlation with a urine sample is recommended, as this can also be a normal finding in some cats.

Both kidneys were increased in size with a mildly irregular capsule contour. The cortex was hyperechoic with a coarse echotexture. The corticomedullary junction was indistinct. There were diffuse cortical pinpoint mineralizations. There was mild renal pelvis dilation. The left kidney measured 4.6 cm in length. The right kidney measured 4.8 cm in length.

**Adrenal Glands**

The left adrenal gland was normal in size, shape and position. The capsule was smooth with no evidence of capsular expansion with normal echogenicity. The left adrenal gland measured 3 mm in height. The region of the right adrenal gland was unremarkable.

**Spleen**

The spleen was normal size with a mildly irregular capsule contour. The parenchyma was hypoechoic with a subtle micronodular pattern. There were no overt masses or nodules present.

**Liver**

The liver was subjectively increased in size with a mildly irregular capsule contour. The parenchyma was mildly heterogeneous with possible micronodular pattern. The portal vasculature was mildly deviated, and the portal markings were increased.

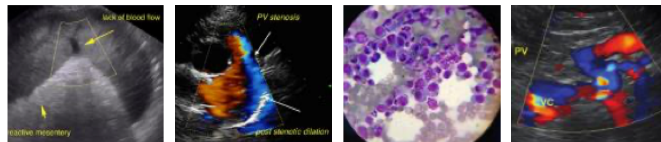
The gallbladder was normal in size and shape. The gallbladder wall was thin and echogenic, with no sign of luminal or surrounding inflammation. The gallbladder contents were largely anechoic.

**Gastrointestinal**

The stomach was largely empty with normal size, shape, and position. The stomach wall was normal in thickness and maintained appropriate layering. The **small intestine** displayed normal curvilinear patterns throughout, with normal wall thickness and layering. Normal peristalsis was present. The visible colon wall was normal in thickness and layering. There were no visible masses or focal lesions.

**Pancreas**

The left limb, body and right limb of the pancreas were visualized and found to be normal in size and shape. The pancreatic capsule was overall smooth, without deviation or expansion.



**PATIENT**

**Free Abdomen**

Blue Fremgen

There was moderate volume free peritoneal fluid which was anechoic with mild suspended sediment. The mesenteric and iliac lymph nodes were enlarged yet maintained normal length to width ratio and normal visible internal layering. The medial iliac lymph node measured 1.5 cm by 0.4 cm. On the transdiaphragmatic views, there was a small amount of free fluid visible in the pleural cavity.

**SPECIES**

Feline

**ULTRASONOGRAPHIC FINDINGS**

**BREED**

- Moderate volume free peritoneal fluid
- Free fluid in pleural cavity
- Bilateral infiltrative renal pattern
- Micronodular hepatic pattern – cholangiohepatitis vs infiltrative disease
- Mesenteric lymphadenopathy, reactive pattern

DLH

**SEX**

Neutered Male

**INTERPRETATION OF THE FINDINGS & FURTHER RECOMMENDATIONS**

**AGE**

Both FIP and infiltrative disease, especially lymphoma, could present this way. I recommend running a FIP PCR on the abdominal effusion. Also, a cytospin and cytology of the sediment (ideally on a fresh effusion sample, as cells degenerate if left sitting in free fluid).

Unknown

**WEIGHT**

The elevated thyroid levels likely indicate hyperthyroidism as a co-morbidity, but less likely a cause of the bicavitary effusion. CHF can cause pleural effusion, but much less this degree of ascites in a cat. Neoplasia or FIP remain the top differentials, although an echo could help to confirm this.

4.3 kg

**INTERPRETED BY**

Karen Ebersole, DVM,  
DABVP (Canine and  
Feline)

**IMAGING  
PERFORMED BY**

Dallas Reynolds, LVT

**HOSPITAL NAME**

Lone Mountain AH

**REFERRING VET**

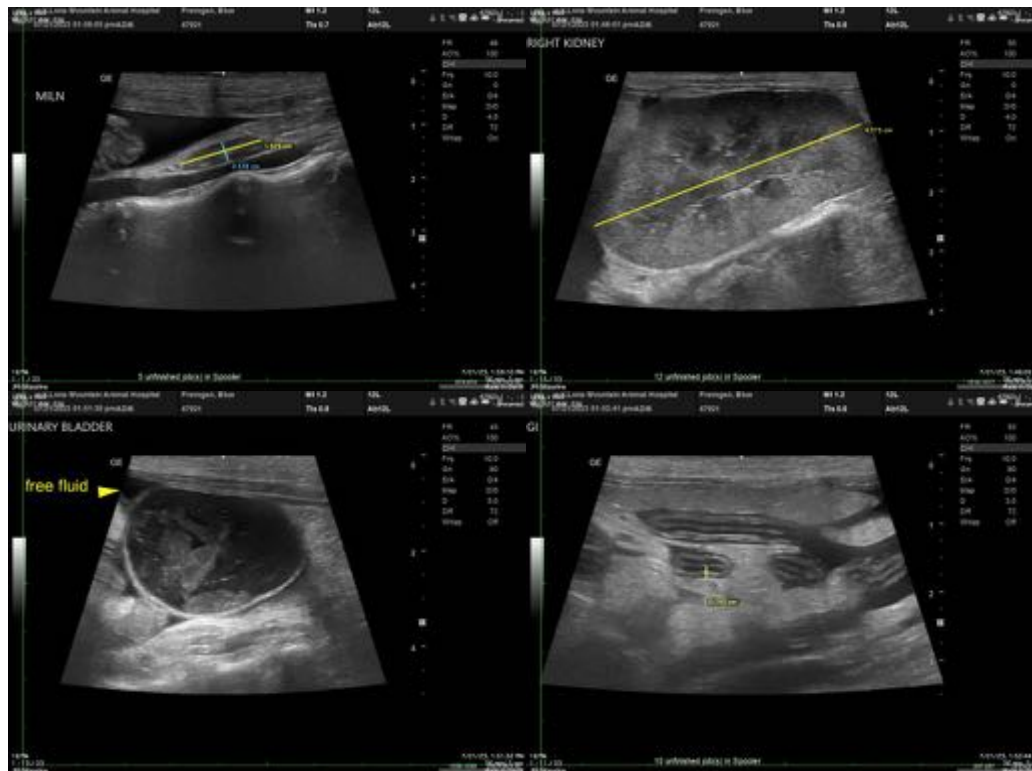
Dr. Taylor Parker

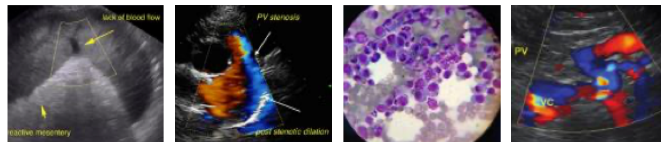
**INVOICE**

13792

**DATE**

7.21.23





**PATIENT**

Blue Fremgen

**SPECIES**

Feline

**BREED**

DLH

**SEX**

Neutered Male

**AGE**

Unknown

**WEIGHT**

4.3 kg

**INTERPRETED BY**

Karen Ebersole, DVM,  
DABVP (Canine and  
Feline)

**IMAGING  
PERFORMED BY**

Dallas Reynolds, LVT

**HOSPITAL NAME**

Lone Mountain AH

**REFERRING VET**

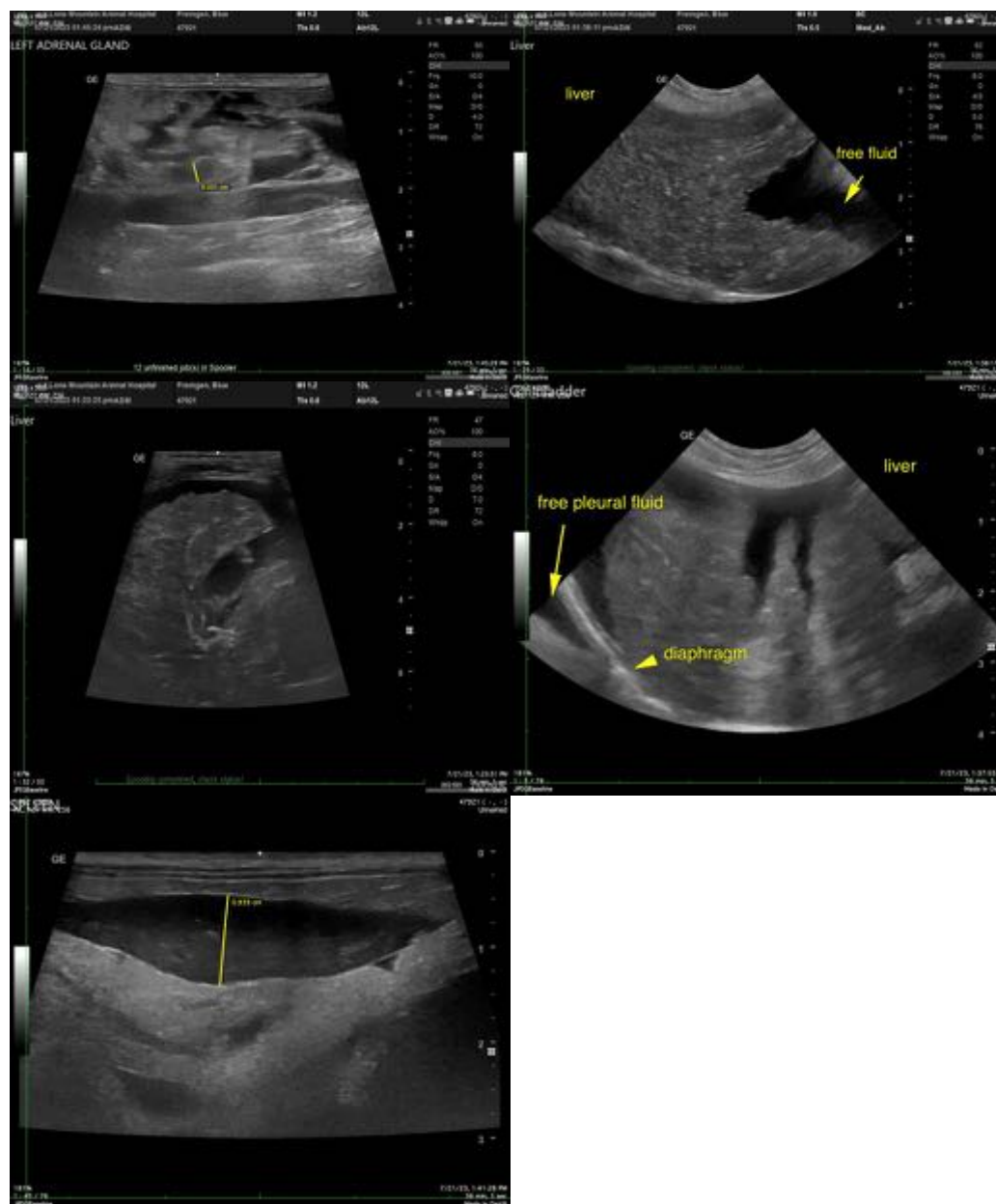
Dr. Taylor Parker

**INVOICE**

13792

**DATE**

7.21.23



The information and recommendations provided are based on the images presented by the referring veterinarian/sonographer. No evaluation can be communicated regarding pathology that was not visible in the image/video clips provided.

Thank you for this referral. If the clinical or image interpretation does not parallel your findings or if I can be of any further assistance, please contact me.

Karen Ebersole, DVM, DABVP (Canine and Feline practice)  
info@SonoPath.com