



PATIENT

Timmy Castronovo

SPECIES

Canine

BREED

Poodle Mix

SEX

Neutered Male

AGE

9.5 Years

WEIGHT

16.5 Pounds

INTERPRETED BY

James Wood, DVM,
DACVIM (Cardiology)

IMAGING PERFORMED BY

Dr. Carey Zumpano

HOSPITAL NAME

Pikesville AH

REFERRING VET

Dr. Carey Zumpano

INVOICE

37418

DATE

6/8/26

PRESENTING CLINICAL SIGNS

History: 2/6 murmur noted for first time on routine wellness exam in the last month. Echo performed to evaluate cause and staging. Patient was sedated with butorphanol to facilitate echo exam.
Abnormal PE/Chem/CBC/UA Results: Full blood profile--wnl BP 130-140 doppler

ULTRASONOGRAPHIC EXAMINATION OF THE HEART

CANINE CARDIAC PARAMETERS	LA long axis	LAmxN	Ao long axis	LA/AO (Heart Base; Swe, short axis)	LA/AO long axis	LVIDd	LVIDdN
NORMAL PARAMETER		<1.57		<1.6	<2.5		<1.7
PATIENT	2.76	1.48	1.12	1.6	2.4	2.5	1.34
CARDIAC PARAMETERS	Body Weight (kg)	AV VMAX (m/s)	PV MAX (m/s)	MR VMAX (m/s)	TR VMAX (m/s)	FS (%)	LVIDsN
NORMAL PARAMETER		0.7-1.7	0.7-1.6			22 - 49%	<0.9
PATIENT	7.5	1.43	0.85	--	1.84	49.6	0.58
CARDIAC PARAMETERS	HR (bpm)	MV E (m/s)	MV A (m/s)	MV E/A (m/s)	EF (%)	IVSdN	LVFWdN
NORMAL PARAMETER						<0.6	<0.6
PATIENT	114	0.81	0.65	1.25	--	0.56	0.36

Radiographic Interpretation

The cardiac silhouette is normal in size and shape. The visible pulmonary vasculature is within normal appearance. There is a mild diffuse bronchointerstitial pulmonary pattern. This may reflect an age-related change versus lower airway inflammatory disease. Congestive heart failure is not suspected.

Cardiac Presentation

The mitral valve leaflets are mildly thickened with mild eccentric and posteriorly directed mitral valve insufficiency. There is no prolapse of the mitral valve leaflets. The left atrial size is normal. Left ventricular internal dimensions during diastole are within normal limits and the global left ventricular



PATIENT

Timmy Castronovo

SPECIES

Canine

BREED

Poodle Mix

SEX

Neutered Male

AGE

9.5 Years

WEIGHT

16.5 Pounds

INTERPRETED BY

James Wood, DVM,
DACVIM (Cardiology)

IMAGING PERFORMED BY

Dr. Carey Zumpano

HOSPITAL NAME

Pikesville AH

REFERRING VET

Dr. Carey Zumpano

INVOICE

37418

DATE

6/8/26

systolic function is normal. There is normal right atrial size with mild eccentric tricuspid regurgitation. There is mild prolapse of the septal leaflet of the tricuspid valve and no evidence of pulmonary hypertension based upon tricuspid regurgitant velocities. The right ventricle subjectively appears normal in structure and function. The aortic and pulmonary valves have normal appearance and motion, and the corresponding outflow velocities are within normal limits. There is no aortic valve insufficiency. There is trivial pulmonary valve insufficiency. The aorta appears normal. The pulmonary artery and associated branches appear normal. There is no evidence of pleural effusion, pericardial effusion, or intracardiac masses.

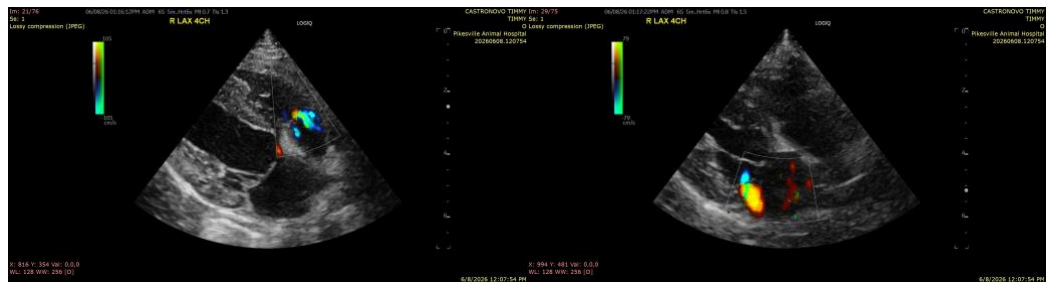
ULTRASONOGRAPHIC FINDINGS

- MMVD – ACVIM stage B1
- Mild tricuspid insufficiency

INTERPRETATION OF THE FINDINGS & FURTHER RECOMMENDATIONS

The echocardiogram showed evidence of myxomatous mitral valve disease. Based on this echocardiogram, the left atrial and left ventricular chamber sizes do not meet the criteria for the initiation of pimobendan. No medications are recommended at this time. The overall risk of adverse cardiovascular outcomes is considered very low in the near future. This is, however, a progressive disease, and as such repeat echocardiogram in ~9-12 months is recommended to screen for progression. Recheck sooner if there is a new cough, increase in the resting RR, or other concern for progressive cardiac disease. Recheck for an echocardiogram in 9-12 months or sooner if concerns arise.

It is very important to catch any clinical signs concerning for emerging CHF as early as possible. The client should be closely monitoring and ideally tracking the sleeping respiratory rate. The sleeping RR should be between 10-30 breaths per minute or less (ideally in the teens or low 20s). **If the resting RR is trending upward**, consistently >35/min while resting/sleeping AND/OR there is a new or progressive cough, the patient should be seen urgent for evaluation to determine if CHF is developing. *RECHECK ASAP for thoracic radiographs if there is a new cough or increase in RR to detect early CHF and avoid ER presentation**



The information and recommendations provided are based on the images presented by the referring veterinarian/sonographer. No evaluation can be communicated regarding pathology that was not visible in the image/video clips provided.



PATIENT

Timmy Castronovo

SPECIES

Canine

BREED

Poodle Mix

SEX

Neutered Male

AGE

9.5 Years

WEIGHT

16.5 Pounds

INTERPRETED BY

James Wood, DVM,
DACVIM (Cardiology)

IMAGING PERFORMED BY

Dr. Carey Zumpano

HOSPITAL NAME

Pikesville AH

REFERRING VET

Dr. Carey Zumpano

INVOICE

37418

DATE

6/8/26

Thank you for this referral. If the clinical or image interpretation does not parallel your findings or if I can be of any further assistance please contact me.

James Wood, DVM, DACVIM (Cardiology)

info@SonoPath.com