

PATIENT

Rex Riney

SPECIES

Canine

BREED

Fox Terrier X

SEX

Neutered Male

AGE

12 Years

WEIGHT

10.6 Pounds

INTERPRETED BY

James Wood, DVM,
 DACVIM (Cardiology)

IMAGING PERFORMED BY

Kelly Reschny

HOSPITAL NAME

Lakeshore Woods AH

REFERRING VET

Dr. Masoud

INVOICE

37411

DATE

6/8/26

PRESENTING CLINICAL SIGNS

History: please see attached echo

HOLTER MONITOR FINDINGS AND RHYTHM ASSESSMENT

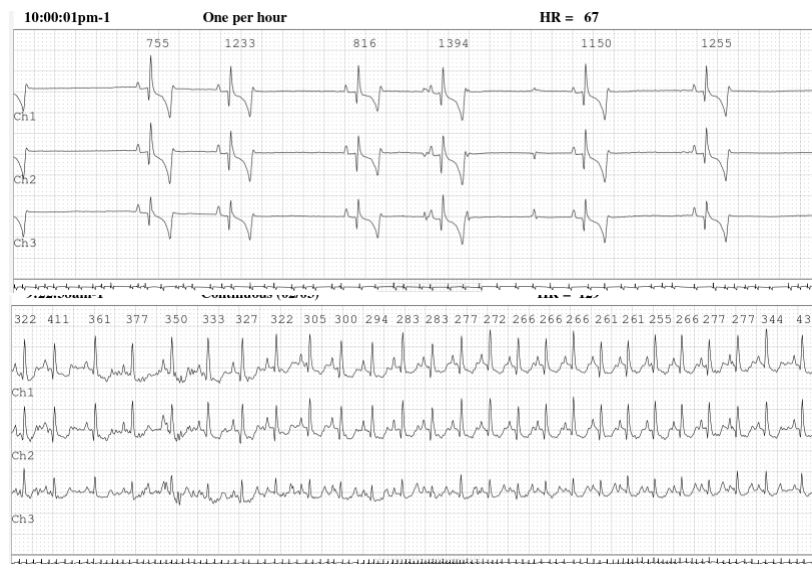Interpretation: A 24-hour Holter was reviewed. No events were triggered on the diary. There were zero supraventricular and zero ventricular ectopic beats. Rare second-degree AV block was noted. The longest pause was 2.3 seconds in duration. Maximum heart rate was 229bpm at 9:20 am. Minimum rate was 35bpm at 2:40 am. A strip was included of what is suspected to be secondary AV block, though the p-wave in question has a non-sinus morphology; this may represent artifact.

Rhythm diagnosis: This Holter revealed no arrhythmic cause of the reported paroxysmal episode.

RECOMMENDATIONS

No specific therapy is recommended based on this Holter, however, the aforementioned theophylline in the previous echo report could be considered if vasovagal syncope is suspected. Recheck echocardiogram is recommended in 6 months.

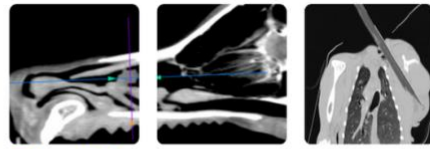
IMAGES



The information and recommendations provided are based on the images presented by the referring veterinarian/sonographer. No evaluation can be communicated regarding pathology that was not visible in the image/video clips provided.

Thank you for this referral. If the clinical or image interpretation does not parallel your findings or if I can be of any further assistance please contact me.

James Wood, DVM, DACVIM (Cardiology)



PATIENT info@SonoPath.com

Rex Riney

SPECIES

Canine

BREED

Fox Terrier X

SEX

Neutered Male

AGE

12 Years

WEIGHT

10.6 Pounds

INTERPRETED BY

James Wood, DVM,
DACVIM (Cardiology)

**IMAGING
PERFORMED BY**

Kelly Reschny

HOSPITAL NAME

Lakeshore Woods AH

REFERRING VET

Dr. Masoud

INVOICE

37411

DATE

6/8/26