



PATIENT

Naruto Kharal

SPECIES

Feline

BREED

DSH

SEX

Neutered Male

AGE

5 Years

WEIGHT

7.4 kg

INTERPRETED BY

James Wood, DVM,
DACVIM (Cardiology)

IMAGING PERFORMED BY

Dr. Iacovides

HOSPITAL NAME

Tuxedo AH

REFERRING VET

Dr. Chahal

INVOICE

37330

DATE

6/4/26

PRESENTING CLINICAL SIGNS

History: Presented to emerg clinic for lethargy. Echo today b/c part of work-up revealed cardiomegaly and positive proBNP

Abnormal PE/Chem/CBC/UA Results: BCS 7/9 Grade 1or2/6 murmur (Heart murmur not noted at our clinic when he was in a few months ago.) Rads: cardiomegaly appreciated but no obvious opacity in the lungs to suspect CHF or pneumonia, no obvious bronchial pattern. Stomach appears to have material in it with gas distension in SI and mixed pattern suspicious of obstruction proBNP abnormal -> colour of the two dots were the same which indicates values between 100-270 which indicates need for cardiac workup but likely in heart failure.

ULTRASONOGRAPHIC EXAMINATION OF THE HEART

FELINE CARDIAC PARAMETERS	BODY WEIGHT (kg)	HR (BPM)	IVSd (cm)	LVIDd (cm)	LVWd (cm)	FS (%)	EF (%)
NORMAL PARAMETER	-----	150-240	0.3-0.6	1.0-2.1	0.25-0.6	35-67	80-100
PATIENT	7.4	187	0.75	1.53	0.78	62.1	--
FELINE CARDIAC PARAMETERS	LA/AO (M-mode)	LA/AO HEART BASE (Sisson)	LAD LA MAX 4 Chamber		LVOT VEL. (m/s)	RVOT VEL. (m/s)	IVRT (m/)
NORMAL PARAMETER	<1.5	1.6	0.7-1.7		<1.6	<1.3	40-60
PATIENT	1.4	1.4	1.6		1.34	0.71	NM
Adapted from June Boon, Veterinary Echocardiography,1998 Sisson D et al. JVIM 1991; 5: 232, Jacobs et al. Am J Vet Res 1985; 46:1705							

Radiographic Interpretation

There is mild subjective cardiomegaly. The visible pulmonary veins are normal in size. Normal pulmonary parenchyma with no evidence of cardiogenic pulmonary edema.

Cardiac Presentation

The left atrium is equivocally dilated on LA Max, but normal based on short axis La/Ao and subjective assessment. No evidence of spontaneous echocontrast or intracardiac thrombi on the provided images. The mitral valve leaflets are normal and there is no mitral regurgitation. There is no evidence of systolic anterior motion of the mitral valve and no evidence of a left ventricular outflow tract obstruction. There is moderate symmetric concentric hypertrophy of the left ventricle. The right atrium is normal. The tricuspid valve is normal without evidence of tricuspid regurgitation. The right ventricle



PATIENT

Naruto Kharal

SPECIES

Feline

BREED

DSH

SEX

Neutered Male

AGE

5 Years

WEIGHT

7.4 kg

INTERPRETED BY

James Wood, DVM,
DACVIM (Cardiology)

IMAGING PERFORMED BY

Dr. Iacovides

HOSPITAL NAME

Tuxedo AH

REFERRING VET

Dr. Chahal

INVOICE

37330

DATE

6/4/26

appears to have preserved systolic function subjectively. The aortic and pulmonary valves are normal without evidence of insufficiency. Aortic and pulmonary outflow velocities are within normal limits. The aorta and PA are normal along with the associated PA branches. There is no evidence of pleural effusion, pericardial effusion, or intracardiac masses.

ULTRASONOGRAPHIC FINDINGS

- Hypertrophic cardiomyopathy phenotype- ACVIM stage B1 (high normal LA size)

INTERPRETATION OF THE FINDINGS & FURTHER RECOMMENDATIONS

The echocardiogram revealed thickening of the left ventricular walls. This is consistent with a hypertrophic cardiomyopathy phenotype, or HCM. In HCM, there is hypertrophy (thickening) of the muscle fibers that make up the walls of the heart. Many cases are a primary heart muscle disease (genetic in origin), however in some cases this can be a secondary process that may improve with treatment of the underlying condition (i.e. high blood pressure or hyperthyroidism among others). A blood pressure and total T4 are recommended in cats >6yr to rule these out as underlying causes (if not already performed). Regardless of the cause, the thickening causes diastolic dysfunction, and progressive left atrial enlargement. Eventually, cats with left atrial enlargement are at risk of developing congestive heart failure (pulmonary edema, pleural effusion, or both), blood clot formation and arrhythmias/sudden death. Some cats with mild HCM may live a normal lifespan with no further progression of disease. However, it is also possible that his HCM will progress over time and further therapy may be required for congestive heart failure, blood clots, or arrhythmias.

Fortunately, this patient does not have evidence of significant left atrial enlargement, so the risk of adverse cardiovascular outcomes is considered low at this time. No cardiac medications are recommended at this stage of the disease. Given the high normal left atrial size, a recheck is recommended in 6 months to screen for progression.

Monitoring

It is very important to catch any clinical signs concerning for emerging CHF as early as possible. The client should be closely monitoring and ideally tracking the sleeping respiratory rate. The sleeping RR should be between 10-30 breaths per minute or less (ideally in the teens or low 20s). **If the resting RR is trending upward**, consistently >35/min while resting/sleeping, the patient should be seen urgent for evaluation to determine if CHF is developing. If your pet is ever unable to use one or more of their limbs, seek emergency veterinary attention. *RECHECK ASAP for thoracic radiographs if there is increase in RR to detect early CHF and avoid ER presentation**



PATIENT

Naruto Kharal

SPECIES

Feline

BREED

DSH

SEX

Neutered Male

AGE

5 Years

WEIGHT

7.4 kg

INTERPRETED BY

James Wood, DVM,
DACVIM (Cardiology)

IMAGING PERFORMED BY

Dr. Iacovides

HOSPITAL NAME

Tuxedo AH

REFERRING VET

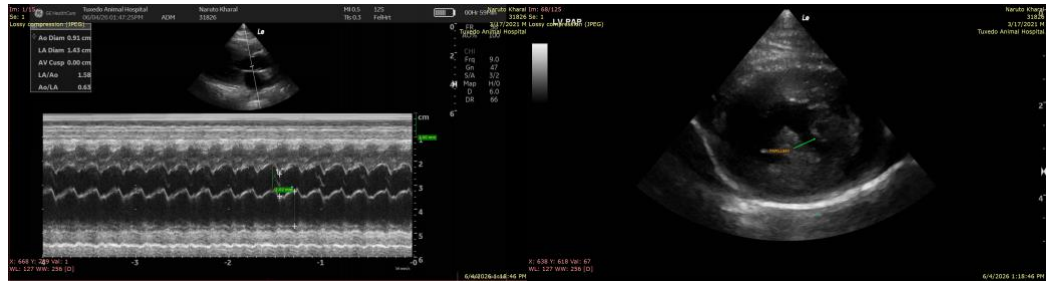
Dr. Chahal

INVOICE

37330

DATE

6/4/26



The information and recommendations provided are based on the images presented by the referring veterinarian/sonographer. No evaluation can be communicated regarding pathology that was not visible in the image/video clips provided.

Thank you for this referral. If the clinical or image interpretation does not parallel your findings or if I can be of any further assistance please contact me.

James Wood, DVM, DACVIM (Cardiology)

info@SonoPath.com