

PATIENT

Sadie Phanco

SPECIES

Canine

BREED

Cockapoo

SEX

Spayed Female

AGE

11 Years

WEIGHT

11.7 kg

INTERPRETED BY

James Wood, DVM,
DACVIM (Cardiology)

IMAGING PERFORMED BY

Andrea Nicastro, DVM,
DACVIM

HOSPITAL NAME

River Oaks

REFERRING VET

Dr. DiNicola

INVOICE

37280

DATE

5/29/26

PRESENTING CLINICAL SIGNS

History: Presented originally for a mass removal. On physical exam Grade 3/6 left sided heart murmur auscultated. On glucosamine.

Abnormal PE/Chem/CBC/UA Results: BP: 5/29/26: 160/101 (114), 187/116 (141), 174/96 (112)

ULTRASONOGRAPHIC EXAMINATION OF THE HEART

CANINE CARDIAC PARAMETERS	LA long axis	LAmxN	Ao long axis	LA/AO (Heart Base; Swe, short axis)	LA/AO long axis	LVIDd	LVIDdN
NORMAL PARAMETER		<1.57		<1.6	<2.5		<1.7
PATIENT	2.32	1.09	--	1.29	--	2.71	1.25
CARDIAC PARAMETERS	Body Weight (kg)	AV VMAX (m/s)	PV MAX (m/s)	MR VMAX (m/s)	TR VMAX (m/s)	FS (%)	LVIDsN
NORMAL PARAMETER		0.7-1.7	0.7-1.6			22 - 49%	<0.9
PATIENT	11.7	1.62	1.1	--	2.7	37.3	0.65
CARDIAC PARAMETERS	HR (bpm)	MV E (m/s)	MV A (m/s)	MV E/A (m/s)	EF (%)	IVSdN	LVFWdN
NORMAL PARAMETER						<0.6	<0.6
PATIENT	108	0.74	0.81	0.9	67.9	0.57	0.48

Radiographic Interpretation

The cardiac silhouette is subjectively normal in size with no evidence of left atrial or auricular enlargement. The visible pulmonary vasculature is normal in size. There is a mild diffuse bronchointerstitial pulmonary pattern. This may reflect age-related change versus lower airway inflammatory disease. Congestive heart failure is not suspected.

Cardiac Presentation

The mitral valve leaflets are mildly thickened with mild eccentric and posteriorly directed mitral valve insufficiency. There is no prolapse of the mitral valve leaflets. The left atrial size is normal. Left



PATIENT

Sadie Phanco

SPECIES

Canine

BREED

Cockapoo

SEX

Spayed Female

AGE

11 Years

WEIGHT

11.7 kg

INTERPRETED BY

James Wood, DVM,
 DACVIM (Cardiology)

IMAGING PERFORMED BY

Andrea Nicastro, DVM,
 DACVIM

HOSPITAL NAME

River Oaks

REFERRING VET

Dr. DiNicola

INVOICE

37280

DATE

5/29/26

ventricular internal dimensions during diastole are within normal limits and the global left ventricular systolic function is normal. There is a delayed relaxation pattern of LV filling. There is normal right atrial size with mild tricuspid regurgitation. There is no prolapse of the tricuspid valve leaflets and no evidence of pulmonary hypertension based upon tricuspid regurgitant velocities. The right ventricle subjectively appears normal in structure and function. The aortic and pulmonary valves have normal appearance and motion, and the corresponding outflow velocities are within normal limits. There is no evidence of pulmonary or aortic valve insufficiency. The aorta appears normal. The pulmonary trunk and branch PAs are normal in size and distensibility. There is a diastolic color flow with the PA trunk near the origin of the LPA. This is suspected to be artifact rather than a patent ductus arteriosus. There is no evidence of pleural effusion, pericardial effusion, or intracardiac masses.

ULTRASONOGRAPHIC FINDINGS

- MMVD-ACVIM stage B1
- Mild tricuspid insufficiency

INTERPRETATION OF THE FINDINGS & FURTHER RECOMMENDATIONS

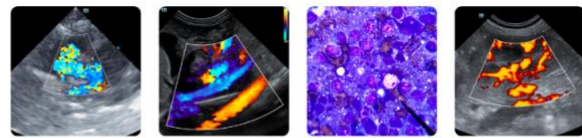
The echocardiogram showed evidence of myxomatous mitral valve disease. Based on this echocardiogram, the left atrial and left ventricular chamber sizes do not meet the criteria for the initiation of pimobendan. No medications are recommended at this time. The overall risk of adverse cardiovascular outcomes is considered very low in the near future. This is, however, a progressive disease, and as such repeat echocardiogram in ~9-12 months is recommended to screen for progression. Recheck sooner if there is a new cough, increase in the resting RR, or other concern for progressive cardiac disease. Recheck for an echocardiogram in 9-12 months or sooner if concerns arise.

Monitoring

It is very important to catch any clinical signs concerning for emerging CHF as early as possible. The client should be closely monitoring and ideally tracking the sleeping respiratory rate. The sleeping RR should be between 10-30 breaths per minute or less (ideally in the teens or low 20s). **If the resting RR is trending upward**, consistently >35/min while resting/sleeping AND/OR there is a new or progressive cough, the patient should be seen urgent for evaluation to determine if CHF is developing. *RECHECK ASAP for thoracic radiographs if there is a new cough or increase in RR to detect early CHF and avoid ER presentation**

Anesthesia

There is only a mildly increased risk to anesthesia given the underlying cardiac disease. On top of the increased intraoperative risks (hypotension, hypoventilation, hypothermia) with cardiac disease, there is an increased risk of precipitating CHF. With this understanding, anesthesia can be pursued pending normal labwork, with appropriate precautions. Recommendations for pre-operative sedation include an opiate (such as butorphanol) combined with a benzodiazepine (such as midazolam or diazepam). It is recommended to avoid alpha 2 agonists, as these agents can cause vasoconstriction and worsen MR, exacerbating left atrial hypertension. These effects persist for hours even after reversal. Etomidate or alfaxalone are preferred induction agents. Propofol can be considered for induction; however, is less preferred to alfaxalone or etomidate. Ketamine should ideally be avoided. Atropine should be



PATIENT

used as needed for blood pressure support when bradycardia is present during periods of hypotension.

Sadie Phanco

SPECIES

Full cardiac precautions should be taken with regards to monitoring (ideally CO₂, SpO₂, ECG, and BP monitoring) and judicious IV fluid administration (avoid volume overload or underload/hypotension - 4-5 mL/kg/hr surgical fluid rate is recommended).

Canine

BREED

Cockapoo

SEX

Spayed Female

AGE

11 Years

WEIGHT

11.7 kg

INTERPRETED BY

James Wood, DVM,
DACVIM (Cardiology)

IMAGING PERFORMED BY

Andrea Nicastro, DVM,
DACVIM

HOSPITAL NAME

River Oaks

REFERRING VET

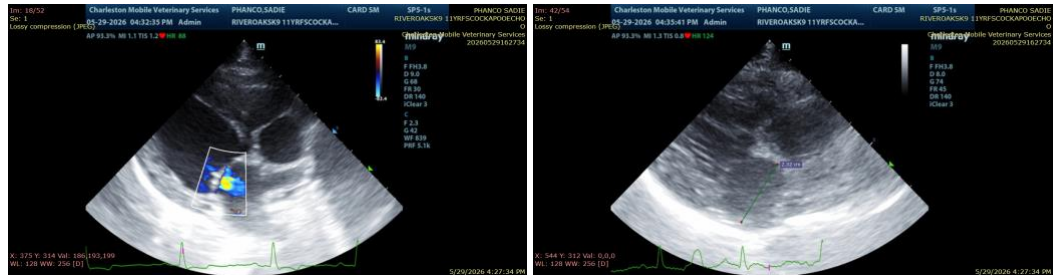
Dr. DiNicola

INVOICE

37280

DATE

5/29/26



The information and recommendations provided are based on the images presented by the referring veterinarian/sonographer. No evaluation can be communicated regarding pathology that was not visible in the image/video clips provided.

Thank you for this referral. If the clinical or image interpretation does not parallel your findings or if I can be of any further assistance please contact me.

James Wood, DVM, DACVIM (Cardiology)

info@SonoPath.com