



**PATIENT**

Trubble Silva

**SPECIES**

Canine

**BREED**

French Bulldog

**SEX**

Neutered Male

**AGE**

12 Years 7 Months

**WEIGHT**

34.3 Pounds

**INTERPRETED BY**

James Wood, DVM,  
DACVIM (Cardiology)

**IMAGING PERFORMED BY**

Vincent Ravancho, CVT

**HOSPITAL NAME**

St. Georges VH

**REFERRING VET**

Dr. Ng

**INVOICE**

37241

**DATE**

5/28/26

**PRESENTING CLINICAL SIGNS**

History: Screening thoracic rads for panting, bronchial pattern. See Abdominal Liver mineralization. r/o gb -liths.

Abnormal PE/Chem/CBC/UA Results: Chol 336. USG - 1.047, Struvites 11-20, 3+ protein, UPC 0.7

**ULTRASONOGRAPHIC EXAMINATION OF THE HEART**

<b>CANINE CARDIAC PARAMETERS</b>	<b>LA long axis</b>	<b>LAmxN</b>	<b>Ao long axis</b>	<b>LA/AO (Heart Base; Swe, short axis)</b>	<b>LA/AO long axis</b>	<b>LVIDd</b>	<b>LVIDdN</b>
<b>NORMAL PARAMETER</b>		<1.57		<1.6	<2.5		<1.7
<b>PATIENT</b>	2.84	1.22	1.37	--	2.07	3.19	1.34
<b>CARDIAC PARAMETERS</b>	<b>Body Weight (kg)</b>	<b>AV VMAX (m/s)</b>	<b>PV MAX (m/s)</b>	<b>MR VMAX (m/s)</b>	<b>TR VMAX (m/s)</b>	<b>FS (%)</b>	<b>LVIDsN</b>
<b>NORMAL PARAMETER</b>		0.7-1.7	0.7-1.6			22 - 49%	<0.9
<b>PATIENT</b>	15.6	1.4	1.35	5.8	2.8	27.9	0.78
<b>CARDIAC PARAMETERS</b>	<b>HR (bpm)</b>	<b>MV E (m/s)</b>	<b>MV A (m/s)</b>	<b>MV E/A (m/s)</b>	<b>EF (%)</b>	<b>IVSdN</b>	<b>LVFWdN</b>
<b>NORMAL PARAMETER</b>						<0.6	<0.6
<b>PATIENT</b>	174	--	--	--	49.3	0.58	0.58

**Cardiac Presentation**

The mitral valve leaflets are mildly thickened with mild eccentric and posteriorly directed mitral valve insufficiency. There is no prolapse of the mitral valve leaflets. The left atrial size is normal. Left ventricular internal dimensions during diastole are within normal limits and the global left ventricular systolic function is normal. There is normal right atrial size with mild to moderate tricuspid regurgitation. There is no prolapse of the tricuspid valve leaflets. The tricuspid regurgitant velocities suggest mild pulmonary hypertension. Clinically meaningful pulmonary hypertension is not suspected based on the lack of morphologic changes to the right heart and proximal pulmonary arterial tree. The right ventricle subjectively appears normal in structure and function. The aortic and pulmonary valves have normal appearance and motion, and the corresponding outflow velocities are within normal limits.



**PATIENT**

Trubble Silva

There is no evidence of pulmonary or aortic valve insufficiency. The aorta appears normal. The pulmonary artery and associated branches appear normal. There is no evidence of pleural effusion, pericardial effusion, or intracardiac masses.

**SPECIES**

Canine

**ULTRASONOGRAPHIC FINDINGS**

- MMVD - ACVIM stage B1
- Mild to moderate tricuspid insufficiency – r/o degenerative valve disease
- Mild pulmonary hypertension

**BREED**

French Bulldog

**INTERPRETATION OF THE FINDINGS & FURTHER RECOMMENDATIONS**

**SEX**

Neutered Male

The echocardiogram showed evidence of mild myxomatous mitral valve disease without left-sided chamber enlargement. No medications are recommended for this change. There's additionally mild to moderate tricuspid regurgitation that is also suspected to be secondary to degenerative valve disease. The right-sided chamber dimensions are subjectively normal.

**AGE**

12 Years 7 Months

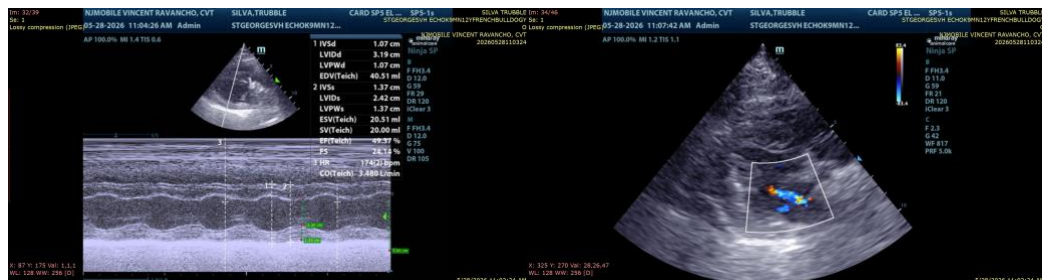
There is mild pulmonary hypertension based on the tricuspid regurgitant velocity, but clinically meaningful pulmonary hypertension is not suspected, and therapy with sildenafil is not recommended at this time. Recheck echocardiogram in 9 to 12 months or sooner if concerns arise.

**WEIGHT**

34.3 Pounds

**INTERPRETED BY**

James Wood, DVM,  
 DACVIM (Cardiology)



**IMAGING PERFORMED BY**

Vincent Ravancho, CVT

**HOSPITAL NAME**

St. Georges VH

**REFERRING VET**

Dr. Ng

**INVOICE**

37241

**The information and recommendations provided are based on the images presented by the referring veterinarian/sonographer. No evaluation can be communicated regarding pathology that was not visible in the image/video clips provided.**

**DATE**

5/28/26

Thank you for this referral. If the clinical or image interpretation does not parallel your findings or if I can be of any further assistance please contact me.

James Wood, DVM, DACVIM (Cardiology)



**PATIENT**

[info@SonoPath.com](mailto:info@SonoPath.com)

Trubble Silva

**SPECIES**

Canine

**BREED**

French Bulldog

**SEX**

Neutered Male

**AGE**

12 Years 7 Months

**WEIGHT**

34.3 Pounds

**INTERPRETED BY**

James Wood, DVM,  
DACVIM (Cardiology)

**IMAGING  
PERFORMED BY**

Vincent Ravancho, CVT

**HOSPITAL NAME**

St. Georges VH

**REFERRING VET**

Dr. Ng

**INVOICE**

37241

**DATE**

5/28/26