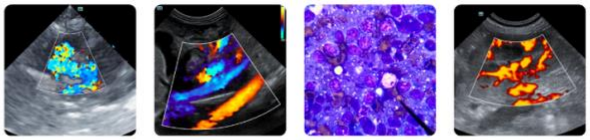

PATIENT
Georgie Amsterdam

SPECIES
Canine

BREED
Bichon Frise

SEX
Neutered Male

AGE
14 Years 8 Months

WEIGHT
24 Pounds

INTERPRETED BY
James Wood, DVM, DACVIM (Cardiology)

IMAGING PERFORMED BY
Graham Sager-Gellerman

HOSPITAL NAME
Back Bay VC

REFERRING VET
Eva Gurian, DVM

INVOICE
37212

DATE
5/26/26

PRESENTING CLINICAL SIGNS

History: To evaluate the following condition: gr II/VI left side systolic murmur
14yo MN Bichon with a new gr II/VI left side systolic murmur. Asymptomatic for cardiac disease. Also evaluating for anesthesia safety due to recommended dental procedure and ear mass biopsy.
Abnormal PE/Chem/CBC/UA Results: Previous Diagnostics: CBC Jan 2026— WBCs 17.1 k/ul, neutrophils 11.4k/ul; Jan 2025 WBCs 17.6 k/ul, neuts 11.3k/ul.

ULTRASONOGRAPHIC EXAMINATION OF THE HEART

CANINE CARDIAC PARAMETERS	LA long axis	LAmaxN	Ao long axis	LA/AO (Heart Base; Swe, short axis)	LA/AO long axis	LVIDd	LVIDdN
NORMAL PARAMETER		<1.57		<1.6	<2.5		<1.7
PATIENT	2.84	1.36	1.07	1.38	2.6	3.0	1.41
CARDIAC PARAMETERS	**Body Weight (kg)**	**AV VMAX (m/s)**	**PV MAX (m/s)**	**MR VMAX (m/s)**	**TR VMAX (m/s)**	**FS (%)**	**LVIDsN**
NORMAL PARAMETER		0.7-1.7	0.7-1.6			22 - 49%	<0.9
PATIENT	10.9	1.7	1.4	--	--	65.7	0.4
CARDIAC PARAMETERS	**HR (bpm)**	**MV E (m/s)**	**MV A (m/s)**	**MV E/A (m/s)**	**EF (%)**	**IVSdN**	**LVFWdN**
NORMAL PARAMETER						<0.6	<0.6
PATIENT	100	1.1	0.98	1.15	93.7	0.57	0.48

Cardiac Presentation

The mitral valve is equivocally thickened with trivial to mild central mitral valve insufficiency, best visualized on the apical imaging windows. There is no prolapse of the mitral valve leaflets. The left atrial size is normal. Left ventricular internal dimensions during diastole are within normal limits and the global left ventricular systolic function is normal. There is normal right atrial size. The tricuspid valve appears normal with no tricuspid valve insufficiency. The right ventricle subjectively appears normal in structure and function. The aortic valve has normal appearance and motion, and the transaortic flow velocity is mildly increased, consistent with an audible murmur. The pulmonary valve

PATIENT
Georgie Amsterdam

SPECIES
Canine

BREED
Bichon Frise

SEX
Neutered Male

AGE
14 Years 8 Months

WEIGHT
24 Pounds

INTERPRETED BY
James Wood, DVM, DACVIM (Cardiology)

IMAGING PERFORMED BY
Graham Sager-Gellerman

HOSPITAL NAME
Back Bay VC

REFERRING VET
Eva Gurian, DVM

INVOICE
37212

DATE
5/26/26

has normal appearance and motion, and the corresponding pulmonic outflow velocity is within normal limits. There is no evidence of clinically relevant pulmonary hypertension based on the lack of changes to the right heart and proximal pulmonary arteries. There is no evidence of pulmonary or aortic valve insufficiency. The aorta appears normal. The pulmonary artery and associated branches appear normal. There is no evidence of pleural effusion, pericardial effusion, or intracardiac masses.

ULTRASONOGRAPHIC FINDINGS

- Myxomatous mitral valve disease, ACVIM stage B1

INTERPRETATION OF THE FINDINGS & FURTHER RECOMMENDATIONS

The echocardiogram showed evidence of myxomatous mitral valve disease. Based on this echocardiogram, the left atrial and left ventricular chamber sizes do not meet the criteria for the initiation of pimobendan. No medications are recommended at this time. The overall risk of adverse cardiovascular outcomes is considered very low in the near future. This is, however, a progressive disease, and as such repeat echocardiogram in ~9-12 months is recommended to screen for progression. Recheck sooner if there is a new cough, increase in the resting RR, or other concern for progressive cardiac disease. Recheck for an echocardiogram in 9-12 months or sooner if concerns arise.

Monitoring

It is very important to catch any clinical signs concerning for emerging CHF as early as possible. The client should be closely monitoring and ideally tracking the sleeping respiratory rate. The sleeping RR should be between 10-30 breaths per minute or less (ideally in the teens or low 20s). **If the resting RR is trending upward**, consistently>35/min while resting/sleeping AND/OR there is a new or progressive cough, the patient should be seen urgent for evaluation to determine if CHF is developing. *RECHECK ASAP for thoracic radiographs if there is a new cough or increase in RR to detect early CHF and avoid ER presentation**

Anesthesia

There is only a mildly increased risk to anesthesia given the underlying cardiac disease. On top of the increased intraoperative risks (hypotension, hypoventilation, hypothermia) with cardiac disease, there is an increased risk of precipitating CHF. With this understanding, anesthesia can be pursued pending normal lab work, with appropriate precautions. Recommendations for pre-operative sedation include an opiate (such as butorphanol) combined with a benzodiazepine (such as midazolam or diazepam). It is recommended to avoid alpha 2 agonists, as these agents can cause vasoconstriction and worsen MR, exacerbating left atrial hypertension. These effects persist for hours even after reversal. Etomidate or alfaxalone are preferred induction agents. Propofol can be considered for induction; however, is less preferred to alfaxalone or etomidate. Ketamine should ideally be avoided. Atropine should be used as needed for blood pressure support when bradycardia is present during periods of hypotension.

PATIENT

Georgie Amsterdam

SPECIES

Canine

BREED

Bichon Frise

SEX

Neutered Male

AGE

14 Years 8 Months

WEIGHT

24 Pounds

INTERPRETED BY

James Wood, DVM, DACVIM (Cardiology)

IMAGING PERFORMED BY

Graham Sager-Gellerman

HOSPITAL NAME

Back Bay VC

REFERRING VET

Eva Gurian, DVM

INVOICE

37212

DATE

5/26/26

Full cardiac precautions should be taken with regards to monitoring (ideally CO2, SpO2, ECG, and BP monitoring) and judicious IV fluid administration (avoid volume overload or underload/hypotension - 4-5 mL/kg/hr surgical fluid rate is recommended).

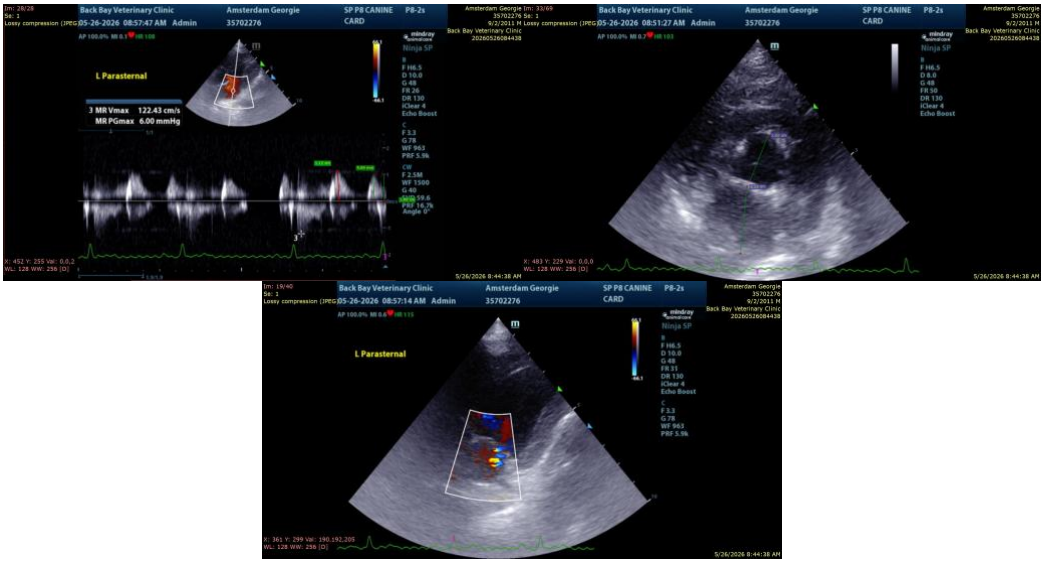

The information and recommendations provided are based on the images presented by the referring veterinarian/sonographer. No evaluation can be communicated regarding pathology that was not visible in the image/video clips provided.

Thank you for this referral. If the clinical or image interpretation does not parallel your findings or if I can be of any further assistance please contact me.

James Wood, DVM, DACVIM (Cardiology)

info@SonoPath.com