



**PATIENT**

Bailey Tam

**PRESENTING CLINICAL SIGNS**

History: Grade 2 HM; Asymptomatic; echo for dental.

**SPECIES**

Canine

**ULTRASONOGRAPHIC EXAMINATION OF THE HEART**

**BREED**

Yorkie

**SEX**

Male

**AGE**

12 Years

**WEIGHT**

11 Pounds

**INTERPRETED BY**

James Wood, DVM,  
DACVIM (Cardiology)

**IMAGING PERFORMED BY**

Vincent Ravancho, CVT

**HOSPITAL NAME**

Englewood Cliffs  
Veterinary, PA

**REFERRING VET**

Dr. Rachel Park

**INVOICE**

37213

**DATE**

5/26/26

CANINE CARDIAC PARAMETERS	LA long axis	LAmxN	Ao long axis	LA/AO (Heart Base; Swe, short axis)	LA/AO long axis	LVIDd	LVIDdN
<b>NORMAL PARAMETER</b>		<1.57		<1.6	<2.5		<1.7
<b>PATIENT</b>	1.98	1.21	0.86	1.34	2.3	1.99	1.2
CARDIAC PARAMETERS	Body Weight (kg)	AV VMAX (m/s)	PV MAX (m/s)	MR VMAX (m/s)	TR VMAX (m/s)	FS (%)	LVIDsN
<b>NORMAL PARAMETER</b>		0.7-1.7	0.7-1.6			22 - 49%	<0.9
<b>PATIENT</b>	5.0	1.9	2.33	5.0	--	31.7	0.72
CARDIAC PARAMETERS	HR (bpm)	MV E (m/s)	MV A (m/s)	MV E/A (m/s)	EF (%)	IVSdN	LVFWdN
<b>NORMAL PARAMETER</b>						<0.6	<0.6
<b>PATIENT</b>	136	--	--	--	62.4	0.56	0.56

**Cardiac Presentation**

There is mild to moderate anterior mitral valve leaflet thickening with mild eccentric and posteriorly directed mitral valve insufficiency. There is no prolapse of the mitral valve leaflets. Left atrial and left ventricular chamber sizes are normal. Left ventricular diastolic function was not assessed. The global left ventricular systolic function is normal. There is normal right atrial size with trace eccentric tricuspid valve insufficiency. There is no prolapse of the tricuspid valve leaflets and no evidence of pulmonary hypertension based upon tricuspid regurgitant velocities. The right ventricle subjectively appears normal in structure and function. The aortic and pulmonary valves have normal appearance and motion and the corresponding outflow velocities are within normal limits. There is no evidence of pulmonary or aortic valve insufficiency. The aorta appears normal. The pulmonary artery and associated branches appear normal. There is no evidence of pleural effusion, pericardial effusion, or intracardiac masses.

**ULTRASONOGRAPHIC FINDINGS**



**PATIENT**

- Myxomatous mitral valve disease, ACVIM stage B1
- Trace tricuspid insufficiency

Bailey Tam

**SPECIES**

Canine

**BREED**

Yorkie

**SEX**

Male

**AGE**

12 Years

**WEIGHT**

11 Pounds

**INTERPRETED BY**

James Wood, DVM,  
DACVIM (Cardiology)

**IMAGING PERFORMED BY**

Vincent Ravancho, CVT

**HOSPITAL NAME**

Englewood Cliffs  
Veterinary, PA

**REFERRING VET**

Dr. Rachel Park

**INVOICE**

37213

**DATE**

5/26/26

**INTERPRETATION OF THE FINDINGS & FURTHER RECOMMENDATIONS**

The echocardiogram showed evidence of myxomatous mitral valve disease. Based on this echocardiogram, the left atrial and left ventricular chamber sizes do not meet the criteria for the initiation of pimobendan. No medications are recommended at this time. The overall risk of adverse cardiovascular outcomes is considered very low in the near future. This is, however, a progressive disease, and as such repeat echocardiogram in ~9-12 months is recommended to screen for progression. Recheck sooner if there is a new cough, increase in the resting RR, or other concern for progressive cardiac disease. Recheck for an echocardiogram in 9-12 months or sooner if concerns arise.

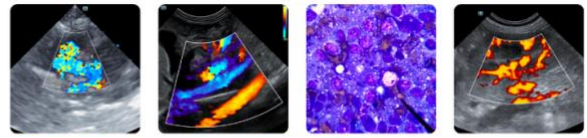
**Monitoring**

It is very important to catch any clinical signs concerning for emerging CHF as early as possible. The client should be closely monitoring and ideally tracking the sleeping respiratory rate. The sleeping RR should be between 10-30 breaths per minute or less (ideally in the teens or low 20s). **If the resting RR is trending upward**, consistently >35/min while resting/sleeping AND/OR there is a new or progressive cough, the patient should be seen urgent for evaluation to determine if CHF is developing. \*RECHECK ASAP for thoracic radiographs if there is a new cough or increase in RR to detect early CHF and avoid ER presentation\*\*

**Anesthesia**

There is only a mildly increased risk to anesthesia given the underlying cardiac disease. On top of the increased intraoperative risks (hypotension, hypoventilation, hypothermia) with cardiac disease, there is an increased risk of precipitating CHF. With this understanding, anesthesia can be pursued pending normal labwork, with appropriate precautions. Recommendations for pre-operative sedation include an opiate (such as butorphanol) combined with a benzodiazepine (such as midazolam or diazepam). It is recommended to avoid alpha 2 agonists, as these agents can cause vasoconstriction and worsen MR, exacerbating left atrial hypertension. These effects persist for hours even after reversal. Etomidate or alfaxalone are preferred induction agents. Propofol can be considered for induction; however, is less preferred to alfaxalone or etomidate. Ketamine should ideally be avoided. Atropine should be used as needed for blood pressure support when bradycardia is present during periods of hypotension.

Full cardiac precautions should be taken with regards to monitoring (ideally CO2, SpO2, ECG, and BP monitoring) and judicious IV fluid administration (avoid volume overload or underload/hypotension - 4-5 mL/kg/hr surgical fluid rate is recommended).



**PATIENT**

Bailey Tam

**SPECIES**

Canine

**BREED**

Yorkie

**SEX**

Male

**AGE**

12 Years

**WEIGHT**

11 Pounds

**INTERPRETED BY**

James Wood, DVM,  
 DACVIM (Cardiology)

**IMAGING PERFORMED BY**

Vincent Ravancho, CVT

**HOSPITAL NAME**

Englewood Cliffs  
 Veterinary, PA

**REFERRING VET**

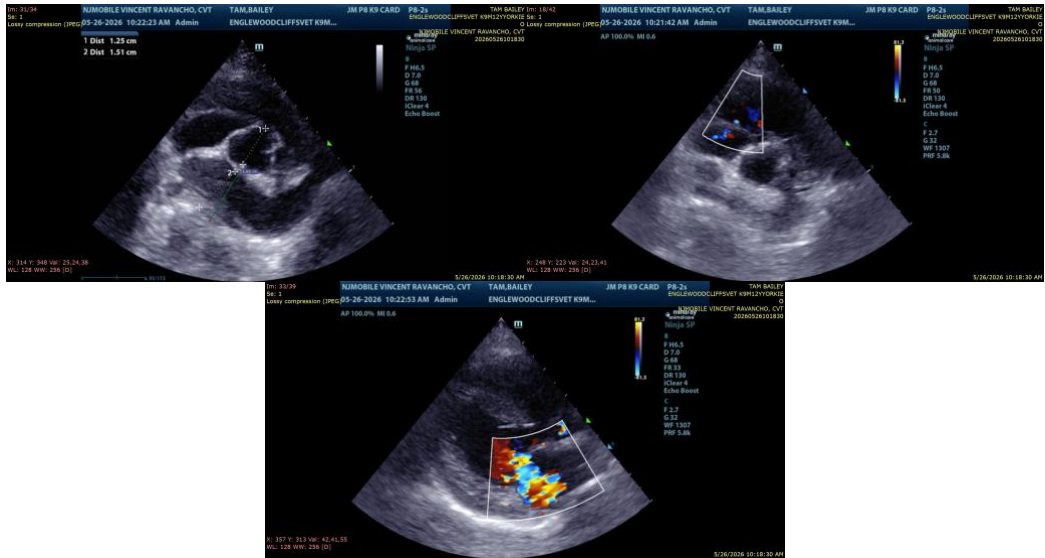
Dr. Rachel Park

**INVOICE**

37213

**DATE**

5/26/26



**The information and recommendations provided are based on the images presented by the referring veterinarian/sonographer. No evaluation can be communicated regarding pathology that was not visible in the image/video clips provided.**

Thank you for this referral. If the clinical or image interpretation does not parallel your findings or if I can be of any further assistance please contact me.

James Wood, DVM, DACVIM (Cardiology)

[info@SonoPath.com](mailto:info@SonoPath.com)