

PATIENT

Roxy Schelhaas

SPECIES

Canine

BREED

Chihuahua

SEX

Spayed Female

AGE

15 Years

WEIGHT

3.6 kg

INTERPRETED BY

James Wood, DVM,
 DACVIM (Cardiology)

IMAGING PERFORMED BY

Amanda Stewart

HOSPITAL NAME

Woodstock VH

REFERRING VET

Dr. Norris

INVOICE

37179

DATE

5/22/26

PRESENTING CLINICAL SIGNS

History: Abdominal - History of new hyporexia/picky appetite over the past 1-2 months. Over past weekend, developed full anorexia. Began vomiting 24 hours ago (May 20) - 5 episodes of mainly bilious fluid, no blood. No diarrhea noted. Has been lethargic. Tense in abdomen on exam, and suspicious of hepatomegaly but difficult to palpate deeply. Weight has been trending downward and has lost 0.2 kg in 2 weeks.

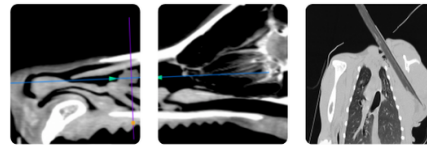
Cardiac - Low grade murmur first noted in 2024, VHS was normal (<11) at that time. Murmur today grade 2/6 left systolic, no pulse deficits. ProBNP normal on recent bloodwork (May 4). Asymptomatic in regards to heart/lungs; hoping to proceed with anesthesia for dental procedure in future, so evaluating if good candidate for anesthesia.

Current Medications: Cerenia injection May 21/26 1230pm

Abnormal PE/Chem/CBC/UA Results: Full wellness performed recently on May 4th (at annual exam) all WNL other than non-regenerative anemia (38%) and lymphopenia. 4Dx negative. CBC repeated today (May 21) which showed HCT at 44.5% (was not significantly dehydrated on exam but has had reduced fluid intake), and cPL was WNL. Previous history of pancreatitis in 2021 but has been on low fat diet since. Primary Question to Be Answered in This Exam hoping to proceed with anesthesia for dental procedure in future, so evaluating if good candidate for anesthesia. suspicious of hepatomegaly but difficult to palpate deeply. Weight has been trending downward and has lost 0.2 kg in 2 weeks.

ULTRASONOGRAPHIC EXAMINATION OF THE HEART

CANINE CARDIAC PARAMETERS	LA long axis	LAmxN	Ao long axis	LA/AO (Heart Base; Swe, short axis)	LA/AO long axis	LVIDd	LVIDdN
NORMAL PARAMETER		<1.57		<1.6	<2.5		<1.7
PATIENT	2.13	1.44	--	1.45	--	1.2	1.15
CARDIAC PARAMETERS	Body Weight (kg)	AV VMAX (m/s)	PV MAX (m/s)	MR VMAX (m/s)	TR VMAX (m/s)	FS (%)	LVIDsN
NORMAL PARAMETER		0.7-1.7	0.7-1.6			22 - 49%	<0.9
PATIENT	3.6	1.04	1.06	5.55	--	27.3	0.76
CARDIAC PARAMETERS	HR (bpm)	MV E (m/s)	MV A (m/s)	MV E/A (m/s)	EF (%)	IVSdN	LVFWdN



PATIENT

Roxy Schelhaas

SPECIES

Canine

BREED

Chihuahua

SEX

Spayed Female

AGE

15 Years

WEIGHT

3.6 kg

INTERPRETED BY

James Wood, DVM,
 DACVIM (Cardiology)

IMAGING PERFORMED BY

Amanda Stewart

HOSPITAL NAME

Woodstock VH

REFERRING VET

Dr. Norris

INVOICE

37179

DATE

5/22/26

NORMAL PARAMETER						<0.6	<0.6
PATIENT	1.05	--	--	--	56.5	0.49	0.5

Cardiac Presentation

The mitral valve leaflets are mildly thickened with mild eccentric and posteriorly directed mitral valve insufficiency. There is no prolapse of the mitral valve leaflets. The left atrial size is normal. The left ventricular diastolic function was not assessed. The global left ventricular systolic function is normal. On the right parasternal short axis view, optimized for the right atrium, there is aliasing color flow. Spectral Doppler of this region shows a prolonged slope. These could be indicative of an obstructive lesion, such as a Cor Triatriatum Dexter, as this lesion appears proximal to the tricuspid valve, however, hepatic venous distention or caudal vena cava dilation was not seen on the included abdomen. If these latter findings are not present, this is likely an insignificant lesion. There is normal right atrial size. The tricuspid valve appears normal with no tricuspid valve insufficiency. The right ventricle subjectively appears normal in structure and function. The aortic and pulmonary valves have normal appearance and motion, and the corresponding outflow velocities are within normal limits. There is no evidence of clinically relevant pulmonary hypertension based on the lack of changes to the right heart and proximal pulmonary arteries. There is no evidence of pulmonary or aortic valve insufficiency. The aorta appears normal. The pulmonary artery and associated branches appear normal. There is no evidence of pleural effusion, pericardial effusion, or intracardiac masses.

ULTRASONOGRAPHIC FINDINGS

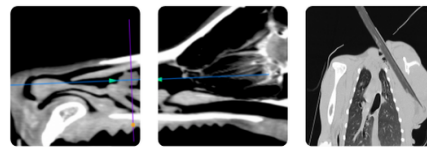
- Myxomatous mitral valve disease, ACVIM stage B1
- Abnormal color flow within the right atrium R/O artifact, less likely mild cor triatriatum

INTERPRETATION OF THE FINDINGS & FURTHER RECOMMENDATIONS

The echocardiogram showed evidence of myxomatous mitral valve disease. Based on this echocardiogram, the left atrial and left ventricular chamber sizes do not meet the criteria for the initiation of pimobendan. No medications are recommended at this time. The overall risk of adverse cardiovascular outcomes is considered very low in the near future. This is, however, a progressive disease, and as such repeat echocardiogram in ~9-12 months is recommended to screen for progression. Recheck sooner if there is a new cough, increase in the resting RR, or other concern for progressive cardiac disease. Recheck for an echocardiogram in 9-12 months or sooner if concerns arise.

Monitoring

It is very important to catch any clinical signs concerning for emerging CHF as early as possible. The client should be closely monitoring and ideally tracking the sleeping respiratory rate. The sleeping RR should be between 10-30 breaths per minute or less (ideally in the teens or low 20s). **If the resting RR is trending upward, consistently >35/min while resting/sleeping AND/OR there is a new or progressive cough, the patient should be seen urgent for evaluation to determine if CHF is developing.**



PATIENT

*RECHECK ASAP for thoracic radiographs if there is a new cough or increase in RR to detect early CHF and avoid ER presentation**

Roxy Schelhaas

SPECIES

Canine

BREED

Chihuahua

SEX

Spayed Female

AGE

15 Years

WEIGHT

3.6 kg

Anesthesia

There is only a mildly increased risk to anesthesia given the underlying cardiac disease. On top of the increased intraoperative risks (hypotension, hypoventilation, hypothermia) with cardiac disease, there is an increased risk of precipitating CHF. With this understanding, anesthesia can be pursued pending normal labwork, with appropriate precautions. Recommendations for pre-operative sedation include an opiate (such as butorphanol) combined with a benzodiazepine (such as midazolam or diazepam). It is recommended to avoid alpha 2 agonists, as these agents can cause vasoconstriction and worsen MR, exacerbating left atrial hypertension. These effects persist for hours even after reversal. Etomidate or alfaxalone are preferred induction agents. Propofol can be considered for induction; however, is less preferred to alfaxalone or etomidate. Ketamine should ideally be avoided. Atropine should be used as needed for blood pressure support when bradycardia is present during periods of hypotension.

Full cardiac precautions should be taken with regards to monitoring (ideally CO2, SpO2, ECG, and BP monitoring) and judicious IV fluid administration (avoid volume overload or underload/hypotension - 4-5 mL/kg/hr surgical fluid rate is recommended).

INTERPRETED BY

James Wood, DVM,
DACVIM (Cardiology)

IMAGING PERFORMED BY

Amanda Stewart

HOSPITAL NAME

Woodstock VH

REFERRING VET

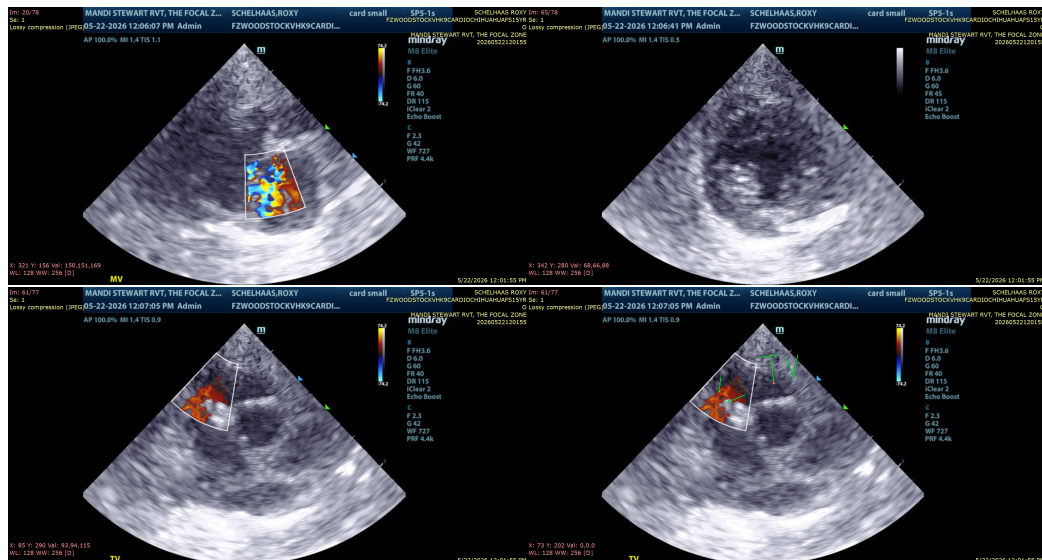
Dr. Norris

INVOICE

37179

DATE

5/22/26

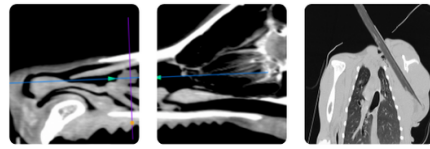


The information and recommendations provided are based on the images presented by the referring veterinarian/sonographer. No evaluation can be communicated regarding pathology that was not visible in the image/video clips provided.

Thank you for this referral. If the clinical or image interpretation does not parallel your findings or if I can be of any further assistance please contact me.

James Wood, DVM, DACVIM (Cardiology)

info@SonoPath.com



PATIENT

Roxy Schelhaas

SPECIES

Canine

BREED

Chihuahua

SEX

Spayed Female

AGE

15 Years

WEIGHT

3.6 kg

INTERPRETED BY

James Wood, DVM,
DACVIM (Cardiology)

**IMAGING
PERFORMED BY**

Amanda Stewart

HOSPITAL NAME

Woodstock VH

REFERRING VET

Dr. Norris

INVOICE

37179

DATE

5/22/26