

PATIENT

Sofie Kaufman

SPECIES

Canine

BREED

Schnauzer

SEX

Spayed Female

AGE

9 Years

WEIGHT

8.7 kg

INTERPRETED BY

James Wood, DVM,
 DACVIM (Cardiology)

IMAGING PERFORMED BY

Amanda Stewart

HOSPITAL NAME

Woodstock VH

REFERRING VET

Dr. DeVries

INVOICE

37180

DATE

5/22/26

PRESENTING CLINICAL SIGNS

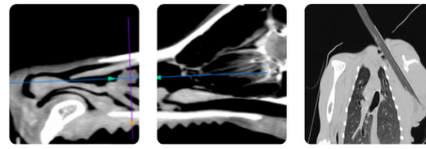
History of hyperlipidemia. She presented for an examination where several new issues were identified. The owner reports a new, pea-sized mass on the right upper eyelid that has appeared recently. The owner also notes that Sofie pants a fair bit. A mass approximately the size of a pea was noted on the right upper eyelid. A large lump, suspected to be a lipoma, is present behind the left elbow in the axillary region. A new grade 2/6 left basilar systolic heart murmur was auscultated. Surgical removal of the right upper eyelid mass and the suspected lipoma in the left axillary area was discussed but U/S recommended to investigate the cause of the newly detected heart.

Current Medications: 200 mg Gabapentin night before and morning of appt, 50 mg Trazodone night before and morning of appt. May need Butorphanol depending on level of sedation with Gaba/Traz

Abnormal PE/Chem/CBC/UA Results: BW elevations in calcium, TP, and sodium. albumin high end of normal. - ALK PHOS significantly elevated at 904 U/L (ref range 5-160 U/L). considerable increase from previous value of 233 U/L. - other liver values WNR - free T4 normal - SG > 1.050. - calcium secondary to being protein-bound on albumin and dehydration - 4DX Neg /Fecal Neg Primary Question to Be Answered in This Exam - echo recommended prior to a sx procedure to investigate the cause of the new heart murmur and assess anesthetic risk. - abd u/s rec with the echo. goal is to evaluate the liver for underlying pathology, (vacuolar hepatopathy) that could be causing ALP elevation. Cushings was a ddx but w/ SG / water consumption appr 27 mL/kg/day, unlikely. consuming more water later in the day compared to the morning.

ULTRASONOGRAPHIC EXAMINATION OF THE HEART

CANINE CARDIAC PARAMETERS	LA long axis	LAmxN	Ao long axis	LA/AO (Heart Base; Swe, short axis)	LA/AO long axis	LVIDd	LVIDdN
NORMAL PARAMETER		<1.57		<1.6	<2.5		<1.7
PATIENT	2.34	1.2	1.06	1.39	2.21	2.92	1.47
CARDIAC PARAMETERS	Body Weight (kg)	AV VMAX (m/s)	PV MAX (m/s)	MR VMAX (m/s)	TR VMAX (m/s)	FS (%)	LVIDsN
NORMAL PARAMETER		0.7-1.7	0.7-1.6			22 - 49%	<0.9
PATIENT	8.7	1.55	1.05	5.24	--	35.27	0.81



PATIENT

Sofie Kaufman

SPECIES

Canine

BREED

Schnauzer

SEX

Spayed Female

AGE

9 Years

WEIGHT

8.7 kg

INTERPRETED BY

James Wood, DVM,
 DACVIM (Cardiology)

IMAGING PERFORMED BY

Amanda Stewart

HOSPITAL NAME

Woodstock VH

REFERRING VET

Dr. DeVries

INVOICE

37180

DATE

5/22/26

CARDIAC PARAMETERS	HR (bpm)	MV E (m/s)	MV A (m/s)	MV E/A (m/s)	EF (%)	IVSdN	LVFWdN
NORMAL PARAMETER						<0.6	<0.6
PATIENT	97	1.0	1.0	1.0	66.4	0.41	0.41

Cardiac Presentation

The mitral valve leaflets are mildly thickened with mild eccentric mitral valve insufficiency. Leaflet prolapse is not identified. The left atrial size is normal. Left ventricular internal dimensions during diastole are within normal limits and the global left ventricular systolic function is normal. There is normal right atrial size. The tricuspid valve appears normal with no tricuspid valve insufficiency. The right ventricle subjectively appears normal in structure and function. The aortic and pulmonary valves have normal appearance and motion, and the corresponding outflow velocities are within normal limits. There is no evidence of clinically relevant pulmonary hypertension based on the lack of changes to the right heart and proximal pulmonary arteries. There is no evidence of pulmonary or aortic valve insufficiency. The aorta appears normal. The pulmonary artery and associated branches appear normal. There is no evidence of pleural effusion, pericardial effusion, or intracardiac masses.

ULTRASONOGRAPHIC FINDINGS

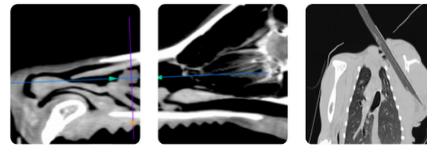
- Myxomatous mitral valve disease, ACVIM stage B1

INTERPRETATION OF THE FINDINGS & FURTHER RECOMMENDATIONS

The echocardiogram showed evidence of myxomatous mitral valve disease. Based on this echocardiogram, the left atrial and left ventricular chamber sizes do not meet the criteria for the initiation of pimobendan. No medications are recommended at this time. The overall risk of adverse cardiovascular outcomes is considered very low in the near future. This is, however, a progressive disease, and as such repeat echocardiogram in ~9-12 months is recommended to screen for progression. Recheck sooner if there is a new cough, increase in the resting RR, or other concern for progressive cardiac disease. Recheck for an echocardiogram in 9-12 months or sooner if concerns arise.

Monitoring

It is very important to catch any clinical signs concerning for emerging CHF as early as possible. The client should be closely monitoring and ideally tracking the sleeping respiratory rate. The sleeping RR should be between 10-30 breaths per minute or less (ideally in the teens or low 20s). **If the resting RR is trending upward**, consistently >35/min while resting/sleeping AND/OR there is a new or progressive cough, the patient should be seen urgent for evaluation to determine if CHF is developing. *RECHECK ASAP for thoracic radiographs if there is a new cough or increase in RR to detect early CHF and avoid ER presentation**



PATIENT

Sofie Kaufman

SPECIES

Canine

BREED

Schnauzer

SEX

Spayed Female

AGE

9 Years

WEIGHT

8.7 kg

INTERPRETED BY

James Wood, DVM,
DACVIM (Cardiology)

IMAGING PERFORMED BY

Amanda Stewart

HOSPITAL NAME

Woodstock VH

REFERRING VET

Dr. DeVries

INVOICE

37180

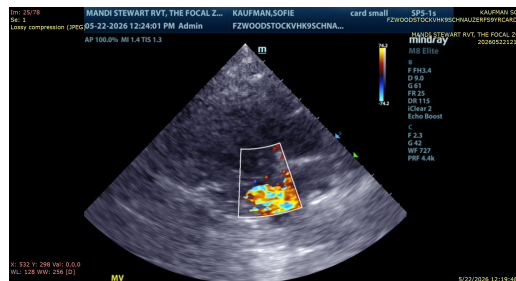
DATE

5/22/26

Anesthesia

There is only a mildly increased risk to anesthesia given the underlying cardiac disease. On top of the increased intraoperative risks (hypotension, hypoventilation, hypothermia) with cardiac disease, there is an increased risk of precipitating CHF. With this understanding, anesthesia can be pursued pending normal labwork, with appropriate precautions. Recommendations for pre-operative sedation include an opiate (such as butorphanol) combined with a benzodiazepine (such as midazolam or diazepam). It is recommended to avoid alpha 2 agonists, as these agents can cause vasoconstriction and worsen MR, exacerbating left atrial hypertension. These effects persist for hours even after reversal. Etomidate or alfaxalone are preferred induction agents. Propofol can be considered for induction; however, is less preferred to alfaxalone or etomidate. Ketamine should ideally be avoided. Atropine should be used as needed for blood pressure support when bradycardia is present during periods of hypotension.

Full cardiac precautions should be taken with regards to monitoring (ideally CO2, SpO2, ECG, and BP monitoring) and judicious IV fluid administration (avoid volume overload or underload/hypotension - 4-5 mL/kg/hr surgical fluid rate is recommended).



The information and recommendations provided are based on the images presented by the referring veterinarian/sonographer. No evaluation can be communicated regarding pathology that was not visible in the image/video clips provided.

Thank you for this referral. If the clinical or image interpretation does not parallel your findings or if I can be of any further assistance please contact me.

James Wood, DVM, DACVIM (Cardiology)

info@SonoPath.com