



PATIENT

Saxon Brakman

SPECIES

Feline

BREED

DSH

SEX

Neutered Male

AGE

11 Years

WEIGHT

12.5 Pounds

INTERPRETED BY

James Wood, DVM,
DACVIM (Cardiology)

IMAGING PERFORMED BY

Dr. Ryan Leal

HOSPITAL NAME

Wellesley AH

REFERRING VET

Dr. Meaghan Godwin

INVOICE

37154

DATE

5/20/26

PRESENTING CLINICAL SIGNS

History: Heart murmur first ausculted in 2020. A ProBNP run at that time was normal. The murmur has been stable on auscultation, however, a ProBNP was recently elevated. Patient is otherwise doing well at home.

Problem List: Heart Murmur, Grade III/VI, stable, Chorioretinitis, OU, stable, no medications needed, Mild Dental Calculus, Mildly Dry Coat.

Abnormal PE/Chem/CBC/UA Results: PE: BCS 6/9; Mildly dry coat with mild diffuse scaling; clear bright corneas OU, no scleral injection or anisocoria. Mild hyper-reflexive retinas noted OU, consistent with stable chorioretinitis; Grade III/VI parasternal systolic heart murmur; Mild calculus present with minimal associated gingivitis; Calm and cooperative for examination. a bit nervous CBC: WNL (HCT 36%, WBC 8.5k, Plat adequate) Chem: WNL (Creat 1.1, BUN 24, SDMA 7) T4: 2.3 WNL HWT: Negative ProBNP: 169 Blood Pressure: Doppler (size 3 cuff): 175 (average 6 readings range of 170-180).

ULTRASONOGRAPHIC EXAMINATION OF THE HEART

FELINE CARDIAC PARAMETERS	BODY WEIGHT (lb)	HR (BPM)	IVSd (cm)	LVIDd (cm)	LVWd (cm)	FS (%)	EF (%)
NORMAL PARAMETER	-----	150-240	0.3-0.6	1.0-2.1	0.25-0.6	35-67	80-100
PATIENT	12.5	185	0.65	1.5	0.51	35.3	--
FELINE CARDIAC PARAMETERS	LA/AO (M-mode)	LA/AO HEART BASE (Sisson)	LAD LA MAX 4 Chamber		LVOT VEL. (m/s)	RVOT VEL. (m/s)	IVRT (m)
NORMAL PARAMETER	<1.5	1.6	0.7-1.7		<1.6	<1.3	40-60
PATIENT	1.7	1.69	1.4		1.1	0.89	NM
Adapted from June Boon, Veterinary Echocardiography, 1998 Sisson D et al. JVIM 1991; 5: 232, Jacobs et al. Am J Vet Res 1985; 46:1705							

Cardiac Presentation

The left atrium is mildly to moderately enlarged based on short axis La/Ao and is equivocally dilated on long axis LA Max. No spontaneous echocontrast or intracardiac thrombi are appreciated. The mitral valve leaflets are normal and there is no mitral regurgitation. There is no evidence of systolic anterior motion of the mitral valve and no evidence of a left ventricular outflow tract obstruction. There is mild thickening of the interventricular septum with a normal LV free wall thickness. The right atrium is normal. The tricuspid valve is normal without evidence of tricuspid regurgitation. Subjectively normal



PATIENT

Saxon Brakman

SPECIES

Feline

BREED

DSH

SEX

Neutered Male

AGE

11 Years

WEIGHT

12.5 Pounds

INTERPRETED BY

James Wood, DVM,
DACVIM (Cardiology)

IMAGING PERFORMED BY

Dr. Ryan Leal

HOSPITAL NAME

Wellesley AH

REFERRING VET

Dr. Meaghan Godwin

INVOICE

37154

DATE

5/20/26

RV systolic function. The aortic and pulmonary valves are normal without evidence of insufficiency. Aortic and pulmonary outflow velocities are within normal limits. The aorta and PA are normal along with the associated PA branches. There is no evidence of pleural effusion, pericardial effusion, or intracardiac masses.

ULTRASONOGRAPHIC FINDINGS

- Hypertrophic cardiomyopathy phenotype, ACVIM stage B2

INTERPRETATION OF THE FINDINGS & FURTHER RECOMMENDATIONS

The echocardiogram revealed thickening of the left ventricular walls. This is consistent with a hypertrophic cardiomyopathy phenotype, or HCM. In HCM, there is hypertrophy (thickening) of the muscle fibers that make up the walls of the heart. Many cases are a primary heart muscle disease (genetic in origin), however in some cases this can be a secondary process that may improve with treatment of the underlying condition (i.e. high blood pressure or hyperthyroidism among others). A blood pressure and total T4 are recommended in cats >6yr to rule these out as underlying causes (if not already performed). Regardless of the cause, the thickening causes diastolic dysfunction, and progressive left atrial enlargement. Eventually, cats with left atrial enlargement are at risk of developing congestive heart failure (pulmonary edema, pleural effusion, or both), blood clot formation and arrhythmias/sudden death. Some cats with mild HCM may live a normal lifespan with no further progression of disease. However, it is also possible that his HCM will progress over time and further therapy may be required for congestive heart failure, blood clots, or arrhythmias.

The echocardiogram showed HCM with left atrial enlargement. While there is no evidence of CHF, baseline thoracic radiographs within the last 1-2 years are ideal to serve as a baseline. Clopidogrel is recommended (18.75 mg PO once daily) to reduce the risk of clot formation. A recheck echocardiogram +/- thoracic radiographs are recommended in 6 months to determine if there is any progression.

Monitoring

It is very important to catch any clinical signs concerning for emerging CHF as early as possible. The client should be closely monitoring and ideally tracking the sleeping respiratory rate. The sleeping RR should be between 10-30 breaths per minute or less (ideally in the teens or low 20s). **If the resting RR is trending upward**, consistently >35/min while resting/sleeping, the patient should be seen urgent for evaluation to determine if CHF is developing. If your pet is ever unable to use one or more of their limbs, seek emergency veterinary attention. *RECHECK ASAP for thoracic radiographs if there is increase in RR to detect early CHF and avoid ER presentation**



PATIENT

Saxon Brakman

SPECIES

Feline

BREED

DSH

SEX

Neutered Male

AGE

11 Years

WEIGHT

12.5 Pounds

INTERPRETED BY

James Wood, DVM,
DACVIM (Cardiology)

IMAGING PERFORMED BY

Dr. Ryan Leal

HOSPITAL NAME

Wellesley AH

REFERRING VET

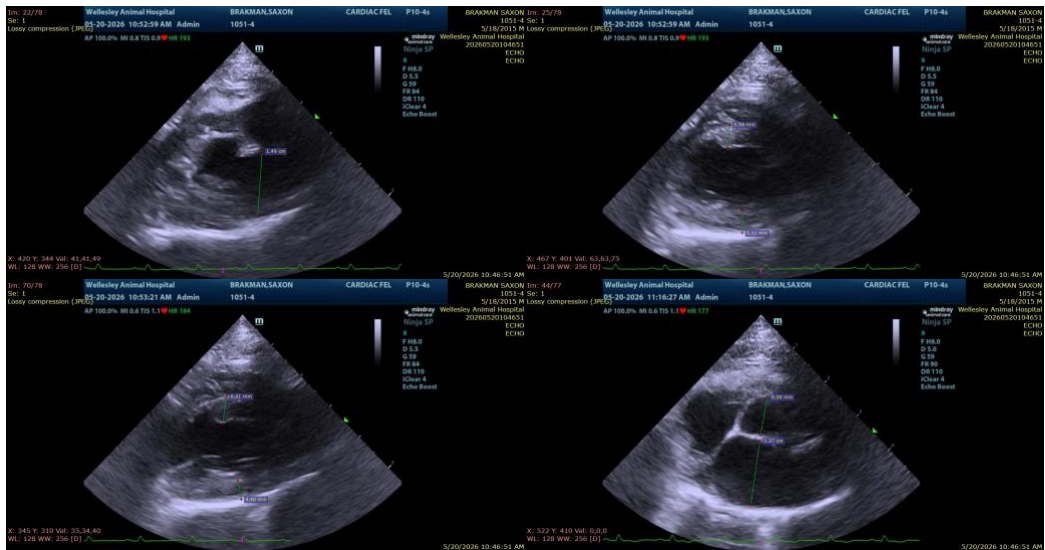
Dr. Meaghan Godwin

INVOICE

37154

DATE

5/20/26



The information and recommendations provided are based on the images presented by the referring veterinarian/sonographer. No evaluation can be communicated regarding pathology that was not visible in the image/video clips provided.

Thank you for this referral. If the clinical or image interpretation does not parallel your findings or if I can be of any further assistance please contact me.

James Wood, DVM, DACVIM (Cardiology)

info@SonoPath.com