



**PATIENT PRESENTING CLINICAL SIGNS**

**Piper Ferch** History: Hs of weight loss, polyphagia. Not pu/pd or v/d. HX of arthritic change on exam. Has a grade V/VI heart murrer, has a fractured 108 and 208 tooth a salivary mucocele on left side. Plan to image to image abdomen to determine cause of weight loss and polyphagia. Check for neoplasia, pancreatitis and adrenal gland status --- BCS 3/9 - underweight. Please pay attn to area cranial to bladder and neoplastic mass?

**SPECIES**

**Canine** Abnormal PE/Chem/CBC/UA Results: lipase - 468 (0-250) t\$ 0.8 (1-4) alk phos 647 (5-160) lymphopenia and eosinophilia

**BREED**

**ULTRASONOGRAPHIC EXAMINATION OF THE ABDOMEN**

**Terrier Mix**

**Urinary System**

The urinary bladder mucosa, trigone, and visible urethra are normal in thickness and there is no evidence of mucosal irregularities. The bladder lumen is mildly distended with anechoic urine and bladder thickness is considered normal for volume of urine.

**SEX**

**Spayed Female**

The left kidney is normal in size (4.10 cm) shape and architecture with smooth peripheral margins. There is normal corticomedullary distinction and normal echogenicity. There is no evidence of pyelectasia, nephroliths, infarcts or hydroureter.

**AGE**

**13 years**

The right kidney is normal in size (4.34 cm) shape and architecture with smooth peripheral margins. There is normal corticomedullary distinction and normal echogenicity. There is no evidence of pyelectasia, nephroliths, infarcts or hydroureter.

**WEIGHT**

**12.4 lbs**

**Adrenal Glands**

The left adrenal gland is normal in size (0.53 cm) with a normal shape and is normal in appearance and echogenicity.

**INTERPRETED BY**

Jessica Midence, DVM,  
DACVIM (SAIM)

The right adrenal gland is normal in size (0.50 cm) with a normal shape and is normal in appearance and echogenicity.

**Spleen**

**IMAGING PERFORMED BY**

A. Murphy CVT

The spleen is subjectively normal in size with a normal smooth capsular contour. Parenchyma is appropriately finely textured and homogenous with normal echogenicity relative to surrounding tissue (hyperechoic to liver). No focal nodules or masses are observed. Splenic vasculature appears normal.

**HOSPITAL NAME**

Wauwatosa Vet

**Liver**

The liver is subjectively mildly enlarged with normal contours, structure, with smooth peripheral margins. The echogenicity appears mildly hypoechoic with decreased portal markings. No overt evidence of inflammatory, infiltrative or regenerative pathology is evident. The visible portions of the vasculature and biliary tract appear normal. No pathological hepatic lymphadenopathy observed.

**REFERRING VET**

Dr Elaine Binor, DVM

The gallbladder lumen is mildly distended. The wall is a normal thickness and smooth. There is a mild amount of hyperechoic dependent debris. The cystic and common bile ducts are normal/not visible.

**Gastrointestinal Tract**

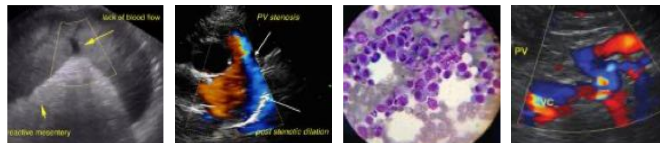
**INVOICE**

12937

The gastric lumen contains a moderate amount of liquid that is stagnant. The stomach wall is of normal wall thickness, though certain sections measure between 0.35 cm to 0.45 cm (which is towards the upper limit of normal), with some variability due to rugal folds. There is normal gastric wall layering. There are no masses or focal lesions observed and the pyloric outflow tract appears patent (from what can be seen).

**DATE**

5.4.23



**PATIENT** Piper Ferch  
The visualized areas of duodenum, jejunum and ileum appear normal in thickness. The duodenum is normal (0.43 cm) with distinct wall layering, though there is at least one mucosal hyperechoic speckle seen. The remainder of the small intestines are normal (0.30 cm) with normal wall layering. The lumen of the small intestine was mostly empty with no signs of ileus, obstruction or foreign material. No focal lesions observed.

**SPECIES** Canine  
The sections of colon are visualized with formed fecal material and gas shadowing distally.

**BREED** Terrier Mix  
**Pancreas**  
The area of the pancreas is normal and isoechoic to surrounding mesentery. There is no evidence of nodules or cystic lesions. There is no evidence of regional mesenteric inflammation or fluid. The visible pancreatic duct was normal.

**SEX** Spayed Female  
**Peritoneum**  
Evaluation of the peritoneal cavity did not reveal any evidence of effusion, or subjective lymphadenomegaly. The omentum is of normal uniform echogenicity. Within the caudal abdomen (just cranial to the bladder) there is a round, smooth and homogenous mass (3.70 x 1.85 cm). There is artifact created by this mass that makes evaluation of the deep edge difficult. The mass abuts the bladder, but is not obviously associated with any organs from the loops provided.

**AGE** 13 years  
**ULTRASONOGRAPHIC FINDINGS**

**Findings**

- Mass cranial to the bladder. Rule out intraabdominal lipoma.
- Gastritis/emerging enteropathy

**INTERPRETED BY**

Jessica Midence, DVM, DACVIM (SAIM)

**IMAGING PERFORMED BY**

A. Murphy CVT

**HOSPITAL NAME**

Wauwatosa Vet

**REFERRING VET**

Dr Elaine Binor, DVM

**INTERPRETATION OF THE FINDINGS & FURTHER RECOMMENDATIONS**

The mass cranial to the bladder is very smooth, round and homogenous. Based on the appearance of the mass, consideration is given to an intraabdominal lipoma, though other neoplastic process (both benign and malignant) could be considered. The mass overall, has a more benign appearance. Fine-needle aspirate could be considered and should be considered to further characterize. A CT scan could also be considered to confirm any association with abdominal organs, but ultimately a surgical explore may be necessary for histopathology and removal.

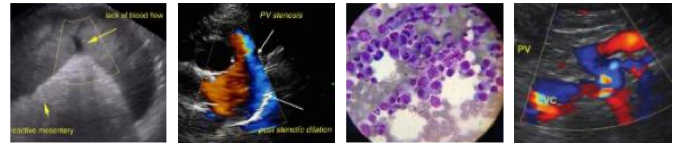
The stomach has a moderate volume of stagnant fluid, and measures towards the upper limit of normal, consistent with gastritis. There was very scant speckling in the duodenal mucosa, which may represent emerging enteropathy. Given the history of weight loss and polyphagia, consider further GI work-up, such as a GI panel, baseline cortisol and food trial, (if not contraindicated in this patient); also considerations for multiple disease processes to explain polyphagia with weight loss. It is difficult to know if the above mass is related to the clinical signs, given the lack of clearly identifiable organ origin, but fine-needle aspirate may elucidate.

**INVOICE**

12937

**DATE**

5.4.23



**PATIENT**

Piper Ferch

**SPECIES**

Canine

**BREED**

Terrier Mix

**SEX**

Spayed Female

**AGE**

13 years

**WEIGHT**

12.4 lbs

**INTERPRETED BY**

Jessica Midence, DVM,  
DACVIM (SAIM)

**IMAGING PERFORMED BY**

A. Murphy CVT

**HOSPITAL NAME**

Wauwatosa Vet

**REFERRING VET**

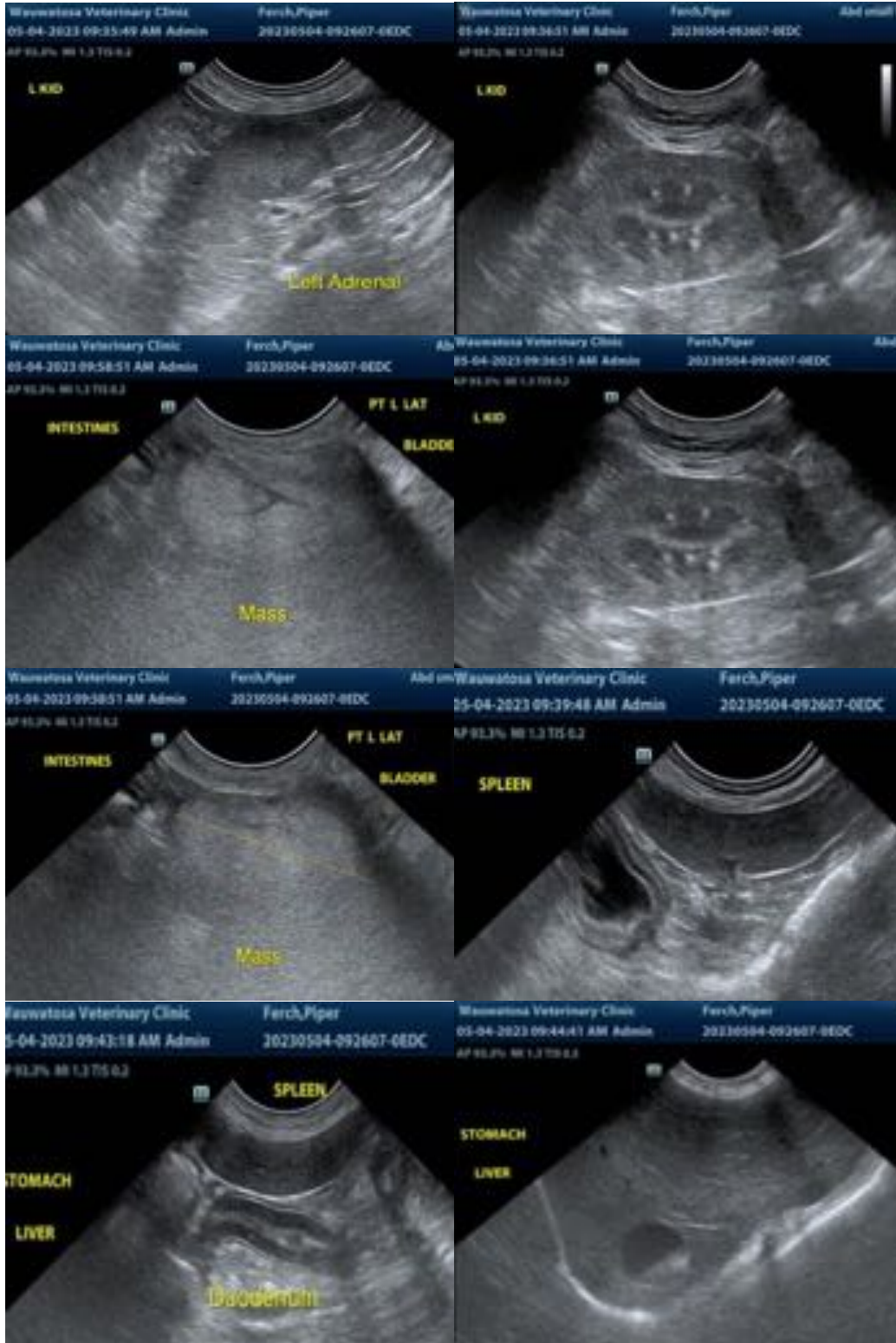
Dr Elaine Binor, DVM

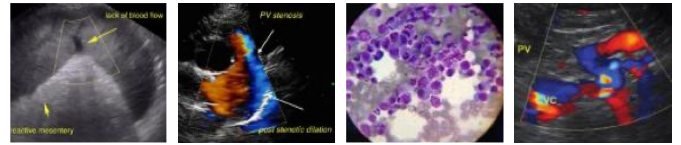
**INVOICE**

12937

**DATE**

5.4.23





**PATIENT**

Piper Ferch

**SPECIES**

Canine

**BREED**

Terrier Mix

**SEX**

Spayed Female

**AGE**

13 years

**WEIGHT**

12.4 lbs

**INTERPRETED BY**

Jessica Midence, DVM,  
DACVIM (SAIM)

**IMAGING PERFORMED BY**

A. Murphy CVT

**HOSPITAL NAME**

Wauwatosa Vet

**REFERRING VET**

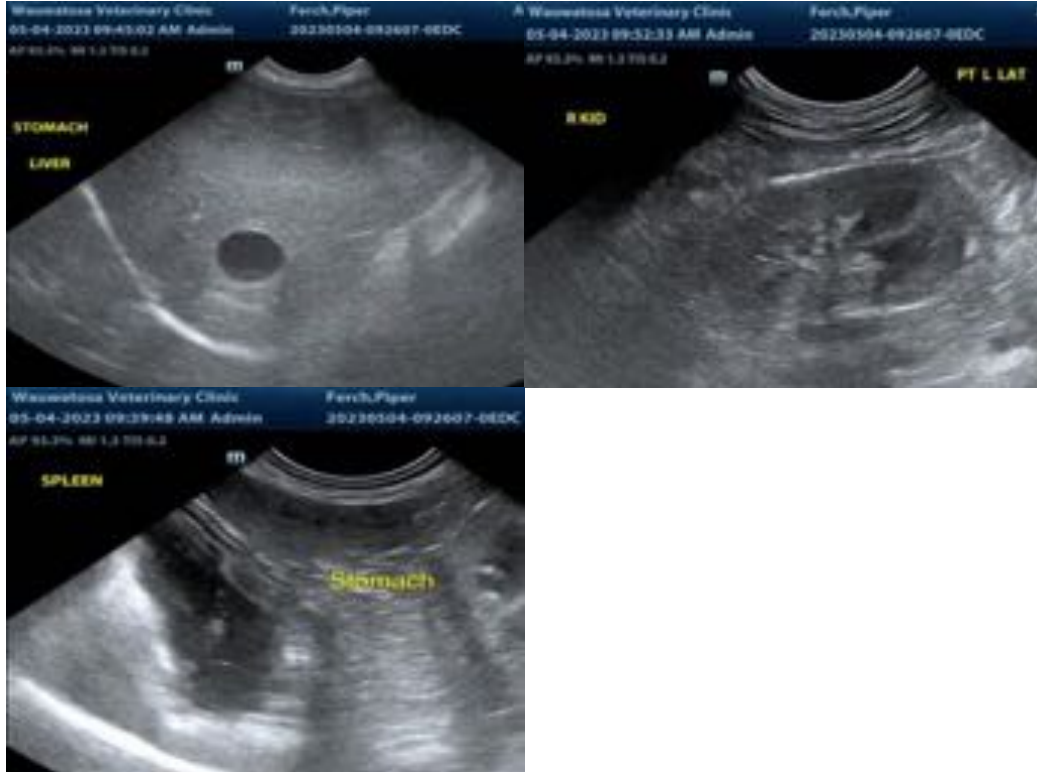Dr Elaine Binor, DVM

**INVOICE**

12937

**DATE**

5.4.23



The information and recommendations provided are based on the images presented by the referring veterinarian/sonographer. No evaluation can be communicated regarding pathology that was not visible in the image/video clips provided.

Thank you for this referral. If the clinical or image interpretation does not parallel your findings or if I can be of any further assistance, please contact me.

Jessica Midence, DVM, DACVIM (SAIM)  
info@SonoPath.com