

**DATE PRESENTING CLINICAL SIGNS**

4.28.2023 NAR, lethargic, urinating on herself.

PATIENT

Sophie Pezzella

Current Medications: None listed.
 Date of Previous IntraPet Ultrasound: No previous.
 Sedation: Declined. Not required to complete full diagnostic ultrasound.
 Stat Report: Declined.
 Imaging Performed By: Rachel Brillhart, RDMS.

SPECIES

Canine

BREED

Shih Tzu

SEX

Spayed Female

AGE

5/22/2012

WEIGHT

26.8lbs

INTERPRETED BY

Jessica Midence,
 DVM, DACVIM
 (SAIM)

HOSPITAL NAME

Animal MC of Bel Air

REFERRING VET

Dr. Chaudhry

INVOICE

12904

ULTRASONOGRAPHIC EXAMINATION OF THE ABDOMEN**Urinary System**

The urinary bladder mucosa, trigone, and visible urethra are normal in thickness and there is no evidence of mucosal irregularities. The bladder lumen is moderately distended with anechoic urine and bladder thickness is considered normal for volume of urine. There are several small, hyperechoic calculi (the largest measuring 0.17 cm at the trigone of the bladder).

The left kidney is normal in size (4.64 cm) shape and architecture with smooth peripheral margins. There is mildly decreased corticomedullary distinction and normal echogenicity, with some cortical nephrocalcinosis. There is a very small cortical cyst and pyelectasia (0.31 cm). There is peridiverticular mineralization.

The right kidney is normal in size (4.67 cm) with a slightly irregular shape (secondary to prior renal infarct) and normal architecture with smooth peripheral margins. There is decreased corticomedullary distinction and normal echogenicity, with several cortical cyst (the largest measuring 0.36 cm x 0.27 cm). There is scant pyelectasia and peridiverticular mineralization.

Adrenal Glands

The left adrenal gland appears to have two masses. The mass in the caudal pole (2.12 cm x 2.35 cm) has a mottled echotexture. A larger nodule/emerging mass in the cranial pole (1.42 cm x 1.41 cm) has a similar mottled echotexture.

The right adrenal gland is diffusely enlarged with a nodule on the cranial pole. The caudal pole measures more normal (0.60 cm thick) but is rounded and bulbous. The cranial pole is rounded and mildly mottled (1.56 cm x 1.18 cm) and has the appearance of an emerging mass.

Spleen

Arising from the tail of the spleen, there is a large splenic mass (5.77 cm x 4.20 cm) that is vascular and bulges the capsule significantly. The mass is mottled with mixed echotexture and both hyper- and hypoechoic regions, and an emerging hypoechoic cavitated portion at the periphery. There is scant anechoic effusion around the caudal edge of the mass and the spleen. The fat surrounding the mass is hyperechoic. The remainder of the splenic parenchyma appears homogenous and isoechoic to liver. Splenic vasculature is normal without signs of congestion or thrombosis.

Liver

The liver is subjectively normal in size with normal contours, structure, and smooth peripheral margins. The echogenicity appears hyperechoic with decreased portal markings. There is a subtle mottling to the echotexture. No overt evidence of infiltrative pathology is evident. The visible portions of the vasculature and biliary tract appear normal. No pathological hepatic lymphadenopathy observed.

The gallbladder lumen is moderately distended. The wall is a normal thickness and smooth. A scant amount of suspended echogenic debris is observed within the lumen. The cystic and common bile ducts are normal/not visible.

Gastrointestinal Tract

The gastric lumen is empty. The stomach wall is of normal wall thickness with some variability due to rugal folds. There is normal gastric wall layering. There are no masses or focal lesions observed and the pyloric outflow tract appears normal.

The visualized areas of duodenum, jejunum and ileum appear normal in thickness. The duodenum is normal with distinct wall layering. The remainder of the small intestines are normal with normal wall layering. The lumen of the small intestine was empty with no signs of ileus, obstruction or foreign material. No focal lesions observed.

The sections of colon are visualized with formed fecal material and gas shadowing distally.

Pancreas

The area of the pancreas is normal and isoechoic to surrounding mesentery. There is no evidence of nodules or cystic lesions. There is no evidence of regional mesenteric inflammation or fluid. The visible pancreatic duct was normal.

Peritoneum

Evaluation of the peritoneal cavity did not reveal any evidence of effusion, or subjective lymphadenomegaly. The omentum is of normal uniform echogenicity.

ULTRASONOGRAPHIC FINDINGS

Findings

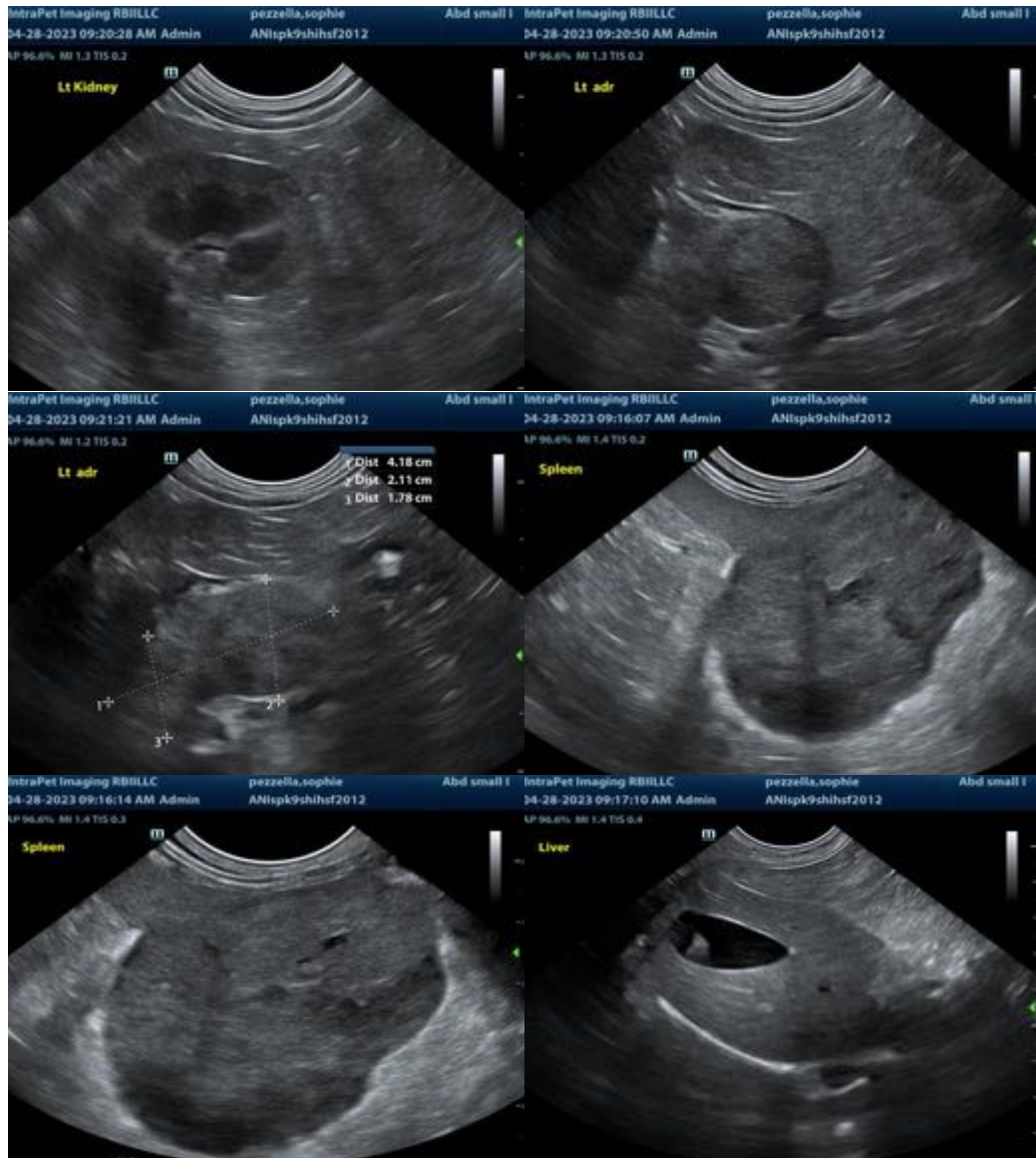
- Splenic mass with smaller areas of cavitation, regional effusion and inflammation
- Left adrenal gland masses
- Right adrenal nodule, emerging mass
- Chronic degenerative renal changes with nephrocalcinosis and mineralization
- Small cystoliths
- Hyperechoic mottled liver

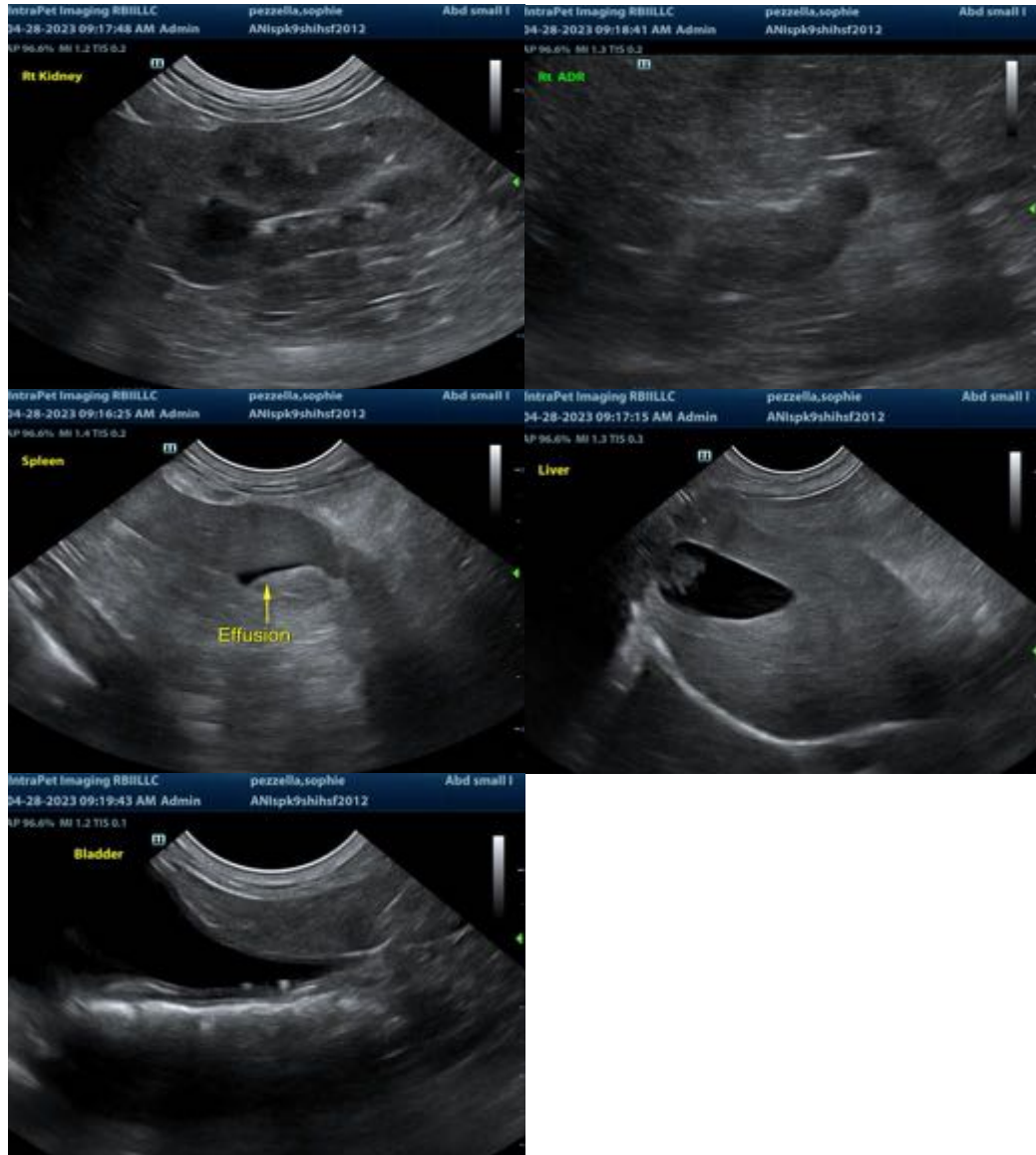
INTERPRETATION OF THE FINDINGS & FURTHER RECOMMENDATIONS

The splenic mass is concerning for malignancy given the regional inflammation and effusion. Fine-needle aspirate could be considered or splenectomy for definitive histopathology. Hemangiosarcoma, histiocytic sarcoma or other stromal cell sarcoma, as well as round cell neoplasia would be considered vs benign differentials (hematoma, complex lymphoid hyperplasia, etc.).

The left adrenal gland appears to have two separate masses, one at the cranial pole and one at the caudal pole. A functional or non-functional carcinoma or pheochromocytoma would be suspected over benign causes. The right adrenal gland also has a large nodule on the cranial pole, that has the appearance of an emerging mass (although it is <2.00 cm). Similar differentials as the left adrenal gland. Consider adrenal axis testing or urine metanephrine testing. These adrenal tumors are likely slow-growing and may be incidental to the presenting complaint. CT scan could be considered for further evaluation or surgical planning.

There are chronic degenerative renal changes. Consider routine monitoring of renal values to monitor progression, and a prescription renal diet (if not contraindicated in this patient). The bladder stones are small enough to be voided by the patient.





The information and recommendations provided are based on the images presented by the referring veterinarian/sonographer. No evaluation can be communicated regarding pathology that was not visible in the image/video clips provided.

Thank you for this referral. If the clinical or image interpretation does not parallel your findings or if I can be of any further assistance, please contact me.

Jessica Midence, DVM, DACVIM (SAIM)
info@SonoPath.com