

**DATE PRESENTING CLINICAL SIGNS**

4.20.2023 Chronic diarrhea for about 9m duration. Ropey intestines on PE.

PATIENT

Zebu Harty

Current Medications: None.

Lab Results: 0.1 low Albumin and slight globulin elevation on superchem/CBC/T4.

Date of Previous IntraPet Ultrasound: No previous.

Sedation: Not required to complete full diagnostic ultrasound.

Stat Report: Not requested.

Imaging Performed By: Rachel Brillhart, RDMS.

SPECIES

Feline

ULTRASONOGRAPHIC EXAMINATION OF THE ABDOMEN**BREED**

DSH

SEX

Neutered Male

AGE

5/1/2010

WEIGHT

6.5 lbs

Urinary System

The urinary bladder mucosa, trigone, and visible urethra are normal in thickness and there is no evidence of mucosal irregularities. The bladder lumen is mildly distended with anechoic urine and bladder thickness is considered normal for volume of urine.

The left kidney was enlarged (0.43 cm) but was otherwise normal in shape and architecture with smooth peripheral margins. There is mildly decreased corticomedullary distinction and normal echogenicity, though the cortex appears subjectively thickened. There is no evidence of pyelectasia, nephroliths, infarcts or hydroureter.

The right kidney was enlarged (0.43 cm) but was otherwise normal in shape and architecture with smooth peripheral margins. There is mildly decreased corticomedullary distinction and normal echogenicity, though the cortex appears subjectively thickened. There is no evidence of pyelectasia, nephroliths, infarcts or hydroureter.

Adrenal Glands

The left adrenal gland is normal in size 0.50 cm. The left adrenal gland has normal in shape and is normal in appearance and echogenicity.

The right adrenal gland is normal in size at 0.44 cm. The right adrenal gland has normal shape and it is normal in appearance and echogenicity.

Spleen

The splenic echotexture is homogeneous with parenchyma hyperechoic to liver and renal cortical parenchyma. The capsule is smooth with no irregularities. The splenic vasculature is normal without signs of congestion or thrombosis.

Liver

The liver is subjectively normal in size with normal contours, structure, with smooth peripheral margins. The echogenicity appears coarse. No overt evidence of inflammatory, infiltrative or regenerative pathology is evident. The visible portions of the vasculature and biliary tract appear normal. No pathological hepatic lymphadenopathy observed.

INTERPRETED BY

Jessica Midence,
DVM, DACVIM
(SAIM)

HOSPITAL NAME

Everhart VH

REFERRING VET

Dr. Farris

INVOICE

12814

The gallbladder lumen is mildly distended. The wall is a normal thickness and smooth. There is a collection of dependent echogenic debris at the neck of the gall bladder that appears a bit more organized/inspissated. The cystic and common bile ducts are normal/not visible.

Gastrointestinal Tract

The gastric lumen is empty. The stomach wall is of normal wall thickness with some variability due to rugal folds. There is normal gastric wall layering. There are no masses or focal lesions observed and the pyloric outflow tract appears empty.

The visualized areas of duodenum, jejunum and ileum appear diffusely thickened. The duodenal measures thick (0.37 cm) with distinct wall layering. The remainder of the small intestines also measure diffusely thickened, with the thickest measuring up to 0.44 cm). In some areas, the mucosa is quite thickened. In other loops of bowel, the muscularis layer is significantly thickened and approaching the same thickness as the mucosa. The lumen of the small intestine was mostly empty, though a few loops could contain some ingesta. No signs of ileus, obstruction or foreign material. The ileocecolic junction was visualized and had normal intact wall layering, and is subjectively thickened as well. The ileocecolic lymph nodes are significantly enlarged (one measuring 2.87 cm in length x 1.69 cm in width, and another measuring 1.89 cm in length x 1.38 cm in width). The lymph nodes are mildly hypoechoic surrounded by hyperechoic fat.

The sections of colon measured normal (0.14 cm) with incompletely-formed fecal material and gas shadowing distally. No observed focal or generalized colon wall thickness.

Pancreas

The left pancreas is elongated and a bit irregular. The pancreas is hypoechoic and measures mildly thickened in certain areas (up to 1.20 cm). The pancreatic duct was dilated (up to 0.22 cm) and at the body of the pancreas, up to 4.00 cm. There is no evidence of nodules or cystic lesions. There is no evidence of regional mesenteric inflammation or fluid. The visible pancreatic duct was normal.

Peritoneum

Evaluation of the peritoneal cavity shows there is scant effusion between the intestinal loops. The mesenteric lymph nodes are diffusely significantly enlarged and hypoechoic, but otherwise homogenous in echotexture. The mesentery is diffusely hyperechoic.

ULTRASONOGRAPHIC FINDINGS

Primary Findings

- Severe enteropathy with enlarged lymph node and scant effusion
- Pancreatitis
- Bilateral adrenomegaly with degenerative renal changes

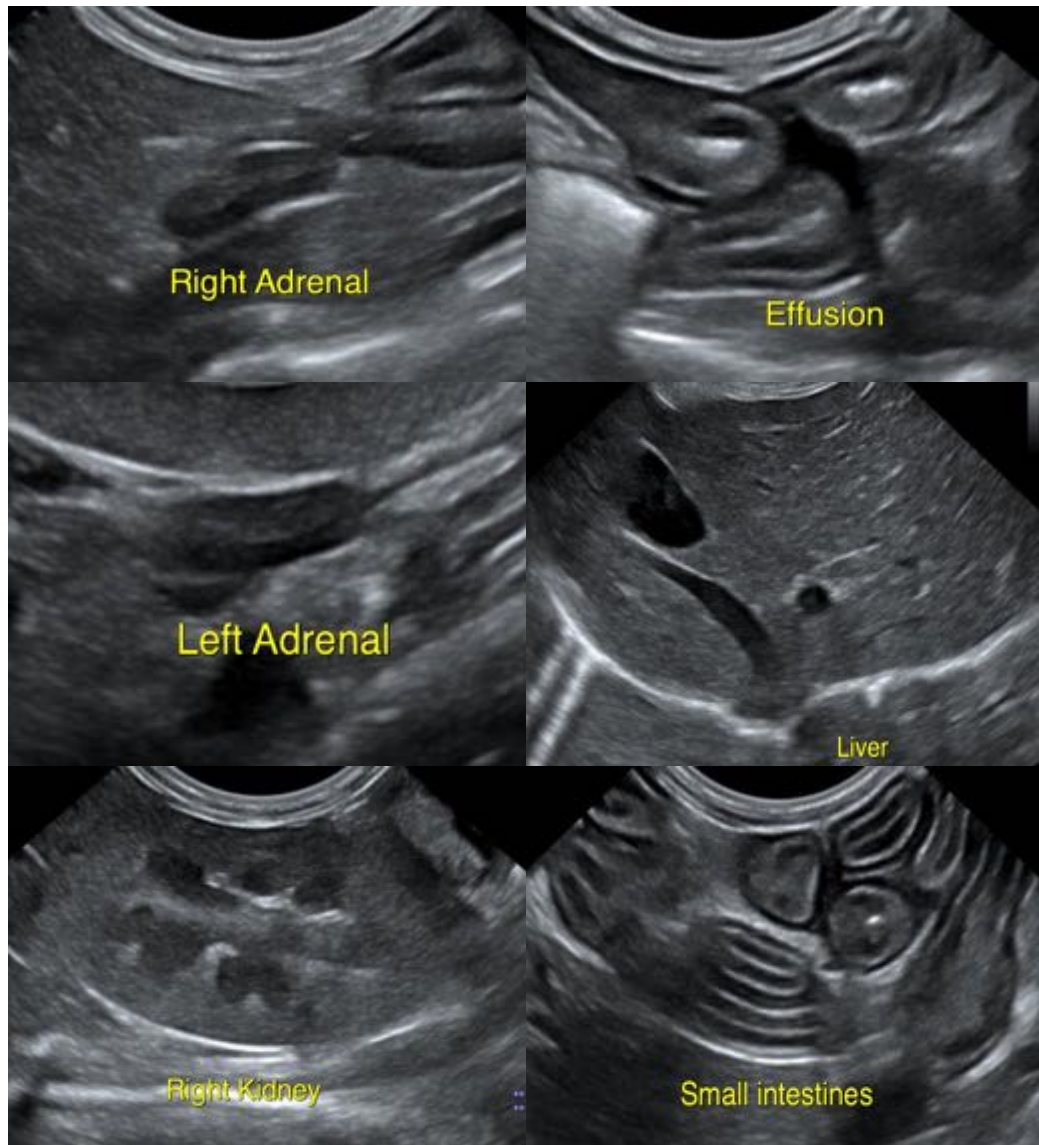
Secondary Findings

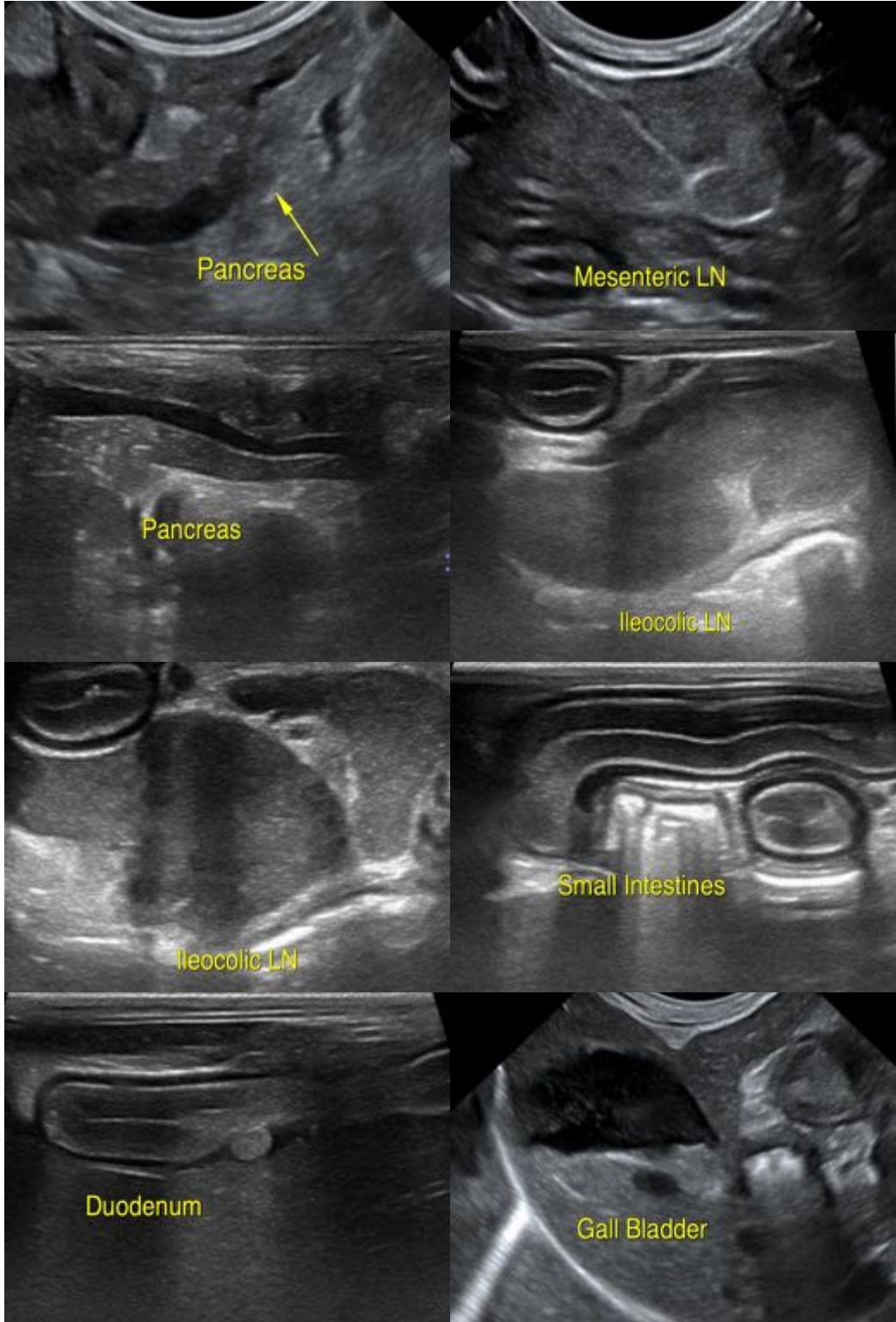
- Small volume of inspissated gall bladder sludge

INTERPRETATION OF THE FINDINGS & FURTHER RECOMMENDATIONS

The intestines are diffusely thickened with some segments of bowel measuring significantly thickened. There are focal areas of thickened muscularis, which would be consistent with a chronic enteropathy such as IBD, small cell lymphoma or even an emerging intermediate/large cell lymphoma. The mesenteric and ileocecolic lymph nodes are significantly enlarged, and the pancreas also has changes consistent with pancreatitis. The changes to the intestines are more severe, which raises concern for neoplasia. Unfortunately however, ultrasound alone cannot distinguish IBD from small cell lymphoma. Consider a GI panel, fine-needle aspirate of the ileocecolic lymph nodes or biopsies of the intestines (surgical versus endoscopic).

The changes to the kidney could be consistent with nephritis. Other causes of renomegaly (such as endocrinopathies) or perhaps emerging lymphoma (though there are no changes to suggest neoplasia on this evaluation, aside from the size of the kidneys). Fine-needle aspirate could be considered as well, but otherwise monitoring kidney values and urinalysis is recommended to evaluation for emerging renal disease and proteinuria.





The information and recommendations provided are based on the images presented by the referring veterinarian/sonographer. No evaluation can be communicated regarding pathology that was not visible in the image/video clips provided.

Thank you for this referral. If the clinical or image interpretation does not parallel your findings or if I can be of any further assistance, please contact me.

Jessica Midence, DVM, DACVIM (SAIM)
info@SonoPath.com