

**DATE PRESENTING CLINICAL SIGNS**

4.20.2023 Physical exam within normal limits. Elevated kidney values on pre surgical bloodwork.

PATIENT

Adeline Maralusha

Current Medications: Benazapril 5mg SID.
 Lab Results: BUN 28, Creat 1.9.
 Date of Previous IntraPet Ultrasound: No previous.
 Sedation: Not required to complete full diagnostic ultrasound.
 Stat Report: Not requested.
 Imaging Performed By: Rachel Brillhart, RDMS.

SPECIES

Canine

ULTRASONOGRAPHIC EXAMINATION OF THE ABDOMEN**BREED**

Greyhound

Urinary System

The urinary bladder mucosa, trigone, and visible urethra are normal in thickness and there is no evidence of mucosal irregularities. The bladder lumen is mildly distended with anechoic urine and bladder thickness is considered normal for volume of urine.

SEX

Spayed Female

The left kidney is normal in size, shape and architecture with smooth peripheral margins and measures 7.27 cm. There is normal corticomedullary distinction and normal echogenicity. There is no evidence of pyelectasia, nephroliths, infarcts or hydroureter.

AGE

10/22/2018

The right kidney is normal in size, shape and architecture with smooth peripheral margins and measures 6.90 cm. There is normal corticomedullary distinction and normal echogenicity. There is no evidence of pyelectasia, nephroliths, infarcts or hydroureter.

WEIGHT

63 lbs

Adrenal Glands

The left adrenal gland is normal in size (cranial pole 0.67 cm / caudal pole 0.65 cm). The left adrenal gland has normal in shape and is normal in appearance and echogenicity.

INTERPRETED BY

Jessica Midence,
 DVM, DACVIM
 (SAIM)

The right adrenal gland is normal in size (cranial pole 0.90 cm / caudal pole 0.56 cm). The left adrenal gland has normal in shape and is normal in appearance and echogenicity.

HOSPITAL NAME

Madonna VC

Spleen

The spleen measures thick (2.50 cm) with mildly rounded margins (though this is considered normal for the breed of the patient). The splenic echotexture is homogeneous with parenchyma hyperechoic to liver and renal cortical parenchyma. The capsule is smooth with no irregularities. The splenic vasculature is normal without signs of congestion or thrombosis.

REFERRING VET

12810

Liver

The liver is subjectively normal in size with normal contours, structure, with smooth peripheral margins. The echogenicity appears normal with normal portal markings. No overt evidence of inflammatory, infiltrative or regenerative pathology is evident. The visible portions of the vasculature and biliary tract appear normal. No pathological hepatic lymphadenopathy observed.

INVOICE

Dr. Brockett

The gallbladder lumen is moderately distended. The wall is a normal thickness and smooth. Luminal contents are anechoic. The cystic and common bile ducts are normal/not visible.

Gastrointestinal Tract

The gastric lumen is empty. The stomach wall is of normal wall thickness with some variability due to rugal folds. There is normal gastric wall layering. There are no masses or focal lesions observed and the pyloric outflow tract appears normal.

The visualized areas of duodenum, jejunum and ileum appear normal in thickness. The duodenum is normal with distinct wall layering. The remainder of the small intestines are normal with normal wall layering. The lumen of the small intestine was empty with no signs of ileus, obstruction or foreign material. No focal lesions observed.

The sections of colon are visualized with formed fecal material and gas shadowing distally.

Pancreas

The area of the pancreas is normal and isoechoic to surrounding mesentery. There is no evidence of nodules or cystic lesions. There is no evidence of regional mesenteric inflammation or fluid. The visible pancreatic duct was normal.

Peritoneum

Evaluation of the peritoneal cavity did not reveal any evidence of effusion, or subjective lymphadenomegaly. The omentum is of normal uniform echogenicity.

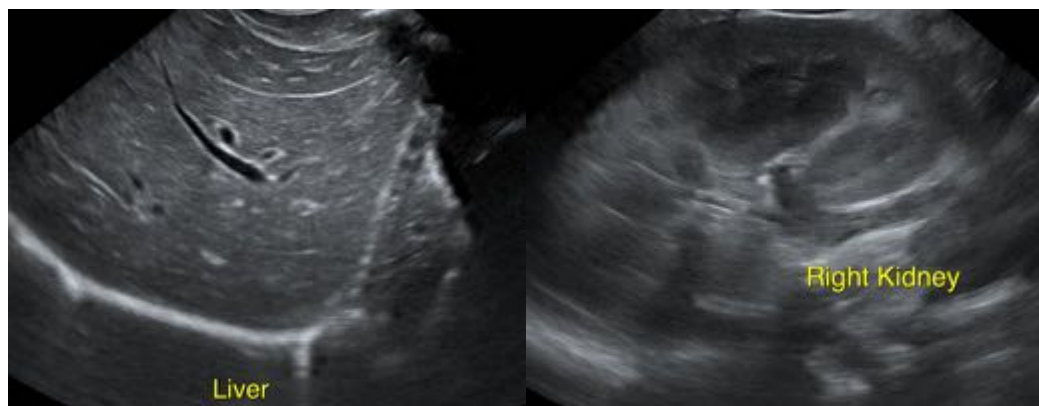
ULTRASONOGRAPHIC FINDINGS

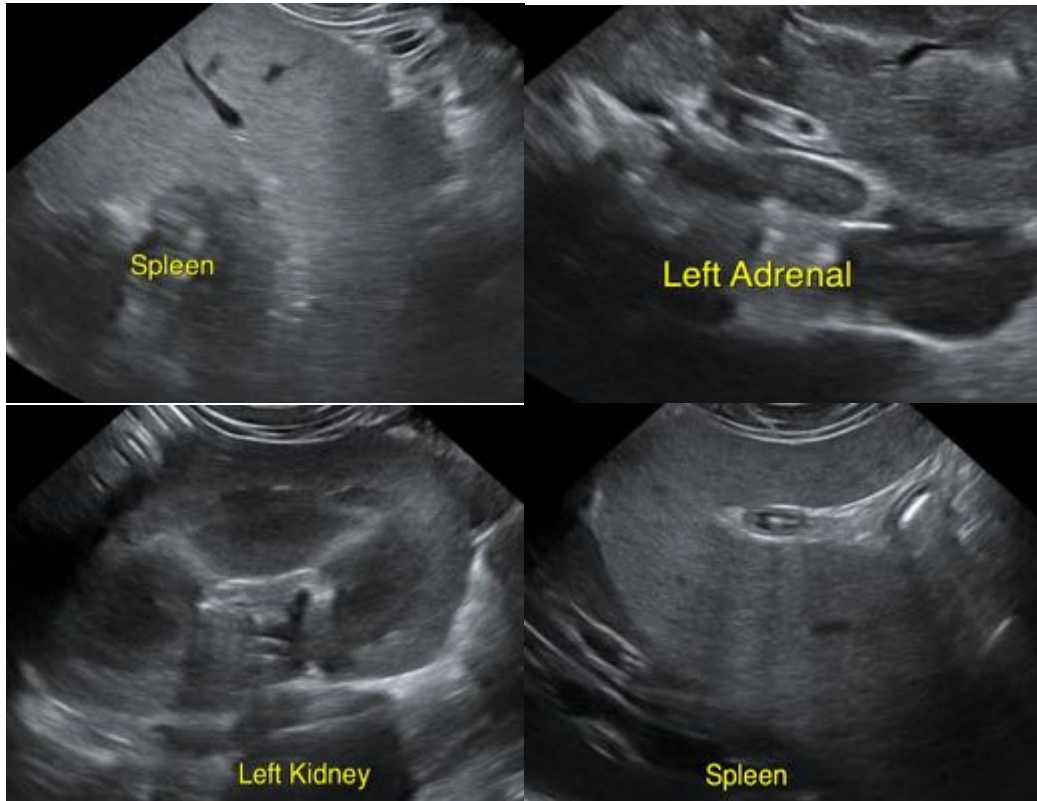
Findings

- Normal abdomen

INTERPRETATION OF THE FINDINGS & FURTHER RECOMMENDATIONS

The kidneys appear normal on this examination. The renal values are at the high end of normal for a Greyhound, though Greyhounds are a breed known to have a higher-than-normal creatinine concentration compared to other breeds (Correlate with urine specific gravity and continue to monitor the renal values over time. If the urine concentration supports decreased renal function, consider an early renal diet).





The information and recommendations provided are based on the images presented by the referring veterinarian/sonographer. No evaluation can be communicated regarding pathology that was not visible in the image/video clips provided.

Thank you for this referral. If the clinical or image interpretation does not parallel your findings or if I can be of any further assistance, please contact me.

Jessica Midence, DVM, DACVIM (SAIM)
info@SonoPath.com