

**DATE PRESENTING CLINICAL SIGNS**

3.31.23 Not feeling well several days and temperature 103.7 and fairly normal exam except somewhat large mass cranial to mid right abdomen palpated, low end PCV of 28-29 bilirubin 0.6 Chest RADS normal

PATIENT

Gillespie Massar

Current Medications: 3/29/23 Convenia 0.48mL, Onsior 6mg SID.

Lab Results: PCV 28, bilirubin 0.6.

Radiographs: Abdominal mass.

Date of Previous IntraPet Ultrasound: No previous.

Sedation: Not required to complete full diagnostic ultrasound.

Stat Report: Declined at this time.

Imaging Performed By: Stephanie Warga RDCS, RVT.

SPECIES

Feline

BREED

DSH

SEX

Neutered Male

AGE

8/20/2008

WEIGHT

9.5 lbs

INTERPRETED BYJessica Midence, DVM,
DACVIM (SAIM)**HOSPITAL NAME**Pleasantville AH
Fallston**REFERRING VET**

Dr. Gounaris

INVOICE

12608

ULTRASONOGRAPHIC EXAMINATION OF THE ABDOMEN**Urinary System**

The urinary bladder mucosa, trigone, and visible urethra are normal in thickness and there is no evidence of mucosal irregularities. The bladder lumen is moderately distended with anechoic urine although there is some dependent echogenic debris swirling in the bladder.

The left kidney is normal in size, shape and architecture with smooth peripheral margins and measures 3.49 cm. There is mildly decreased corticomedullary distinction and normal echogenicity. There is no evidence of pyelectasia, nephroliths, infarcts or hydroureter.

The right kidney is normal in size, shape and architecture with smooth peripheral margins and measures 3.90 cm. There is mildly decreased corticomedullary distinction and normal echogenicity. There is no evidence of pyelectasia, nephroliths, infarcts or hydroureter.

Adrenal Glands

The left adrenal gland is normal in size (0.33 cm). The left adrenal gland has normal in shape and is normal in appearance and echogenicity.

The right adrenal gland is normal in size (0.31 cm). The right adrenal gland has normal shape and it is normal in appearance and echogenicity.

Spleen

The splenic echotexture is homogeneous with hypoechoic parenchyma. The capsule is slightly undulating and the parenchyma appears to very slightly bulge the capsule. The spleen measures mildly thick (1.30 cm at the hilus). The fat and mesentery surrounding the spleen is hyperechoic. The liver is subjectively enlarged in size with normal contour, structure and smooth peripheral margins. Echogenicity appears hypoechoic with normal portal markings. The visible portions of the vasculature and biliary tract appear normal. The fat within the porta hepatis is hyperechoic and inflamed. There is a significantly enlarged hepatic lymph node that is rounded, hypoechoic and measures 2.58 cm x 1.10 cm.

Liver

The liver is subjectively normal in size with normal contours, structure, with smooth peripheral margins. The echogenicity appears normal with normal portal markings. No overt evidence of inflammatory, infiltrative or regenerative pathology is evident. The visible portions of the vasculature and biliary tract appear normal. No pathological hepatic lymphadenopathy observed.

The gallbladder lumen is mildly distended. The wall is a normal thickness and smooth. There is a small volume of dependent echogenic debris. The cystic and common bile ducts are normal/not visible.

Gastrointestinal Tract

The gastric lumen is empty. The stomach wall is of normal wall thickness with some variability due to rugal folds. There is normal gastric wall layering. There are no masses or focal lesions observed and the pyloric outflow tract appears empty.

The visualized areas of duodenum and most of the jejunum appear normal with distinct wall layering. There is a very large circumferential mass at the ileum that extends from the ileocecolic junction to the jejunum. The mass extends at least 7.85 cm. There is complete loss of layering and there is infiltration of the ileal wall (which is diffusely hypoechoic). The serosal surface is highly irregular. This mass measures up to 1.69 cm for one wall, but overall, it approaches 3.00 cm in width. The mesentery surrounding this mass is significantly hyperechoic with innumerable hypoechoic enlarged lymph nodes. The mesentery also appears hazy in some areas and thickened, suggestive of regional peritonitis and possible lesions. Further Orad from the ileum, there is a second area of small intestine where the intestinal wall is severely thick (up to 1.60 cm focally). It is difficult to tell if this a confluent with the ileal mass or a second, smaller intestinal mass (though the latter is suspected). The mesentery surrounding the second loop of bowel is also highly hyperechoic. The lymph nodes are all enlarged, rounded and hypoechoic.

The sections of colon are visualized with formed fecal material and gas shadowing distally.

Pancreas

The area of the pancreas is normal and isoechoic to surrounding mesentery. There is no evidence of nodules or cystic lesions. There is no evidence of regional mesenteric inflammation or fluid. The visible pancreatic duct was normal.

Peritoneum

There was scant effusion surrounding the ileal mass. There is diffuse severe mesenteric lymphadenopathy. The lymph nodes are all hypoechoic, rounded and significantly enlarged. The omentum appears nodular and thickened surrounding the mass.

ULTRASONOGRAPHIC FINDINGS

Primary Findings

- Very large ileocolic mass with surrounding peritonitis
- Suspected second small intestinal mass with surrounding peritonitis
- Metastatic abdominal lymph nodes (mesenteric, ileocolic and hepatic)
- Hypoechoic splenomegaly

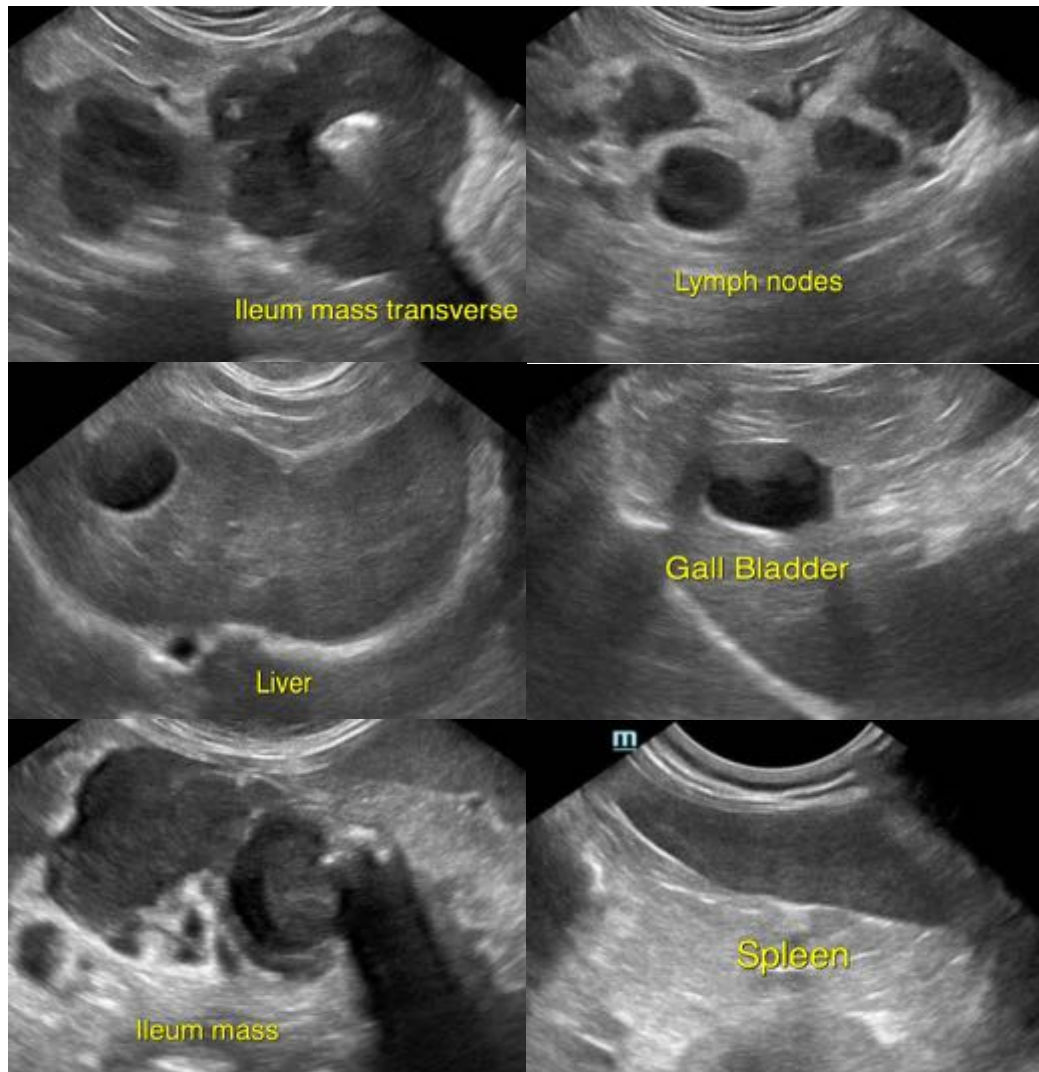
Secondary Findings

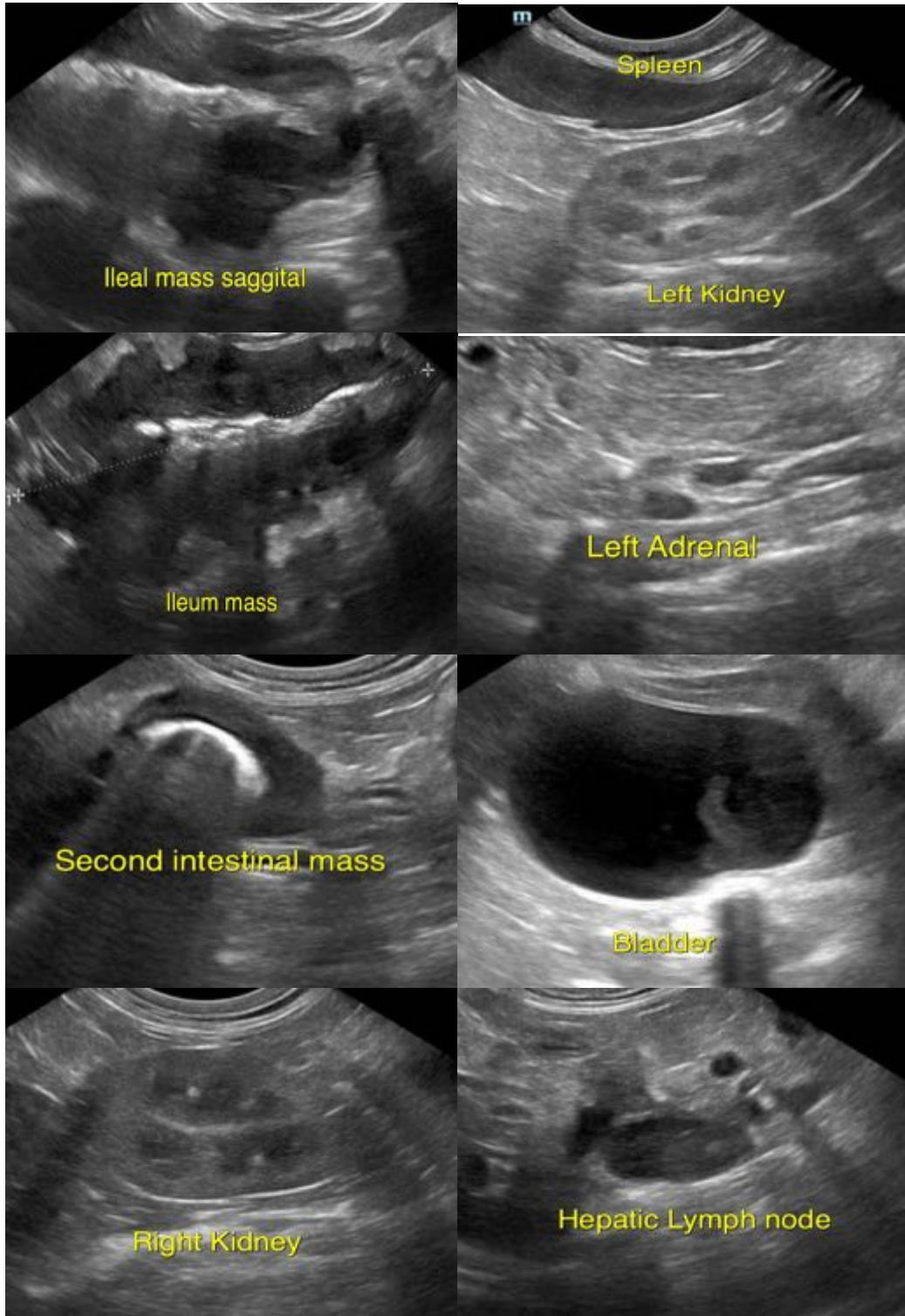
- Hypoechoic hepatomegaly
- Gall bladder sludge

INTERPRETATION OF THE FINDINGS & FURTHER RECOMMENDATIONS

The mass at the ileum would be amenable to fine-needle aspiration for diagnostics, though differentials include large cell lymphoma mast cell tumor, carcinoma or other malignant neoplasias. The surrounding mesentery is highly reactive and appears adherent to the area, raising concern for regional peritonitis. The

lymph nodes surrounding this area and in the mesentery are highly concerning for metastasis, given their appearance. There appears to be a second smaller mass just Oral to the ileal mass, but it is possible that this mass is confluent with the ileal mass and there is only one. The appearance of the spleen could be consistent with EMH lymphoid hyperplasia or splenitis, given the regional peritonitis, though there is concern for infiltration. Consider fine-needle aspiration of the spleen as well. The liver is also mildly hypoechoic and enlarged, though there is significant inflammation surrounding the liver, so similar to the spleen, it could be reactive to the other changes in the abdomen. But fine-needle aspiration could be considered to evaluate for infiltration as well.





The information and recommendations provided are based on the images presented by the referring veterinarian/sonographer. No evaluation can be communicated regarding pathology that was not visible in

the image/video clips provided.

Thank you for this referral. If the clinical or image interpretation does not parallel your findings or if I can be of any further assistance, please contact me.

Jessica Midence, DVM, DACVIM (SAIM)
info@SonoPath.com