



**PATIENT**

Willow Kopec

**SPECIES**

Feline

**BREED**

American Shorthair

**SEX**

Spayed Female

**AGE**

6 Years

**WEIGHT**

5.3 Pounds

**INTERPRETED BY**

Jessica Midence, DVM,  
DACVIM (SAIM)

**IMAGING  
PERFORMED BY**

Diane McFadden

**HOSPITAL NAME**

Newton Vet Hospital

**REFERRING VET**

Dr. Wyman-Greenwald

**INVOICE**

46331

**DATE**

3/31/23

**PRESENTING CLINICAL SIGNS**

Vomiting/diarrhea. Hx of mesenteric LN mass and mass in pancreas/LN.

Abnormal PE/Chem/CBC/UA Results: ALB 2.1, WBC 31.4, RBC decr 45, HCT decr 24%, hemoglobin 8.7, neuts 24178, monos 1884

**ULTRASONOGRAPHIC EXAMINATION OF THE ABDOMEN**

**Urinary System**

The urinary bladder mucosa, trigone, and visible urethra are normal in thickness and there is no evidence of mucosal irregularities. The bladder lumen is mildly distended with anechoic urine and bladder thickness is considered normal for volume of urine. No masses, inflammatory changes or calculi are observed.

The left kidney is large in size, shape and architecture with smooth peripheral margins and measures 4.1 cm. There is normal corticomedullary distinction and normal echogenicity. There is no evidence of pyelectasia, nephroliths, infarcts or hydroureter.

The right kidney is large in size, shape and architecture with smooth peripheral margins and measures 4.29 cm. There is normal corticomedullary distinction and normal echogenicity. There is no evidence of pyelectasia, nephroliths, infarcts or hydroureter.

**Adrenal Glands**

The left adrenal gland is normal in size (0.49 cm). The left adrenal gland has normal shape and it is normal in appearance and echogenicity.

The right adrenal gland is slightly enlarged at 0.61 cm, likely secondary to chronic physiologic stress. The right adrenal gland has normal shape and it is normal in appearance and echogenicity.

**Spleen**

The splenic echotexture is mildly mottled. It has a slightly scalloped edge, but otherwise the capsule is smooth with no irregularities. The splenic vasculature is normal without signs of congestion or thrombosis. The spleen measures 0.70 cm.

**Liver**

The liver is subjectively normal in size with normal contours, structure, with smooth peripheral margins. The echogenicity appears hyperechoic with decreased portal markings. No overt evidence of inflammatory, infiltrative or regenerative pathology is evident. The visible portions of the vasculature and biliary tract appear normal. No pathological hepatic lymphadenopathy observed.

The gallbladder lumen is mildly distended. The wall is a normal thickness and smooth. Luminal contents are anechoic. The cystic and common bile ducts are normal/not visible.

**Gastrointestinal**

The gastric lumen is empty. The stomach wall is of normal wall thickness with some variability due to rugal folds. There is normal gastric wall layering. There are no masses or focal lesions observed and the pyloric outflow tract appears patent.

The visualized areas of duodenum, jejunum and ileum are diffusely thick. The duodenum measures up to 0.31 cm (normal is up to 0.24 cm). Areas of the jejunum measure up to 0.36 cm (normal is up to 0.25 cm). The ileum is eccentrically thickened up to 1.0 cm. It is the muscularis layer that is thick. The muscularis



**PATIENT**

Willow Kopec

layer is diffusely significantly thickened throughout the small intestine (similar thickness to the mucosa). Wall layering is preserved and distinct throughout. The lumen of the small intestine does intermittently contain ingesta.

**SPECIES**

Feline

The ileocolic junction was visualized and had normal intact wall layering. The ileocolic lymph nodes are hypoechoic and significantly enlarged, the largest of which measures 1.3 cm x 0.90 cm.

**BREED**

American Shorthair

The colon is diffusely thickened, measuring up to 0.36 cm (normal is up to 0.17 cm). The muscularis layer is thickened, and in certain areas it is thicker than the mucosa. The entire colon is diffusely dilated with incompletely formed feces/diarrhea throughout.

**Pancreas**

**SEX**

Spayed Female

The area of the pancreas is normal and isoechoic to surrounding mesentery. There is no evidence of nodules or cystic lesions. There is no evidence of regional mesenteric inflammation or fluid. The visible pancreatic duct was normal.

**AGE**

6 Years

**Free Abdomen**

**WEIGHT**

5.3 Pounds

The entire mesentery and fat within the abdomen is hyperechoic. There are innumerable enlarged and hypoechoic lymph nodes. A perigastric lymph node measures 0.44 cm x 0.65 cm and is round and hypoechoic. In comparison to the images from 2020, this is the same perigastric lymph node that was before measured at 1.8 cm x 1.48 cm, so it is smaller on today's exam. Within the mid to caudal abdomen, what are presumed to be the mesenteric lymph nodes (though a highly complex mass involving associated lymph nodes would also be possible) are diffusely enlarged, complex in architecture, with hyper- and hypoechoic portions, and some appear to have hypoechoic nodules. There are portions of this cluster of lymph nodes that do appear mass-like, but this area is quite indistinct and difficult to discern the borders. This area was difficult to measure, given that the borders are so indistinct and complex, but it measures at least 4.0 cm x 4.2 cm. There are other more definitive/classic looking mesenteric lymph nodes that measure 0.92 cm thick by 3.7 cm in length. The fat surrounding these lymph nodes is hyperechoic. This cluster of lymph nodes is within the same area as the previously reported mesenteric lymph node mass, but in comparison with prior images, it looks significantly different.

**INTERPRETED BY**

Jessica Midence, DVM,  
DACVIM (SAIM)

**IMAGING PERFORMED BY**

Diane McFadden

**PRIMARY FINDINGS**

**HOSPITAL NAME**

Newton Vet Hospital

- Severe lymphadenopathy versus mesenteric mass with associated lymphadenopathy
- Significant intestinal and muscularis thickening throughout.

**REFERRING VET**

Dr. Wyman-Greenwald

**SECONDARY FINDINGS**

- Renomegaly
- Hyperechoic liver

**INVOICE**

46331

**DATE**

3/31/23

**INTERPRETATION OF THE FINDINGS & FURTHER RECOMMENDATIONS**

This study is compared to an ultrasound from 2020. The previously aspirated perigastric lymph node is still present and enlarged, though today is smaller, but similar in appearance. The appearance of the mesenteric lymph node mass is completely different today as compared to the previous study, so it is presumed to be progressive disease. The mesenteric lymph nodes are diffusely enlarged and complex, and there is a mass-like appearance, though it is indistinct and ill-defined. It is difficult to tell if this area constitutes a mass versus innumerable enlarged and abnormal mesenteric lymph nodes. This area is highly concerning for progression/transformation of the prior disease process into a neoplastic process such as lymphoma, mast cell tumor, histiocytic sarcoma, etc. Repeat FNA of this area is recommended, but surgical biopsy may be necessary for definitive diagnosis. A severe inflammatory granulomatous



**PATIENT**

Willow Kopec

**SPECIES**

Feline

**BREED**

American Shorthair

**SEX**

Spayed Female

**AGE**

6 Years

**WEIGHT**

5.3 Pounds

**INTERPRETED BY**

Jessica Midence, DVM,  
DACVIM (SAIM)

**IMAGING PERFORMED BY**

Diane McFadden

**HOSPITAL NAME**

Newton Vet Hospital

**REFERRING VET**

Dr. Wyman-Greenwald

**INVOICE**

46331

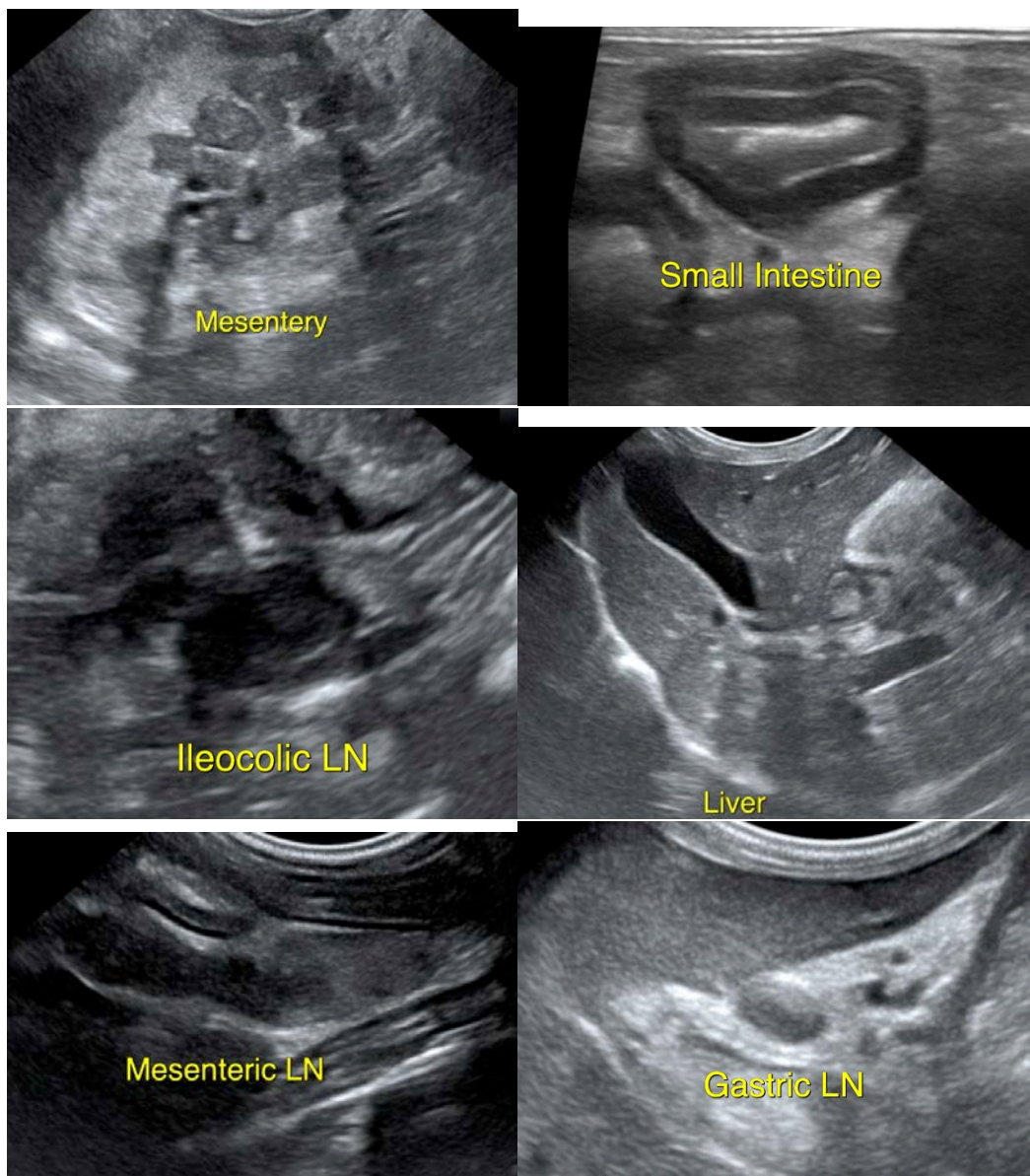
**DATE**

3/31/23

condition (infectious or inflammatory) is also possible but considered less likely.

The intestines are diffusely thickened, particularly the muscularis layer, which supports a chronic enteropathy such as inflammatory bowel disease, small cell lymphoma, or intermediate to large cell lymphoma, given the other changes in the abdomen. Consider GI panel or intestinal biopsy to further characterize.

Lastly, the kidneys are large for this size patient, and they are measuring larger than in 2020. This raises concern for infiltrative disease of the kidneys as well, though sonographically they do not appear overtly infiltrated. FNA can be considered.





**PATIENT**

Willow Kopec

**SPECIES**

Feline

**BREED**

American Shorthair

**SEX**

Spayed Female

**AGE**

6 Years

**WEIGHT**

5.3 Pounds

**INTERPRETED BY**

Jessica Midence, DVM,  
 DACVIM (SAIM)

**IMAGING PERFORMED BY**

Diane McFadden

**HOSPITAL NAME**

Newton Vet Hospital

**REFERRING VET**

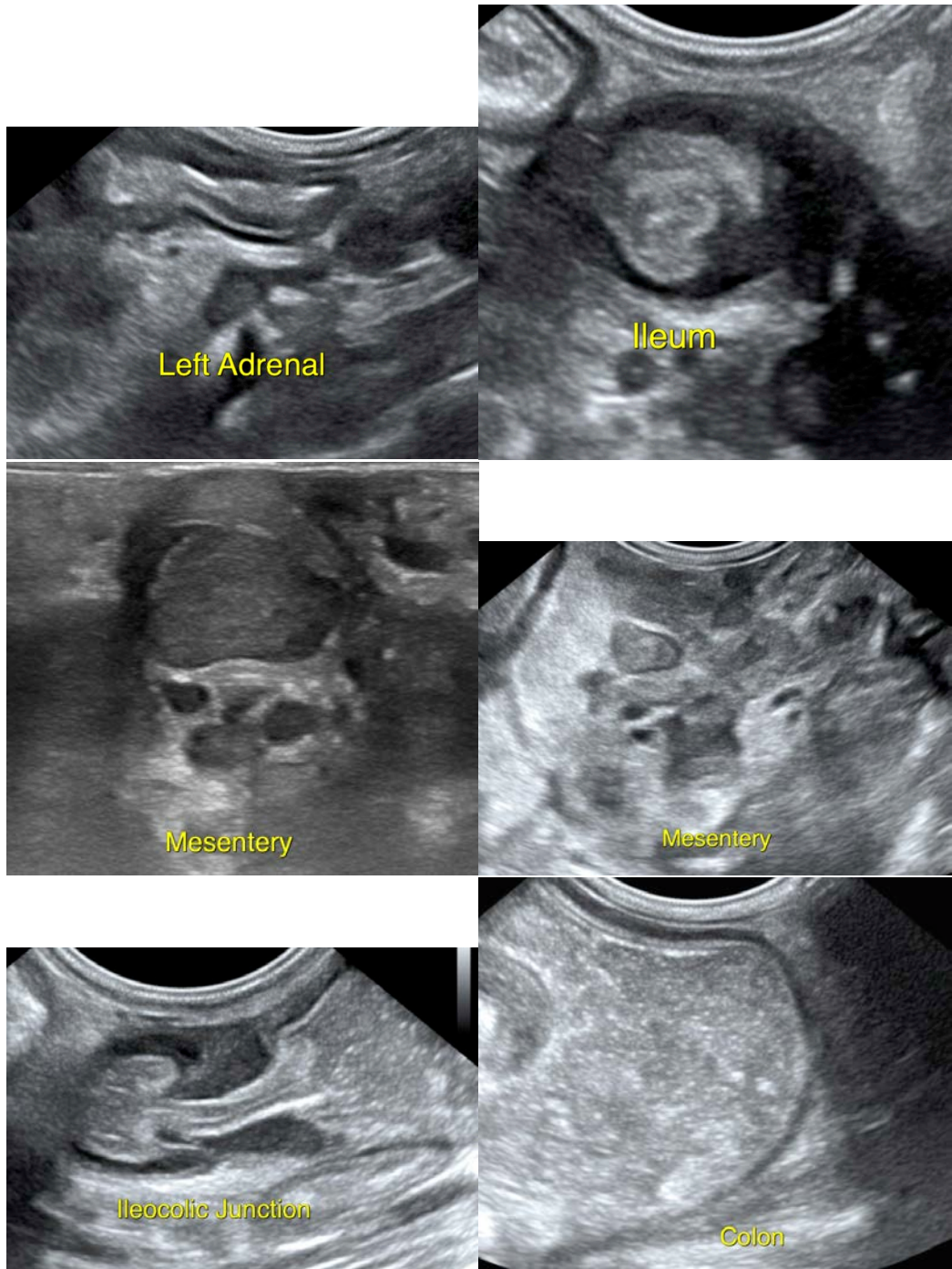
Dr. Wyman-Greenwald

**INVOICE**

46331

**DATE**

3/31/23





**PATIENT**

Willow Kopec

**SPECIES**

Feline

**BREED**

American Shorthair

**SEX**

Spayed Female

**AGE**

6 Years

**WEIGHT**

5.3 Pounds

**INTERPRETED BY**

Jessica Midence, DVM,  
DACVIM (SAIM)

**IMAGING  
PERFORMED BY**

Diane McFadden

**HOSPITAL NAME**

Newton Vet Hospital

**REFERRING VET**

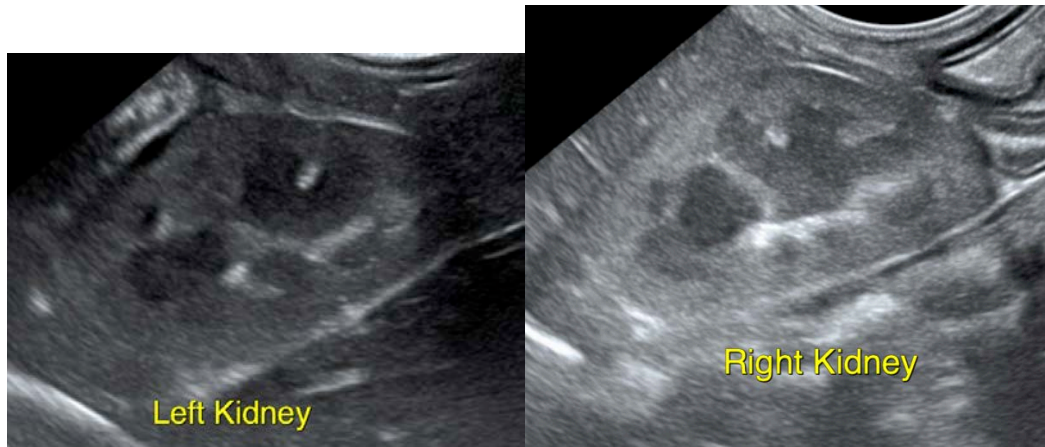
Dr. Wyman-Greenwald

**INVOICE**

46331

**DATE**

3/31/23



The information and recommendations provided are based on the images presented by the referring veterinarian/sonographer. No evaluation can be communicated regarding pathology that was not visible in the image/video clips provided.

Thank you for this referral. If the clinical or image interpretation does not parallel your findings or if I can be of any further assistance please contact me.

Jessica Midence, DVM, DACVIM (SAIM)

[info@SonoPath.com](mailto:info@SonoPath.com)