**DATE**

2/24/23

**PATIENT**

Dexter Simpson

**SPECIES**

Canine

**BREED**

Jack Russell

**SEX**

Netuered male

**AGE**

2/21/08

**WEIGHT**

27.9 lbs

**INTERPRETED BY**Jessica Midence, DVM,  
DACVIM (SAIM)**HOSPITAL NAME**Animal Emergency  
Hospital**REFERRING VET**

Dr. Nacke-Horney

**INVOICE**

42971

**PRESENTING CLINICAL SIGNS**

Around 5 days ago was seen by rdvm (animal medical center of bel air) - was dx with pancreatitis - started bland diet Ate one of the cans of food and then vomited - re-presented and rdvm gave dry dog food for GI tract - owner mixed boiled hamburger in with it Has continued to vomit and diarrhea - does drinking water but seems decreased Don't believe bloodwork was performed Current medication: - Metronidazole 250 mg, 1/2 tab q12 - last given: 8a - Cerenia 24 mg, 1 tab q24 - last given: 12p  
Current Medications: Purina EN, Metronidazole, Omeprazole, Gabapentin, Cerenia, Entyce, Ondansetron, Proviabie.

Lab Results: See attached.

Date of Previous IntraPet Ultrasound: No previous.

Sedation: Not required to complete full diagnostic ultrasound.

Stat Report: Not requested.

Imaging Performed By: Rachel Brillhart, RDMS.

**ULTRASONOGRAPHIC EXAMINATION OF THE ABDOMEN****Urinary System**

The urinary bladder mucosa, trigone, and visible urethra are normal in thickness and there is no evidence of mucosal irregularities. The bladder lumen is mildly distended with a large volume of anechoic urine and bladder thickness is considered normal for volume of urine.

The region of the prostate was normal.

The left kidney is normal in size, shape and architecture with smooth peripheral margins and measures 5.16 cm. There is normal corticomedullary distinction and normal echogenicity. There is no evidence of pyelectasia, nephroliths, infarcts or hydroureter.

The right kidney is normal in size, shape and architecture with smooth peripheral margins and measures 5.18 cm. There is normal corticomedullary. distinction and normal echogenicity. There is no evidence of pyelectasia, nephroliths, infarcts or hydroureter.

**Adrenal Glands**

The left adrenal gland is normal in size (cranial pole 0.48 cm, caudal pole 0.47 cm). The left adrenal gland has normal shape and it is normal in appearance and echogenicity.

The right adrenal gland is normal in size (0.58 cm caudal pole, 0.53 cm cranial pole). The right adrenal gland has normal shape and it is normal in appearance and echogenicity.

**Spleen**

The splenic echotexture is homogeneous with parenchyma hyperechoic to liver and renal cortical parenchyma. The capsule is smooth with no irregularities. The splenic vasculature is normal without signs of congestion or thrombosis.

**Liver**

The liver is diffusely enlarged and mottled/heterogenous, but overall the echotexture is hyperechoic. The contours are rounded, particularly the right liver lobe. There was a hyperechoic and homogenous liver mass in the right liver that measured 2.0 x 1.54 cm. Extending from the caudal border of the right liver there is portion of liver that measures 4.63 cm x 2.79 cm that has a subtly more mottled echotexture than the rest of the liver. This portion of liver is very rounded and gives the impression of a mass extending off the caudal edge of the liver. In certain ultrasound loops normal hepatic vessels can be seen both end on and longitudinal

though they are slightly bulged. There is a similar area in the cranial portion of the right liver that measures 4.27 cm x 1.85 cm, that is mottled and has a very rounded caudal border giving the impression of a possible mass though its borders are mostly indistinct from surrounding liver parenchyma.

The gallbladder had a moderate amount of semi-adherent echogenic debris. The wall measures normal at 0.24 cm, it is hyperechoic and prominent.

### ***Gastrointestinal Tract***

The gastric lumen is empty. The stomach wall is of normal wall thickness with some variability due to rugal folds. There is normal gastric wall layering. There are no masses or focal lesions observed and the pyloric outflow tract appears normal.

The visualized areas of duodenum, jejunum and ileum appear normal in thickness. The duodenum is normal with distinct wall layering. The remainder of the small intestines are normal with normal wall layering. Some loops of intestine measured thick up to 0.5 cm. The lumen of the small intestine was empty with no signs of ileus, obstruction or foreign material. No focal lesions observed.

The section of colon are visualized with incompletely formed feces and was mildly corrugated.

### ***Pancreas***

The pancreas was mildly hypoechoic and slightly prominent with scanty hyperechoic, bright fat surrounding it.

### ***Peritoneum***

Evaluation of the peritoneal cavity did not reveal any evidence of effusion, or subjective lymphadenomegaly. The omentum is of normal uniform echogenicity.

## **ULTRASONOGRAPHIC FINDINGS**

### ***Primary Findings***

1. Emerging or resolving mild pancreatitis.
2. Liver mass. One definitive liver mass with 2 other areas of possible larger liver masses
3. Hyperechoic, hepatomegaly.

### ***Secondary Findings***

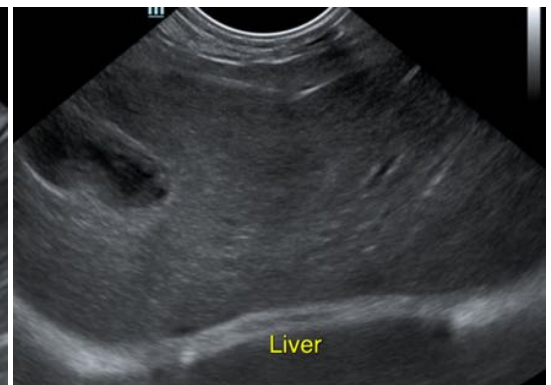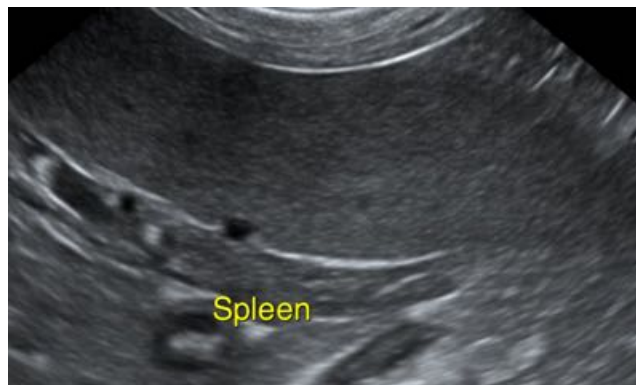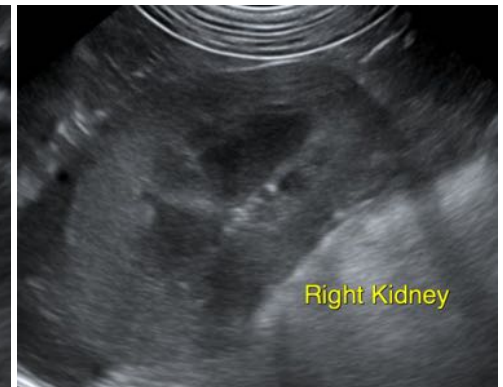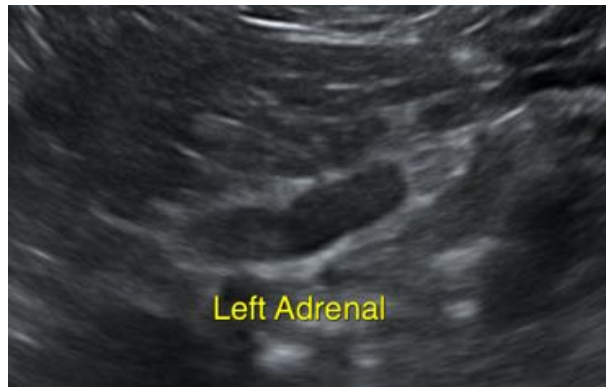
1. Possible cholecystitis.
2. Mild gastroenterocolitis.

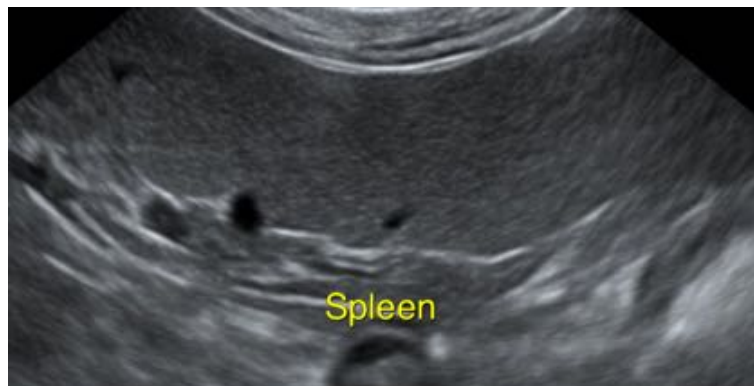
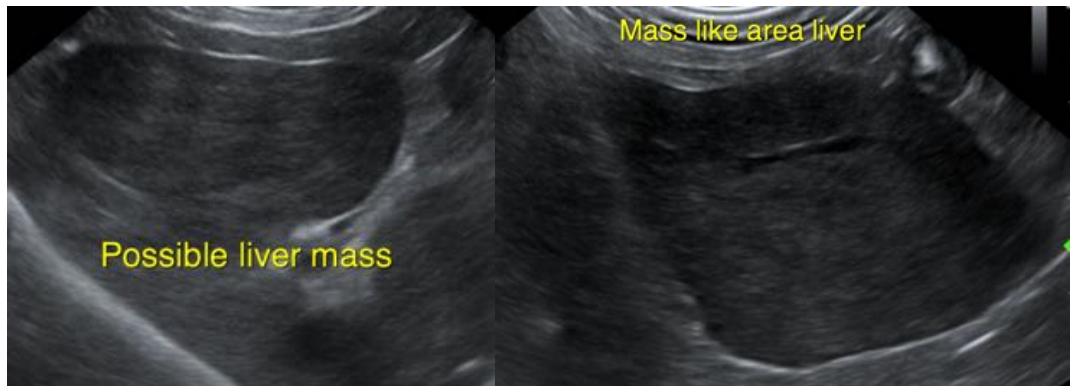
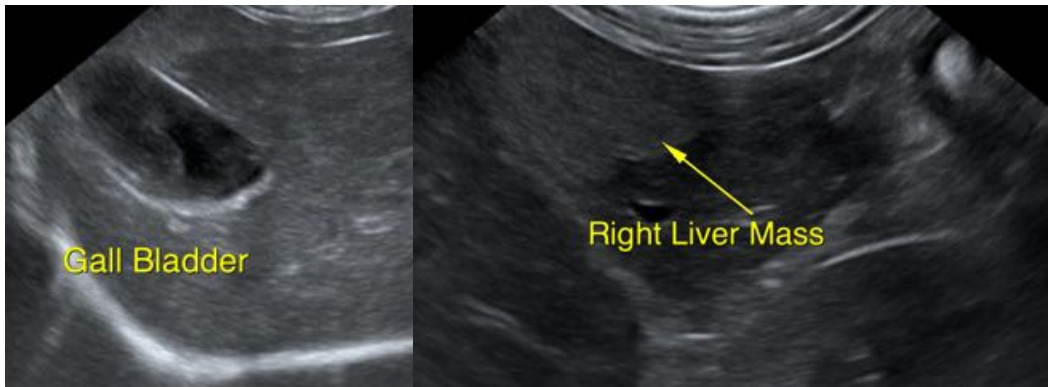
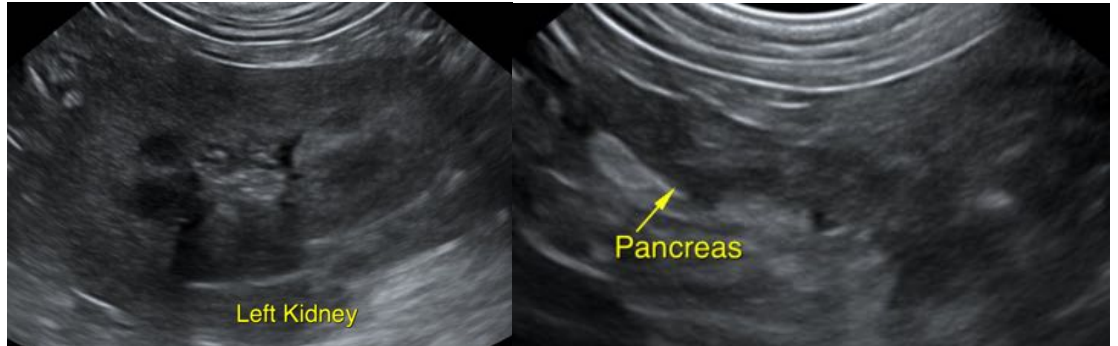
## **INTERPRETATION OF THE FINDINGS & FURTHER RECOMMENDATIONS**

The patient has evidence of mild pancreatitis and mild gastroenterocolitis. I recommend to continue treatment and consider in patient supportive care including intravenous fluids, anti-nausea medications, anti-diarrhea medications and appetite stimulants. The changes to the liver would be consistent with a vacuolar hepatopathy, but inflammatory or reactive hepatopathy or even round cell neoplasia cannot be excluded, yet not suspected from this exam.

There is one definitive liver mass in the right liver that is smaller than that is likely incidental and could be aspirated. There are 2 other areas within the right liver that certainly give the impression of a liver mass in that those portions of the liver are quite rounded and can be discreetly measured, however, other features of these areas preclude a definitive interpretation such as their appearance so similar to other portions of liver. Given the appearance of these areas, being quite similar to the more normal liver parenchyma, a large hepatoma or very slowly growing hepatocellular carcinoma would be considered most likely if they were neoplastic. These mass like areas are in a location amenable to fine needle aspiration. Alternatively, serial ultrasonographic monitoring could be considered. These masses are not inflamed and appear quiescent and are therefore also likely incidental to the presenting complaint.

The changes to the gallbladder are subtle, but the gallbladder wall is more prominent and hyperechoic than typical (though it still measures normal). Treatment for cholecystitis can be considered including Ursodiol and broader spectrum antibiotics if not contraindicated in this patient and not already initiated. If the patient fails to respond then aspirates of the liver parenchyma, gallbladder and liver mass should be considered.





**The information and recommendations provided are based on the images presented by the referring veterinarian. No evaluation can be communicated regarding pathology that was not visible in the image/video clips provided.**

Thank you for this referral. If the clinical or image interpretation does not parallel your findings or if I can be of any further assistance please contact me.

Jessica Midence, DVM, DACVIM (SAIM)  
info@SonoPath.com