



**PATIENT**

Dexter Cohn

**SPECIES**

Canine

**BREED**

Labrador Retriever X

**SEX**

Neutered Male

**AGE**

11 Years

**WEIGHT**

94 Pounds

**INTERPRETED BY**

Jessica Midence, DVM,  
DACVIM (SAIM)

**IMAGING PERFORMED BY**

Jessica Bailes

**HOSPITAL NAME**

All Creatures Great &  
Small Corvallis

**REFERRING VET**

Dr. Brent Sadahiro

**INVOICE**

44757

**DATE**

2/3/23

**PRESENTING CLINICAL SIGNS**

Hx of T - cell lymphoma and gastric leiomyoma. LSA controlled w/ pred and chlorambucil. Local oncology service recommended AUS to monitor disease process.

Abnormal PE/Chem/CBC/UA Results: NSF on PE BW done 12/22/22: Mild stress leukogram, otherwise NSF

**ULTRASONOGRAPHIC EXAMINATION OF THE ABDOMEN**

**Urinary System**

The urinary bladder mucosa, trigone, and visible urethra are normal in thickness and there is no evidence of mucosal irregularities. The bladder lumen is moderately distended with anechoic urine and bladder thickness is considered normal for volume of urine.

The left kidney is normal in size, shape and architecture with smooth peripheral margins and measures 7.5 cm. There is normal corticomedullary distinction and normal echogenicity. There is no evidence of pyelectasia, nephroliths, infarcts or hydroureter.

The right kidney is normal in size, shape and architecture with smooth peripheral margins and measures 8.32 cm. There is normal corticomedullary distinction and normal echogenicity. There is no evidence of pyelectasia, nephroliths, infarcts or hydroureter.

**Adrenal Glands**

The left adrenal gland is overall enlarged in size, measuring 1.2 cm at the caudal pole and 1.0 cm at the cranial pole. The overall shape and echogenicity are normal, though overall it is enlarged. Within the caudal pole, there is a single hyperechoic foci.

The right adrenal gland is normal in size at 0.62 cm at the caudal pole. The right adrenal gland has normal shape and it is normal in appearance and echogenicity.

**Spleen**

The splenic echotexture is homogeneous with parenchyma hyperechoic to liver and renal cortical parenchyma. The capsule is smooth with no irregularities. The splenic vasculature is normal without signs of congestion or thrombosis.

**Liver**

The liver is subjectively mildly enlarged and mildly hyperechoic, being isoechoic to the spleen in certain loops. Otherwise, the contour, structure, and portal markings are normal. No overt evidence of inflammatory, infiltrative, or regenerative pathology is evident. The visible portions of the vasculature and biliary tract appear normal. No pathological hepatic lymphadenopathy observed.

The gallbladder lumen is moderately distended. The wall is a normal thickness and smooth. Luminal contents are anechoic. The cystic and common bile ducts are normal/not visible.

**Gastrointestinal**

The stomach appears normal in all images reviewed and was empty. It measured normal at 0.36 cm. There are no masses or focal lesions observed and the pyloric outflow tract appears patent.



**PATIENT**

Dexter Cohn

The small intestine measures normal in all images reviewed and was diffusely empty. There are certain loops of bowel where the mucosa is subjectively slightly thicker than in other loops of bowel, but the overall width is well within normal range.

**SPECIES**

Canine

The section of colon are visualized with formed fecal material and gas shadowing distally. There is no observed focal or generalized colon wall thickening or loss of layering.

**BREED**

Labrador Retriever X

**Pancreas**

The area of the pancreas is normal and isoechoic to surrounding mesentery. There is no evidence of nodules or cystic lesions. There is no evidence of regional mesenteric inflammation or fluid. The visible pancreatic duct was normal.

**SEX**

Neutered Male

**Free Abdomen**

Evaluation of the peritoneal cavity did not reveal any evidence of effusion, or subjective lymphadenomegaly. The omentum is of normal uniform echogenicity.

**AGE**

11 Years

**PRIMARY FINDINGS**

- Normal gastrointestinal tract
- Left adrenomegaly with hyperechoic foci

**WEIGHT**

94 Pounds

**SECONDARY FINDINGS**

- Hyperechoic hepatomegaly – The diffuse hepatic changes are very mild and non-specific, though are most consistent with vacuolar hepatopathy (e.g., as would be expected with chronic corticosteroid use).

**INTERPRETED BY**

Jessica Midence, DVM,  
DACVIM (SAIM)

**INTERPRETATION OF THE FINDINGS & FURTHER RECOMMENDATIONS**

The appearance of the liver is non-specific and most consistent with chronic corticosteroid use. Inflammatory or infiltrative neoplasia cannot be ruled out, though are not suspected from this exam.

**IMAGING PERFORMED BY**

Jessica Bailes

The left adrenal gland is enlarged with a hyperechoic focus, which is particularly of noted, given chronic steroid use. Both adrenal glands maintain normal shape. Continue to monitor for development of symptoms of hyperadrenocorticism and continue to monitor the left adrenal gland by ultrasound to monitor progression of size and the hyperechoic focus.

**HOSPITAL NAME**

All Creatures Great &  
Small Corvallis

**REFERRING VET**

Dr. Brent Sadahiro

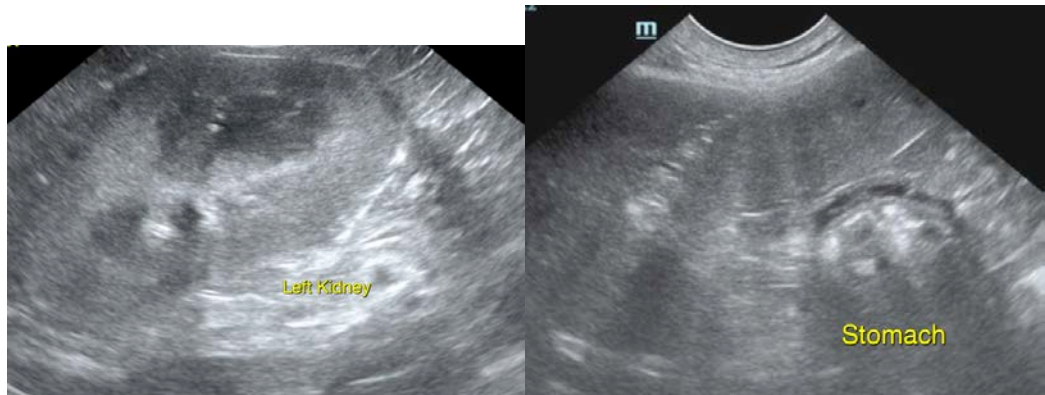
The gastrointestinal tract including the stomach are considered normal.

**INVOICE**

44757

**DATE**

2/3/23





**PATIENT**

Dexter Cohn

**SPECIES**

Canine

**BREED**

Labrador Retriever X

**SEX**

Neutered Male

**AGE**

11 Years

**WEIGHT**

94 Pounds

**INTERPRETED BY**

Jessica Midence, DVM,  
DACVIM (SAIM)

**IMAGING PERFORMED BY**

Jessica Bailes

**HOSPITAL NAME**

All Creatures Great &  
Small Corvallis

**REFERRING VET**

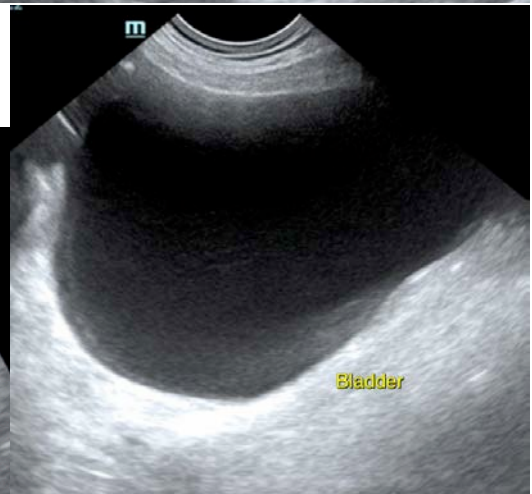
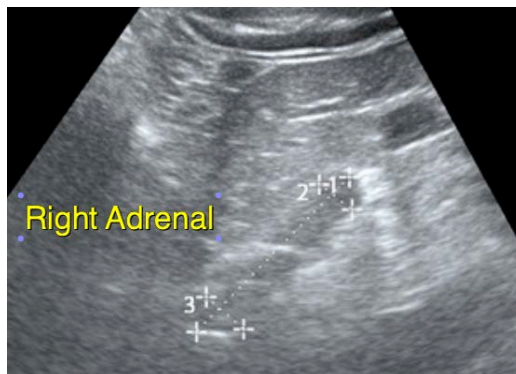
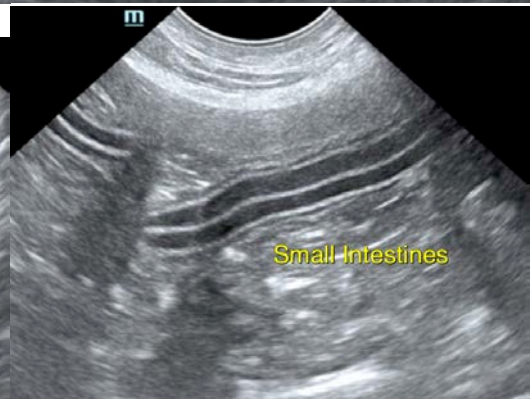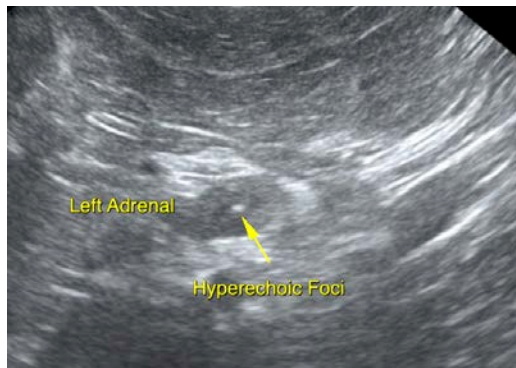
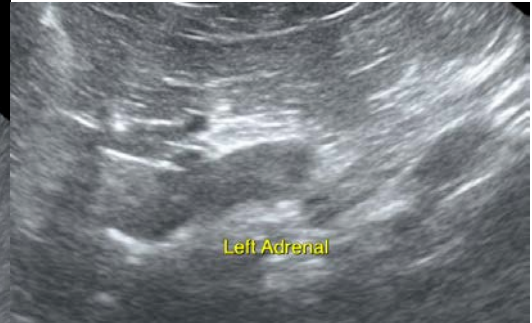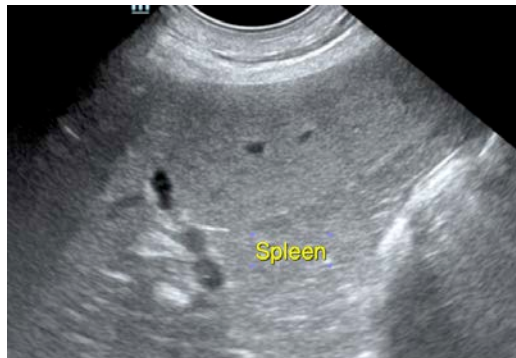Dr. Brent Sadahiro

**INVOICE**

44757

**DATE**

2/3/23



The information and recommendations provided are based on the images presented by the referring veterinarian/sonographer. No evaluation can be communicated regarding pathology that was not visible in the image/video clips provided.

Thank you for this referral. If the clinical or image interpretation does not parallel your findings or if I can be of any further assistance please contact me.

Jessica Midence, DVM, DACVIM (SAIM)

[info@SonoPath.com](mailto:info@SonoPath.com)