

PATIENT

Eli Coppens

SPECIES

Canine

BREED

Retriever Mix

SEX

Neutered male

AGE

3 years

WEIGHT

57.6 lbs

PRESENTING CLINICAL SIGNS

History: Chronic history of poor appetite and occasional loose stool. Elevated lipase on repeat blood panel. Screening for GI tract disease.

Abnormal PE/Chem/CBC/UA Results: Lipase 941 (ref range 0-250) Amylase 1533 (ref range 337-1469)

Right lateral radiograph and ventral dorsal radiograph were submitted for review. The right lateral radiograph shows evidence of small intestinal changes consistent with small intestinal gastroenteritis. There was completely formed feces in the colon, but otherwise, unremarkable.

ULTRASONOGRAPHIC EXAMINATION OF THE ABDOMEN

Urinary System

The urinary bladder mucosa, trigone, and visible urethra are normal in thickness and there is no evidence of mucosal irregularities. The bladder lumen is mildly distended with anechoic urine and bladder thickness is considered normal for a small volume of urine.

The left kidney is normal in size, shape and architecture with smooth peripheral margins and measures 6.3 cm. There is normal corticomedullary distinction and normal echogenicity. There is no evidence of pyelectasia, nephroliths, infarcts or hydroureter.

The right kidney is normal in size, shape and architecture with smooth peripheral margins and measures 6.8 cm. There is normal corticomedullary distinction and normal echogenicity. There is no evidence of pyelectasia, nephroliths, infarcts or hydroureter.

INTERPRETED BY

Jessica Midence, DVM,
DACVIM (SAIM)

IMAGING PERFORMED BY

A Murphy CVT

HOSPITAL NAME

Wauwautosa VC

REFERRING VET

Dr. Haynes

Adrenal Glands

The left adrenal gland is normal in size at 0.66 cm. The left adrenal gland has normal shape and it is normal in appearance and echogenicity.

The right adrenal gland is normal in size at 0.5 cm at the caudal pole and 0.51 cm at the cranial pole. The right adrenal gland has normal shape and it is normal in appearance and echogenicity.

Spleen

The head of the spleen was folded upon itself, yet otherwise the spleen appeared normal. The splenic echotexture is homogeneous with parenchyma hyperechoic to liver and renal cortical parenchyma. The capsule is smooth with no irregularities. The splenic vasculature is normal without signs of congestion or thrombosis.

Liver

The liver is subjectively normal in size with normal contours, structure, with smooth peripheral margins. The echogenicity appears normal with normal portal markings. No overt evidence of inflammatory, infiltrative or regenerative pathology is evident. The visible portions of the vasculature and biliary tract appear normal. No pathological hepatic lymphadenopathy observed.

INVOICE

42700

DATE

2/10/23

The gallbladder lumen is mildly distended. The wall is a normal thickness and smooth. A moderate volume of anechoic bile is noted. The cystic and common bile ducts are normal/not visible.



PATIENT

Gastrointestinal Tract

Eli Coppens

The gastric lumen is empty. The stomach wall is of normal wall thickness with some variability due to rugal folds. There is normal gastric wall layering. There are no masses or focal lesions observed and the pyloric outflow tract appears normal.

SPECIES

Canine

There were many loops of small intestine, although not all, that were mildly to moderately thickened with the jejunum having several loops that measured 0.53 cm (normal is up to 0.44 cm in this size dog). The thickness arises from mucosal thickening. The lumen of the small intestine was empty with no signs of ileus, obstruction or foreign material. .No focal lesions observed.

BREED

Retriever Mix

The section of colon are visualized with formed fecal material and gas shadowing distally.

SEX

Pancreas

Neutered male

The area of the pancreas is normal and isoechoic to surrounding mesentery. There is no evidence of nodules or cystic lesions. There is no evidence of regional mesenteric inflammation or fluid. The visible pancreatic duct was normal.

AGE

3 years

Peritoneum

WEIGHT

57.6 lbs

Evaluation of the peritoneal cavity did not reveal any evidence of effusion, or subjective lymphadenomegaly. The omentum is of normal uniform echogenicity.

INTERPRETED BY

ULTRASONOGRAPHIC FINDINGS

Jessica Midence, DVM,
DACVIM (SAIM)

Primary Findings

- Thickened intestines, consistent with acute or chronic gastroenteritis.

IMAGING PERFORMED BY

A Murphy CVT

HOSPITAL NAME

Wauwautosa VC

INTERPRETATION OF THE FINDINGS & FURTHER RECOMMENDATIONS

Multiple loops of small intestines displayed mucosal thickening causing overall mild to moderate increase in small intestinal thickening. The layering is preserved and there were no enlarged lymph nodes. While these ultrasound changes cannot distinguish between acute versus chronic gastroenteritis, given the history chronic enteropathy is suspected. Consider diet trial with novel protein, hypoallergenic diet protein or alimental protein as long as it is not contraindicated in this patient. Also consider baseline cortisol to rule out hypoadrenocorticism and a GI Panel. Endoscopy biopsies can also be considered.

REFERRING VET

Dr. Haynes

INVOICE

42700

DATE

2/10/23



PATIENT

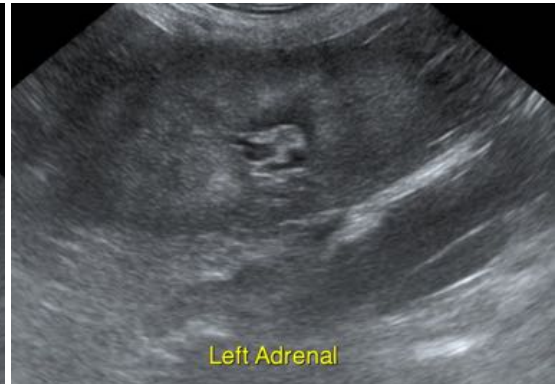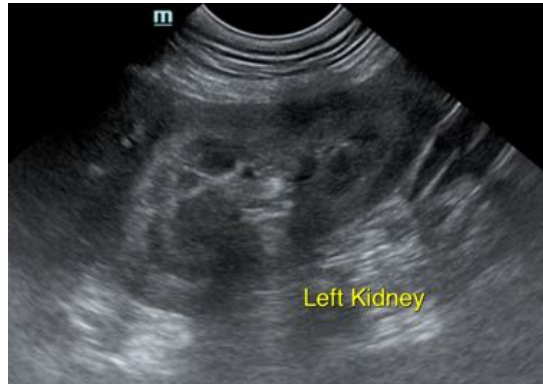
Eli Coppens

SPECIES

Canine

BREED

Retriever Mix



SEX

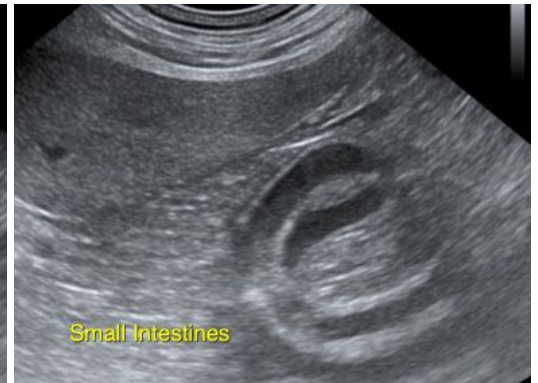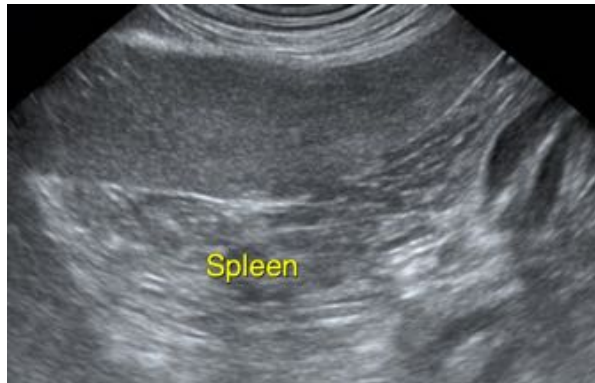Neutered male

AGE

3 years

WEIGHT

57.6 lbs



INTERPRETED BY

Jessica Midence, DVM,
DACVIM (SAIM)

IMAGING PERFORMED BY

A Murphy CVT

HOSPITAL NAME

Wauwautosa VC

REFERRING VET

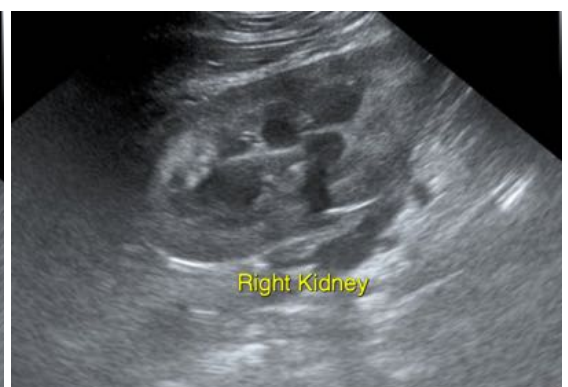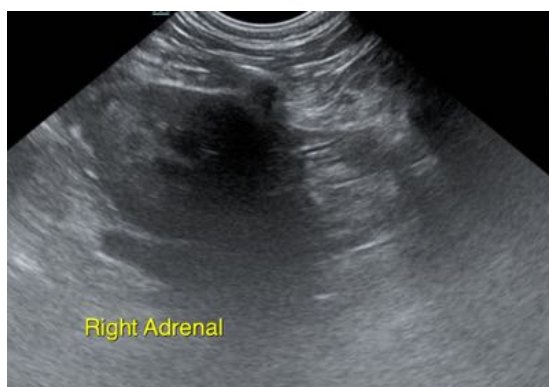
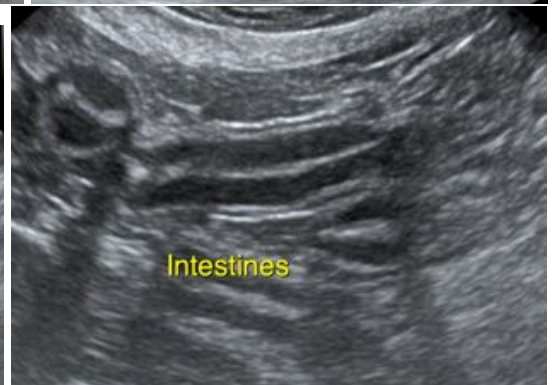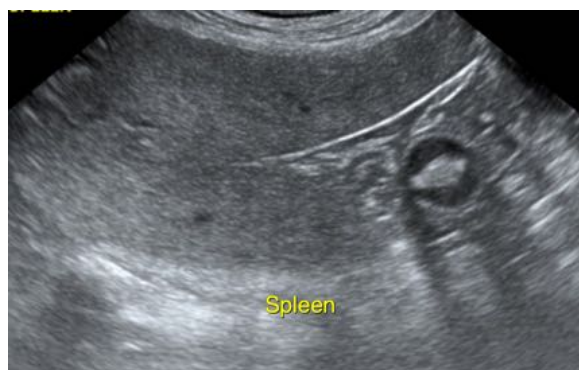Dr. Haynes

INVOICE

42700

DATE

2/10/23





PATIENT

Eli Coppens

SPECIES

Canine

BREED

Retriever Mix

SEX

Neutered male

AGE

3 years

WEIGHT

57.6 lbs

INTERPRETED BY

Jessica Midence, DVM,
DACVIM (SAIM)

**IMAGING
PERFORMED BY**

A Murphy CVT

HOSPITAL NAME

Wauwautosa VC

REFERRING VET

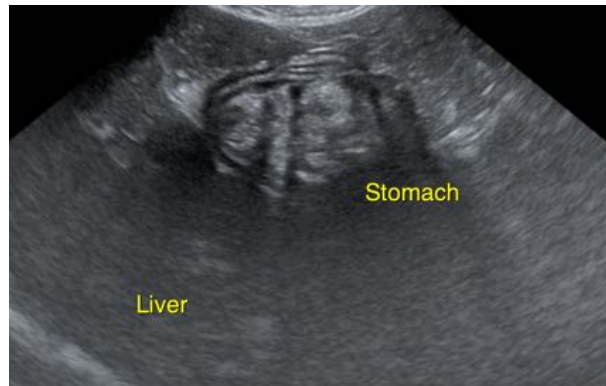
Dr. Haynes

INVOICE

42700

DATE

2/10/23



The information and recommendations provided are based on the images presented by the referring veterinarian/sonographer. No evaluation can be communicated regarding pathology that was not visible in the image/video clips provided.

Thank you for this referral. If the clinical or image interpretation does not parallel your findings or if I can be of any further assistance please contact me.

Jessica Midence, DVM, DACVIM (SAIM)
info@SonoPath.com