



PATIENT

Leica Stratakos

SPECIES

Canine

BREED

German Shepherd

SEX

Intact Male

AGE

5 Months

WEIGHT

31.4 Pounds

INTERPRETED BY

Jessica Midence, DVM,
DACVIM (SAIM)

IMAGING PERFORMED BY

Dr. Schanche

HOSPITAL NAME

TotalBond VH

REFERRING VET

Dr. Schanche

INVOICE

44402

DATE

1/20/23

PRESENTING CLINICAL SIGNS

Pt's presenting complain is inappetence and being underweight. Pt will eat a new food for a day or 2, but then stops wanting to eat. O will try mixing in different meats, cottage cheese, etc., and O still has no success with getting him to consistently eat. Pt appears to drink a lot, although O was not offering free choice water (drinking about 16 oz 3x/day) Defecates normally according to owner. On exam, pt is BCS 3/9 and cryptorchid (unilateral). Remainder of exam wnl.

Abdominal rads performed 1/18/22 - main conclusions: Mineral opaque GI foreign material. The gastric and small intestinal soft tissue is presumed to be food. Foreign material cannot be excluded. The abnormal small intestinal gas pattern indicates enteritis. Gastroenteritis or pancreatitis could account for the patient's inappetence and weight loss. The urinary bladder dilation is suspected to be transient and of no significance.

Performed an enema and administered SQ fluids on 1/18/22.

Labwork abnormalities from 1/18: Chem: BUN 68 high, creatinine 2.8 high, SDMA 33 high, Phosphorous 10.9 high, Calcium 12 high, CBC: WBC 16.2 high, lymphocytes 6642 high GI parasite PCR: none detected

ULTRASONOGRAPHIC EXAMINATION OF THE ABDOMEN

Urinary System

The urinary bladder mucosa, trigone, and visible urethra are normal in thickness and there is no evidence of mucosal irregularities. The bladder lumen is moderately distended with anechoic urine and bladder thickness is considered normal for volume of urine.

The kidneys display similar changes to one another. Both are small, with the left kidney measuring 5.43 cm in length and the right kidney measuring 5.13 cm in length. There is ill-defined corticomedullary distinction (though there is still some), and the overall renal architecture is moderately abnormal. There is a small cortical cyst in the left kidney and the suggestion of mild pyelectasia in certain views of the left kidney. The cortices of both kidneys appear mildly hyperechoic, and there appears to be cortical dystrophic mineralization.

Adrenal Glands

The left adrenal gland is normal in size at 0.89 cm long x 0.36 cm wide. The left adrenal gland has normal shape and it is normal in appearance and echogenicity.

The right adrenal gland is normal in size at 0.52 cm long x 0.48 cm wide. The right adrenal gland has normal shape and it is normal in appearance and echogenicity.

Spleen

The splenic echotexture is homogeneous with parenchyma hyperechoic to liver and renal cortical parenchyma. The capsule is smooth with no irregularities. The splenic vasculature is normal without signs of congestion or thrombosis.

Liver

The liver is subjectively normal in size with normal contours, structure, with smooth peripheral margins. The echogenicity appears normal with normal portal markings. No overt evidence of inflammatory, infiltrative or regenerative pathology is evident. The visible portions of the vasculature and biliary tract



PATIENT

Leica Stratakos

appear normal. No pathological hepatic lymphadenopathy observed. The fat within the portal hepatitis is moderately hyperechoic.

SPECIES

Canine

The gallbladder lumen is moderately distended. The wall is a normal thickness and smooth. Luminal contents are anechoic. The cystic and common bile ducts are normal/not visible.

BREED

German Shepherd

Gastrointestinal

The gastric lumen is empty. The stomach wall is of normal wall thickness measuring 0.43 cm with some variability due to rugal folds. There is normal gastric wall layering. There is mucosal mineralization in portions visualized. There are no masses or focal lesions observed and the pyloric outflow tract appears normal and patent, though the fat surrounding the pylorus and fundus of the stomach is moderately hyperechoic.

SEX

Intact Male

While the duodenum and some segments of jejunum measure normal, certain segments measure thick, up to 0.55 cm in the jejunum, with the mucosa generally thickened as well. Normal wall layering is maintained throughout. The lumen of the small intestines was empty with no signs of ileus, obstruction, or foreign material. No focal lesions observed.

AGE

5 Months

Pancreas

The right pancreas is mildly enlarged and hypoechoic with surrounding hyperechoic fat.

WEIGHT

31.4 Pounds

Free Abdomen

Evaluation of the peritoneal cavity did not reveal any evidence of effusion, or subjective lymphadenomegaly. The omentum is of normal uniform echogenicity.

INTERPRETED BY

Jessica Midence, DVM,
DACVIM (SAIM)

PRIMARY FINDINGS

- Chronic renal changes – consistent with congenital kidney disease/renal dysplasia.
- Uremic gastropathy with dystrophic mineralization of the mucosa

IMAGING PERFORMED BY

Dr. Schanche

SECONDARY FINDINGS

- Mild pancreatitis
- Mild enteritis

HOSPITAL NAME

TotalBond VH

INTERPRETATION OF THE FINDINGS & FURTHER RECOMMENDATIONS

REFERRING VET

Dr. Schanche

The changes to the kidneys are suggestive of a chronic kidney disease, most likely congenital (e.g., renal dysplasia), given their appearance and the age of the patient. There is a concurrent uremic gastropathy with dystrophic mineralization of the mucosa, as well as inflammation surrounding the stomach, pancreas, and porta hepatis. There is also mild enteritis. These changes are all likely secondary to the azotemia (e.g., uremia).

INVOICE

44402

DATE

1/20/23

A urinalysis and urine culture can be considered to rule out infection (though that is not suspected from the ultrasound). A UPC for proteinuria component, and Leptospirosis testing could be considered (though again, this is not suspected from the ultrasound). Treatment for uremia can be considered, including appetite stimulants, anti-nausea medications, antacid, phosphorus binders, and lower phosphorus diet labeled for growth (such as Royal Canin HP, Science Diet Large Breed Puppy, or Hills G/D) until the patient is full grown, then a renal diet should be considered.



PATIENT

Leica Stratakos

SPECIES

Canine

BREED

German Shepherd

SEX

Intact Male

AGE

5 Months

WEIGHT

31.4 Pounds

INTERPRETED BY

Jessica Midence, DVM,
DACVIM (SAIM)

IMAGING PERFORMED BY

Dr. Schanche

HOSPITAL NAME

TotalBond VH

REFERRING VET

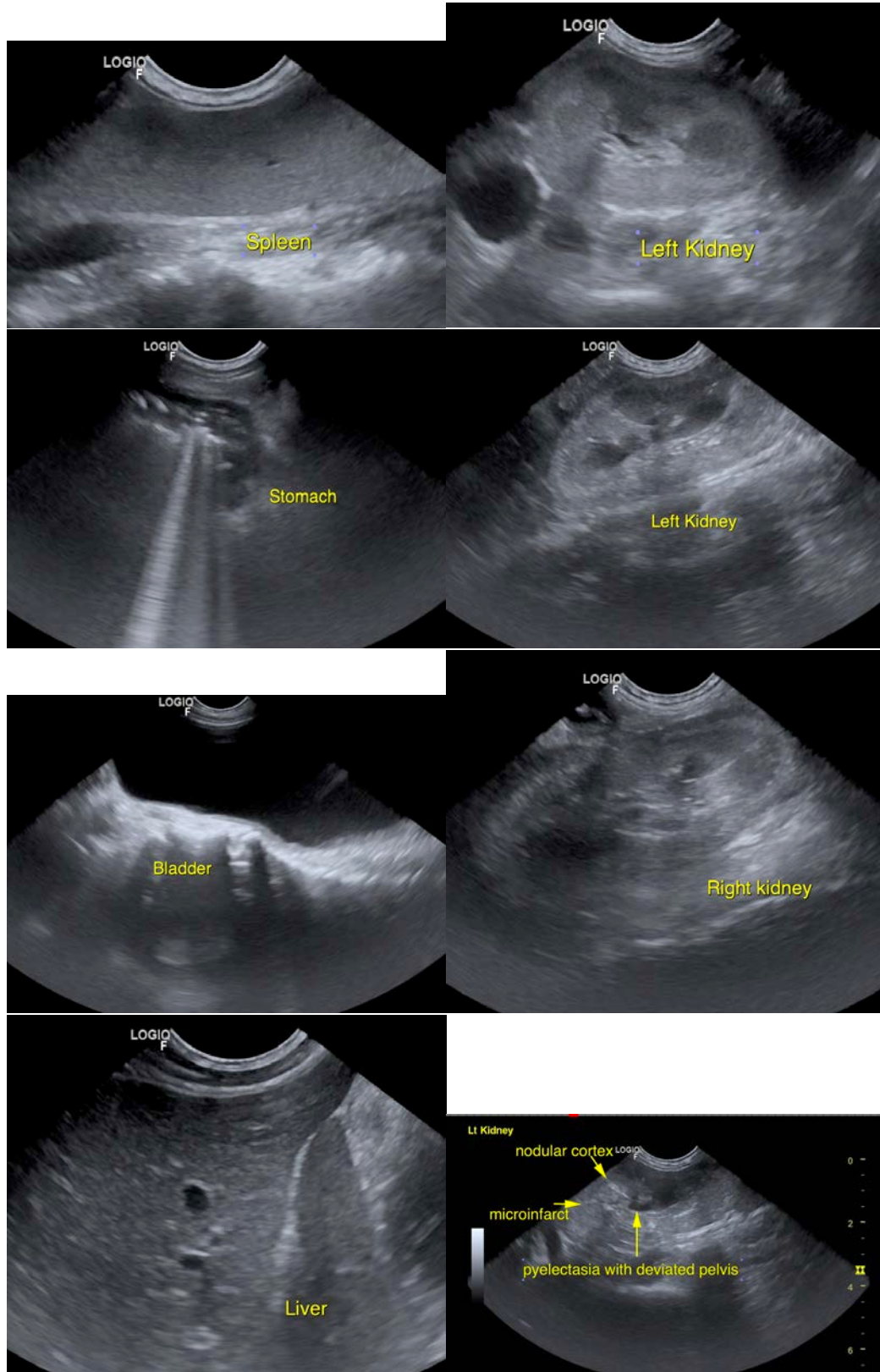
Dr. Schanche

INVOICE

44402

DATE

1/20/23





PATIENT

Leica Stratakos

SPECIES

Canine

BREED

German Shepherd

SEX

Intact Male

AGE

5 Months

WEIGHT

31.4 Pounds

INTERPRETED BY

Jessica Midence, DVM,
DACVIM (SAIM)

**IMAGING
PERFORMED BY**

Dr. Schanche

HOSPITAL NAME

TotalBond VH

REFERRING VET

Dr. Schanche

INVOICE

44402

DATE

1/20/23

The information and recommendations provided are based on the images presented by the referring veterinarian/sonographer. No evaluation can be communicated regarding pathology that was not visible in the image/video clips provided.

Thank you for this referral. If the clinical or image interpretation does not parallel your findings or if I can be of any further assistance please contact me.

Jessica Midence, DVM, DACVIM (SAIM)

info@SonoPath.com