



**PATIENT PRESENTING CLINICAL SIGNS**

Thor Wilcox History: lethargic and not eating not drinking, arches back when pets him ( maybe slipped disc) vomiting last time he eat was Wednesday  
Abnormal PE/Chem/CBC/UA Results: Unremarkable ALP is little high

**SPECIES RADIOGRAPHIC STUDY OF THORAX AND ABDOMEN**

Canine The body condition score is 5/9 with smooth alternating layers of fat and soft tissue opacity.

The bony structures appear physiological. No signs of aggressive osteolysis have been identified.

**BREED**

**Thorax**

Chihuahua

The lungs are in contact with the thoracic boundaries and the tips are pointed. The lobar vessels are clearly visible to the tertiary branches and have a physiological size.

**SEX**

Neutered Male

The cranial mediastinum is of physiological size and opacity. The trachea diverges slightly from the thoracic vertebrae and dips at the carina.

**AGE**

8 Years

The cardiac silhouette occupies 75% of the chest height and 2.5 intercostal spaces (VHS ). No chamber or outflow tract enlargement is evident.

**Abdomen**

**INTERPRETED BY**

The abdominal detail is good; diaphragm and abdominal wall are intact.

Heike Rudolf, DVM,  
Dr. med. Vet.,  
DipECVDI DVR

The liver is located within the costal arch and the caudo-ventral lobe is pointed.

The spleen appears physiological.

**HOSPITAL NAME**

St. Catharine's AH

Stomach and colon contain a small amount of gas; distribution and size of the small intestinal loops appear physiological.

Both renal shadows have a physiological size, shape and opacity; the bladder is small and of homogeneous fluid opacity. A prostatic shadow is not apparent.

**REFERRING VET**

Dr. Bekhit

The sublumbar region appears physiological.

**RADIOGRAPHIC DIAGNOSIS**

**INVOICE**

17258

- I can see no changes that explain the clinical signs

**INTERPRETATION OF THE FINDINGS & FURTHER RECOMMENDATIONS**

Full biochemistry will help identify if infection or inflammation are present (e.g. pancreatitis). Should all be normal, a full neurological examination may reveal signs compatible with disc disease.

**DATE**

9/9/22

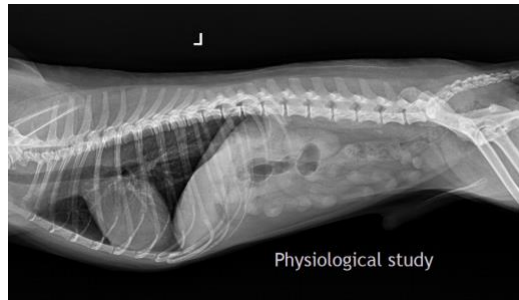


**PATIENT**

Thor Wilcox

**SPECIES**

Canine



**BREED**

Chihuahua

**The information and recommendations provided are based on the images presented by the referring veterinarian/sonographer. No evaluation can be communicated regarding pathology that was not visible in the image/video clips provided.**

**SEX**

Neutered Male

Thank you for this referral. If the clinical or image interpretation does not parallel your findings or if I can be of any further assistance please contact me.

**Heike Rudolf**, DVM, Dr. med. vet., DipECVDI, DVR  
dr.h.rudorf@gmail.com

**AGE**

8 Years

**INTERPRETED BY**

Heike Rudolf, DVM,  
Dr. med. Vet.,  
DipECVDI DVR

**HOSPITAL NAME**

St. Catharine's AH

**REFERRING VET**

Dr. Bekhit

**INVOICE**

17258

**DATE**

9/9/22