



PATIENT PRESENTING CLINICAL SIGNS

Ruairi Smith History: 2-3-week history of lameness. Abducts RF leg on extension No response to rimadyl Seems to be stiff after periods of rest

SPECIES RADIOGRAPHIC STUDY OF THE SHOULDERS

Canine Skeletal immaturity compatible with the given age is noted.

The bones are well mineralized, have a normal trabecular structure and smooth, continuous surfaces. Cortical-medullary development and differentiation of the long bones are physiological.

BREED

Golden Retriever The shoulder joints appear congruent with even subchondral bone surfaces. New bone formation is not apparent.

SEX RADIOGRAPHIC DIAGNOSIS

Male • I can see no changes that would explain the clinical signs

INTERPRETATION OF THE FINDINGS & FURTHER RECOMMENDATIONS

AGE The absence of boney abnormalities suggests a lesion further distally, e.g. elbow ED, or a muscle injury e.g. myositis or infraspinatus contracture. Should a CT examination of both elbows be unrewarding, this should be followed by a contrast CT to rule out flexor myositis.

6 Months

TECHNICAL COMMENTS

INTERPRETED BY Jpg images were submitted. The transformation from DICOM to other formats reduces the image quality and only allows limited manipulation of the image. More subtle lesions can thus easily be missed. For the best possible imaging reports, I suggest submitting DICOM images in the future.

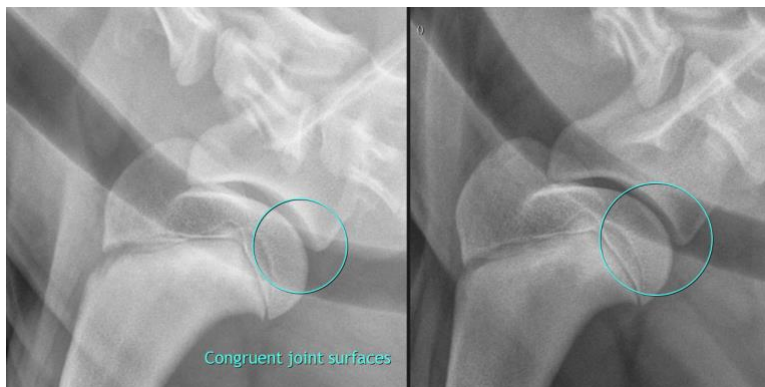
Heike Rudorf, DVM,
Dr. med. Vet.,
DipECVDI DVR

HOSPITAL NAME

Washington AH

REFERRING VET

Dr. Grodkiewicz



INVOICE

17256

The information and recommendations provided are based on the images presented by the referring veterinarian/sonographer. No evaluation can be communicated regarding pathology that was not visible in the image/video clips provided.

DATE

9/9/22



PATIENT

Thank you for this referral. If the clinical or image interpretation does not parallel your findings or if I can be of any further assistance please contact me.

Ruairi Smith

Heike Rudolf, DVM, Dr. med. vet., DipECVDI, DVR
dr.h.rudorf@gmail.com

SPECIES

Canine

BREED

Golden Retriever

SEX

Male

AGE

6 Months

INTERPRETED BY

Heike Rudolf, DVM,
Dr. med. Vet.,
DipECVDI DVR

HOSPITAL NAME

Washington AH

REFERRING VET

Dr. Grodkiewicz

INVOICE

17256

DATE

9/9/22