

**PATIENT**

Taggs Minnie

PRESENTING CLINICAL SIGNS

met check. has a mamm mass

SPECIES

Ca

RADIOGRAPHIC STUDY OF THE THORAX

RLR, LLR, DV

RADIOGRAPHIC FINDINGS**BREED**

Mix

The body condition score is 8/9 with smooth alternating layers of fat and soft tissue opacity.

The bony structures appear physiological.

SEX

FS

The lungs are in contact with the thoracic boundaries and the tips are pointed. The lobar vessels are clearly visible. The two main stem bronchi are slightly pushed laterally and appear curved. Oval, shaped soft tissue opacities are superimposed onto the base of the heart and caudal vena cava on the L lateral recumbent view.

AGE

8

The cranial mediastinum is of physiological size and opacity. The trachea diverges from the thoracic vertebrae and the carina is located at T4.

The cardiac silhouette occupies 75% of the chest height and 3 intercostal spaces (VHS); a mild bulging appears to be present at 3 o'clock and the caudal heart border appears to be straight.

INTERPRETED BY

Heike Rudolf, DVM,
Dr. med. Vet.,
DipECVDDI DVR

RADIOGRAPHIC DIAGNOSIS

- I can see no metastases
- Obesity
- Possible L sided cardiomegaly

HOSPITAL NAME

Bayshore Veterinary
Hospital

INTERPRETATION OF THE FINDINGS & FURTHER RECOMMENDATIONS

The oval opacities are compatible with superimposed shadows of the pulmonary vessels; a CT examination is needed to detect very small metastases. Echocardiography is recommended to rule out mitral valve disease.

REFERRING VET

Lara Stephens Brown

Obesity is a known to impair lung function; weight control is recommended.

INVOICE

47379

DATE

9-8-21



PATIENT

Taggs Minnie

SPECIES

Ca

BREED

Mix

SEX

FS

AGE

8

INTERPRETED BY

Heike Rudorf, DVM,
Dr. med. Vet.,
DipECVDI DVR

HOSPITAL NAME

Bayshore Veterinary
Hospital

REFERRING VET

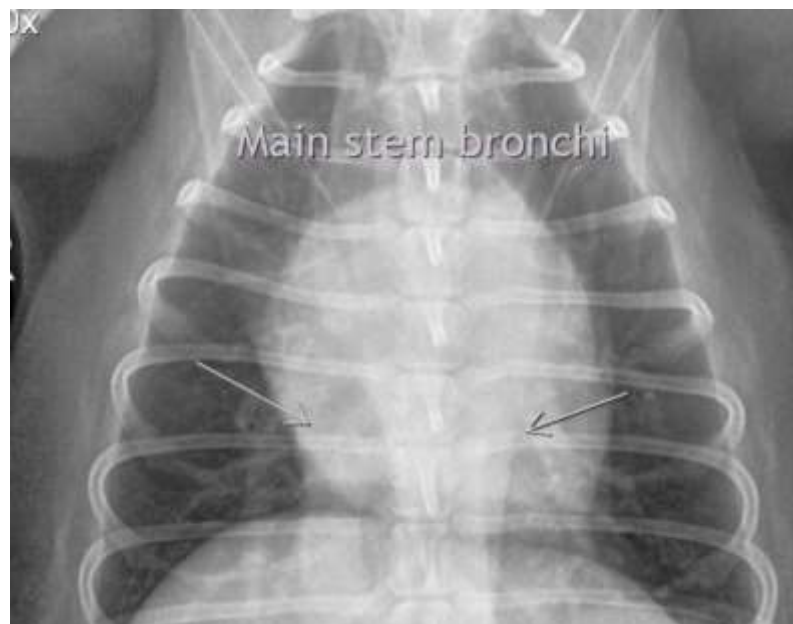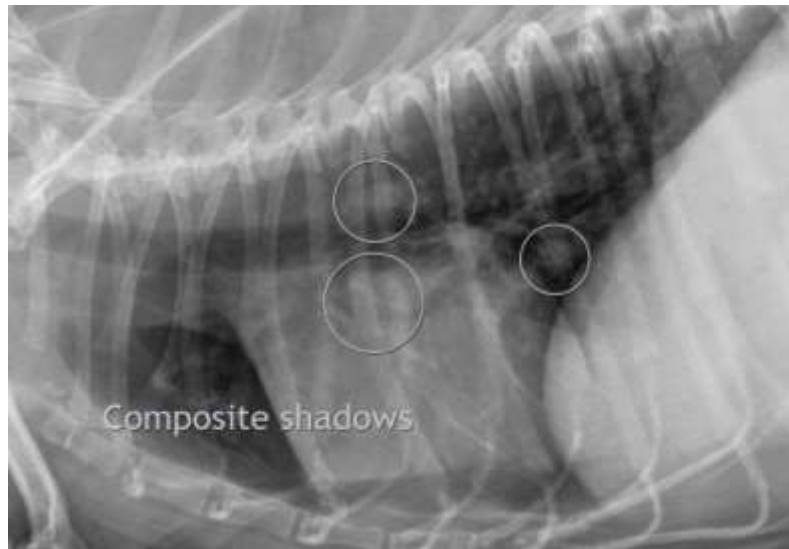
Lara Stephens Brown

INVOICE

47379

DATE

9-8-21





PATIENT

Taggs Minnie

The information and recommendations provided are based on the images presented by the referring veterinarian. No evaluation can be communicated regarding pathology that was not visible in the image/video clips provided.

SPECIES

Ca

Thank you for this referral. If the clinical or image interpretation does not parallel your findings or if I can be of any further assistance please contact me.

BREED

Mix

Heike Rudolf, DVM, Dr. med. vet., DipECVDI, DVR
Dr.H.Rudorf@gmail.com

SEX

FS

AGE

8

INTERPRETED BY

Heike Rudolf, DVM,
Dr. med. Vet.,
DipECVDI DVR

HOSPITAL NAME

Bayshore Veterinary
Hospital

REFERRING VET

Lara Stephens Brown

INVOICE

47379

DATE

9-8-21