SonoPath Teleradiology

EDUCATIONAL TELECONSULTATION SERVICES™

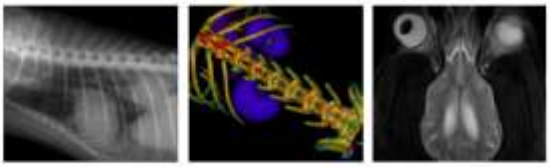

SonoPath.com
1-800-838-4268 info@sonopath.com

PATIENT

Rainbow Benko

SPECIES

Canine

BREED

Yorkie

SEX

Female Spayed

AGE

10 Years

INTERPRETED BY

Heike Rudorf, DVM, Dr. med. Vet., DipECVDI DVR

HOSPITAL NAME

Animal Health Partners

REFERRING VET

Dr. Shannon Westgarth

INVOICE

47377

DATE

9-8-21

PRESENTING CLINICAL SIGNS

Approximately 1 year history of chronic cough, previously unresponsive to doxycycline but responsive to hydroocodone and fluticasone inhaler; recent mild worsening of chronic cough, responds consistently to hydrocodone. Previous history of degenerative mitral valve disease, last echo January 2021 consistent with ACVIM Stage B1. Current therapies: fluticasone 125 mcg/puff - 1 puff q 24 hrs, hydrocodone 1 mg PRN

RADIOGRAPHIC STUDY OF THE THORAX

RLR, LLR, DV

RADIOGRAPHIC FINDINGS

The body condition score is 8/9 with smooth alternating layers of fat and soft tissue opacity.

T5 is slightly wedge shaped.

The degree of pulmonary expansion is fair at best. The lungs are in contact with the thoracic boundaries and the tips are pointed. The lobar vessels are blurred, and the caudo-dorsal lobes show an increased opacity.

Trachea and carina are elevated. The tracheal air shadow degreases gradually from C7 to the carina and the main bronchi are not seen.

The cardiac silhouette occupies 90% of the chest height and 3.5 intercostal spaces (VHS 12). The caudal heart border is straight and tenting of the left atrium is present.

RADIOGRAPHIC DIAGNOSIS

- Tracheal collapse
- Possible bronchial collapse
- Cardiomegaly
- Hepatomegaly
- Obesity

Incidental finding

- Congenital vertebral anomaly, mild

INTERPRETATION OF THE FINDINGS & FURTHER RECOMMENDATIONS

Tracheal collapse alone can be due to a weakened dorsal tracheal ligament. Tracheal as well as tracheo-bronchial collapse is usually caused by chondromalacia and is thus due to an altered cartilage development which may go unnoticed until physical circumstances (such as stress, running, excitement) or disease (e.g. L cardiac enlargement, pneumonia, bronchitis) reduces the ease of airflow. Echocardiography to re-assess mitral valve and L atrial size and trachea-bronchoscopy to assess the severity of the collapse and to obtain a BAL is recommended. Should an underlying lung disease be present, treatment may improve the clinical signs.

Obesity is known to worsen clinical signs of cough and impair lung function; weight control is necessary.

SonoPath Teleradiology

EDUCATIONAL TELECONSULTATION SERVICES™

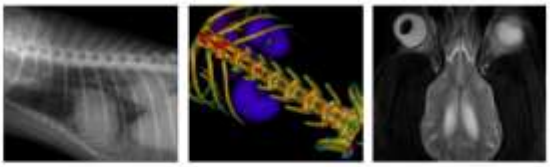

SonoPath.com
1-800-838-4268 info@sonopath.com

PATIENT

Rainbow Benko

SPECIES

Canine

BREED

Yorkie

SEX

Female Spayed

AGE

10 Years

INTERPRETED BY

Heike Rudorf, DVM, Dr. med. Vet., DipECVDI DVR

HOSPITAL NAME

Animal Health Partners

REFERRING VET

Dr. Shannon Westgarth

INVOICE

47377

DATE

9-8-21

The hepatomegaly may be due to congestion or fatty infiltrate. Diabetes and Cushing's disease should be ruled out.

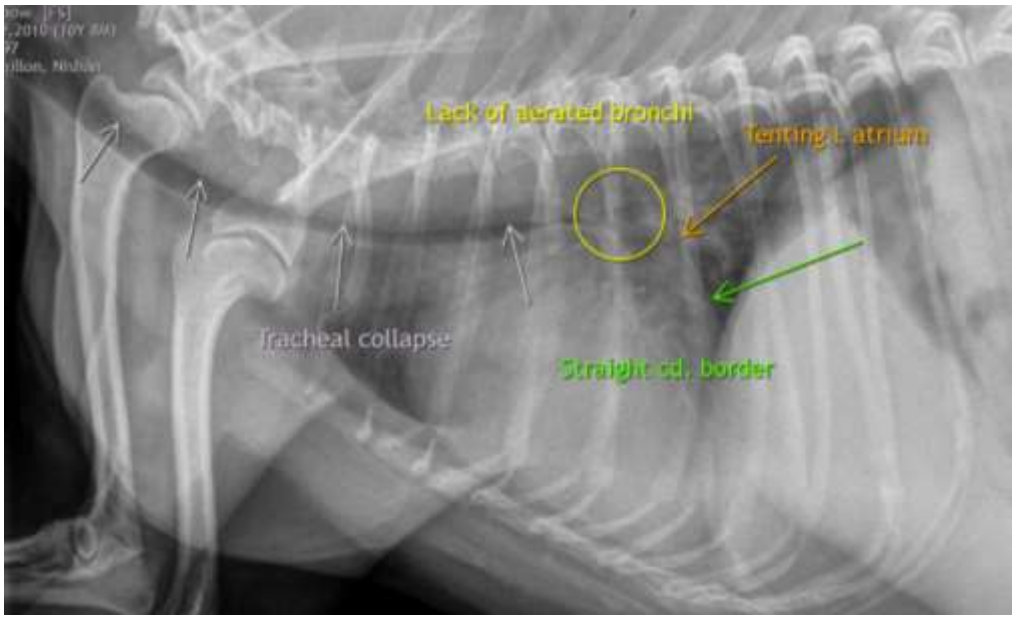

The information and recommendations provided are based on the images presented by the referring veterinarian. No evaluation can be communicated regarding pathology that was not visible in the image/video clips provided.

Thank you for this referral. If the clinical or image interpretation does not parallel your findings or if I can be of any further assistance please contact me.

Heike Rudorf, DVM, Dr. med. vet., DipECVDI, DVR
Dr.H.Rudorf@gmail.com