



PATIENT

Buzz Kocar

PRESENTING CLINICAL SIGNS

History: Pet presented for vague pain 8/18/21. Pet had normal exam and labwork (CBC/Chem) at that time and was prescribed Rimadyl. Pet returned 8/30/21 with right forelimb lameness and neck pain and was started on Rimadyl, methocarbamol, and gabapentin. Pet returned 9/4/21, still painful in neck, delayed CP in forelimbs but present and ambulating well, hold neck parallel to floor and resistant to rotation. Normal cranial nerve exam. O relay pet had history of owner tripping on pet early August prior to onset of initial symptoms, o felt they kicked the underside of the neck/thoracic inlet. Examination of this area today it normal and non painful, seems more spinal in origin. Abnormal PE/Chem/CBC/UA Results:

SPECIES

Canine

BREED

Australian Shepherd

RADIOGRAPHIC STUDY OF C- AND T-SPINE

The surrounding muscles and fat layers appear physiological.

SEX

Male

Number and shape of the vertebrae are physiological. The skeletal structures are well mineralized and have smooth surfaces. No compressive lesions or signs of aggressive osteolysis have been identified.

The facet joints appear to be congruent.

AGE

4 Years 6 Months

The disc spaces C4-7 appear to be reduced but both outlines of the caudal endplates are observed.

RADIOGRAPHIC DIAGNOSIS

- I can see no changes that would explain the clinical signs

INTERPRETED BY

Heike Rudolf, DVM,
Dr. med. Vet.,
DipECVDI DVR

INTERPRETATION OF THE FINDINGS & FURTHER RECOMMENDATIONS

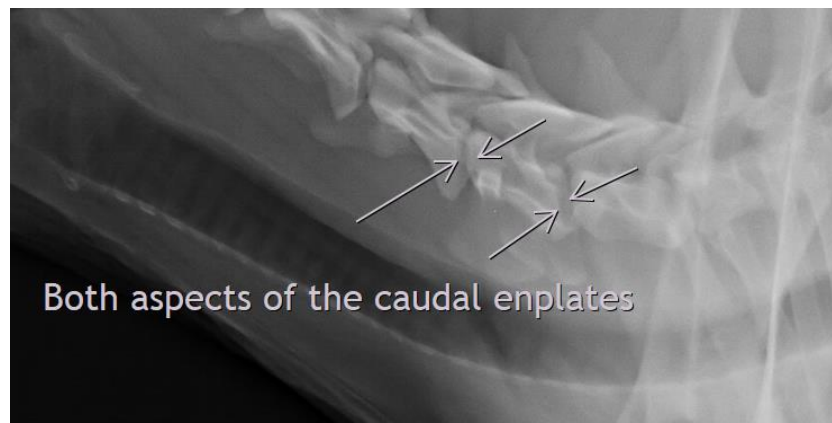
Accurate positioning of the spine is difficult, even under G.A., and cord compression can only be identified with myelography or in cross sectional imaging. Depending on the severity of the clinical signs, which may necessitate surgical intervention, CT or MRI is recommended. The brachial plexus nerves and the musculature (e.g. myositis) can be examined at the same time.

HOSPITAL NAME

All Creatures AH of
South Hill

REFERRING VET

Dr. Krisha Salmon



INVOICE

12957

DATE

9/8/21



PATIENT

Buzz Kocar

The information and recommendations provided are based on the images presented by the referring veterinarian. No evaluation can be communicated regarding pathology that was not visible in the image/video clips provided.

SPECIES

Canine

Thank you for this referral. If the clinical or image interpretation does not parallel your findings or if I can be of any further assistance please contact me.

Heike Rudolf, DVM, Dr. med. vet., DipECVDI, DVR
dr.h.rudorf@gmail.com

BREED

Australian Shepherd

SEX

Male

AGE

4 Years 6 Months

INTERPRETED BY

Heike Rudolf, DVM,
Dr. med. Vet.,
DipECVDI DVR

HOSPITAL NAME

All Creatures AH of
South Hill

REFERRING VET

Dr. Krisha Salmon

INVOICE

12957

DATE

9/8/21