



<b>PATIENT</b>	<b>PRESENTING CLINICAL SIGNS</b>
Frankie Hernandez	IVDD Rule out R/O L6, L7
<b>SPECIES</b>	<b>RADIOGRAPHIC STUDY OF L-SPINE AND STIFLES</b>
Canine	RLR thorax, 2 orthogonal views of the abdomen, L stifle including L-spine
<b>BREED</b>	<b>RADIOGRAPHIC FINDINGS</b>
French Bulldog	<u>L-Spine</u> The surrounding muscles and fat layers appear physiological. T5- 8, sacrum and tail show breed specific congenital vertebral anomalies.
<b>SEX</b>	Smooth new bone is present on the L facet joints between L5 and 7 and on the cranial endplate of T12.
Male Neutered	The discs between L5-7 are mineralized.
<b>AGE</b>	The urinary bladder is full.
5	<u>L stifle</u> The long bones are well mineralized, with physiological cortico-medullary development and differentiation. The joint has smooth subchondral bone surfaces. The cranial fat pad has a physiological size, and the caudal fascial plains are in a physiological position. New bone formation is not evident.
<b>INTERPRETED BY</b>	<b>RADIOGRAPHIC DIAGNOSIS</b>
Heike Rudolf, DVM, Dr. med. Vet., DipECVDI DVR	<ul style="list-style-type: none"> <li>• Disc mineralization L5-L7</li> <li>• Facet arthropathy left, mild</li> <li>• Congenital vertebral anomalies (e.g. wedge- and block vertebrae)</li> <li>• Sample text</li> </ul>
<b>HOSPITAL NAME</b>	<b>INTERPRETATION OF THE FINDINGS &amp; FURTHER RECOMMENDATIONS</b>
New Bridge Veterinary Practice	Accurate positioning of the spine is difficult even under G.A. and cord compression can only be identified with myelography or in cross sectional imaging. Depending on the severity of the clinical signs, CT or MRI will thus be necessary.
<b>REFERRING VET</b>	<b>TECHNICAL COMMENTS</b>
Dr. Abina Glennon	The L-spine is rotated on the lateral views
<b>INVOICE</b>	
47357	
<b>DATE</b>	
9-7-21	



**PATIENT**

Frankie Hernandez

**SPECIES**

Canine

**BREED**

French Bulldog

**SEX**

Male Neutered

**AGE**

5

**INTERPRETED BY**

Heike Rudorf, DVM,  
Dr. med. Vet.,  
DipECVDI DVR

**HOSPITAL NAME**

New Bridge  
Veterinary Practice

**REFERRING VET**

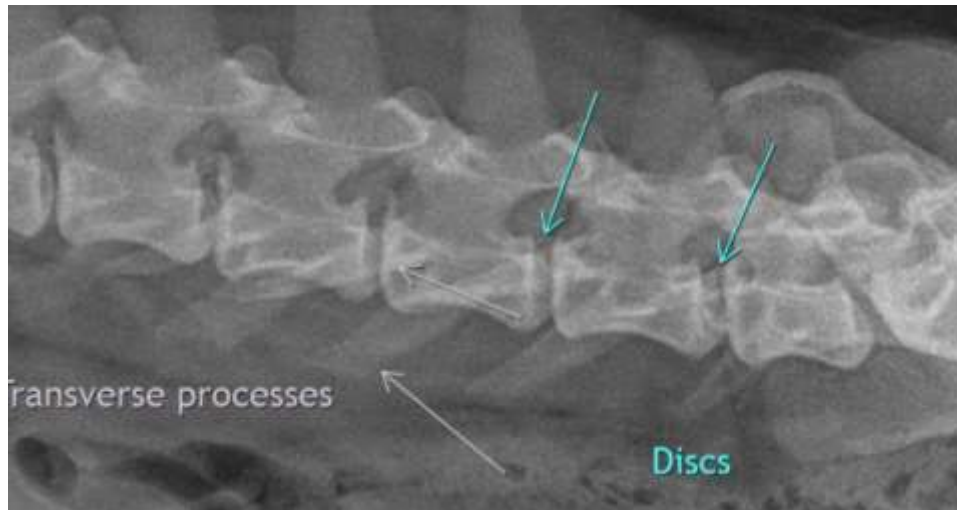
Dr. Abina Glennon

**INVOICE**

47357

**DATE**

9-7-21



The information and recommendations provided are based on the images presented by the referring veterinarian. No evaluation can be communicated regarding pathology that was not visible in the image/video clips provided.

Thank you for this referral. If the clinical or image interpretation does not parallel your findings or if I can be of any further assistance please contact me.

**Heike Rudorf**, DVM, Dr. med. vet., DipECVDI, DVR  
Dr.H.Rudorf@gmail.com